

Shortness of breath

Shortness of breath

J S Dawson, C J L Hetherington

Answers on p 681.

A 50 year old man presented with a one week history of general malaise, worsening shortness of breath, and a cough productive of green sputum. He had also noticed an itchy rash on his trunk and face. There was no relevant medical history and he took no regular medications. He was a non-smoker.

On examination the patient had a widespread symmetrical rash over his face, trunk, and proximal limbs; this consisted of vesicles, pustules, and crusted lesions. He was afebrile, dyspnoeic at rest with a respiratory rate of 36 breaths/min, and tachycardic (pulse 140 beats/min) with a normal blood pressure. Auscultation of his chest revealed vesicular breath sounds bilaterally; the rest of the examination was unremarkable.

Arterial blood gas analysis on air (table 1) demonstrated the patient was

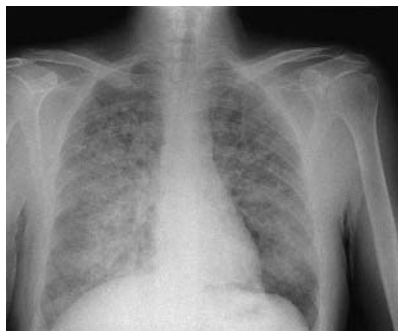

Figure 1 Chest radiograph.

profoundly hypoxic. A chest radiograph (fig 2) demonstrated diffuse infiltrates across both lung fields.

QUESTIONS

- (1) What is the diagnosis?
- (2) How might the diagnosis be confirmed?

	Patient	Reference range
pH	7.40	7.35–7.45
pCO ₂ (kPa)	4.38	4.6–6.0
pO ₂ (kPa)	6.6	10–13.3
Bicarbonate (mmol/l)	22	24–30
Base excess	–3.0	+2 to –2
O ₂ saturation (%)	76	>94

- (3) What is the differential diagnosis of findings on the chest radiograph?

Postgrad Med J 2004;80:679.
doi: 10.1136/pgmj.2003.016568

Authors' affiliations

J S Dawson, Division of Anaesthesia and Intensive Care, Queen's Medical Centre, Nottingham, UK

C J L Hetherington, Department of Emergency Medicine, Russells Hall Hospital, Dudley, West Midlands, UK

Correspondence to: Dr J S Dawson, Division of Anaesthesia and Intensive Care, Queen's Medical Centre, University Hospital NHS Trust, Nottingham NG7 2UH, UK; james@dawson.me.uk

Submitted 29 October 2003
Accepted 19 November 2003

Bradycardia and hypotension

Symptomatic bradycardia and postural hypotension

R Gupta, S Singh, M A Rahman, M Saeed, Y Birnbaum

Answers on p 681.

A 24 year old white woman presented to hospital with complaints of recurrent dizziness and lightheadedness. She also admitted to several non-exertional episodes of passing out, lasting for a few minutes, over the past two years. These episodes were not associated with seizure-like activity. She had been admitted to multiple hospitals in the past with similar symptoms without any conclusive diagnosis or treatment. Hypertension was diagnosed five years earlier for which she was receiving clonidine and nifedipine. Work-up for secondary hypertension at another hospital, including urinary metanephrines, cosyntropin stimulation test, and a renal arteriogram had all been negative in the past. There was no

history of diabetes, prior psychiatric disorder, or family history of sudden death. She had a history of syringomyelia with Arnold-Chiari malformation for which she had received decompression surgery at the age of 12 years.

The patient was found to have a heart rate of 34 beats/min, blood pressure of 110/50 mm Hg; on standing her blood pressure dropped to 80/40 mm Hg with a heart rate of 54 beats/min. The rest of the physical examination was normal. An electrocardiogram showed sinus bradycardia with a heart rate of 34 beats/min. The QTc interval was not prolonged (fig 1). Transthoracic echocardiogram was normal.

She was taken off antihypertensive medications and observed. Her symptoms,

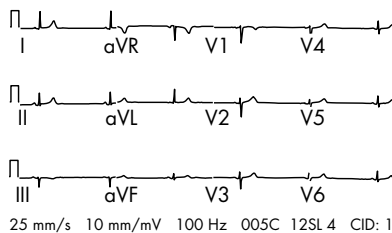


Figure 1 Electrocardiogram showing sinus bradycardia with a rate of 34 beats/min. QRS morphology is normal and there are no ST-T changes; QTc is normal.

bradycardia and hypotension, resolved gradually over the next two days. The patient was advised not to take antihypertensive medications and discharged.

She came back one week later with similar complaints. Resting bradycardia, orthostatic hypotension, wide fluctuations in vital signs with both hypertensive and hypotensive episodes were noted. This time she denied taking any antihypertensives medications. In view of her history of syringomyelia, further imaging with computed tomography of her brain and cervical spinal cord was done. This showed a tube adjacent to distal cervical cord from previous syrinx decompression and cerebellar tonsils extending below the foramen magnum consistent with Arnold-Chiari malformation (fig 2).

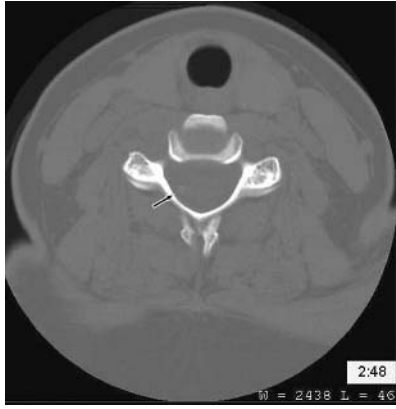

Figure 2 Computed tomography showing a tube (arrow) used for decompression of syrinx in the cervical cord.

She was prescribed fludrocortisone for presumed autonomic dysfunction and discharged and was scheduled for follow up in one month.

The patient was readmitted in one week for severe bradycardia and syncope. At that time it was decided to place a permanent pacemaker secondary to persistence of symptomatic bradycardia. After the pacemaker placement the patient's symptoms seemed to improve dramatically. On the follow up visit to the clinic a purplish rash was noted over the pacemaker site (fig 3). She also began to complain of recurrent symptoms of postural dizziness. Suspecting a

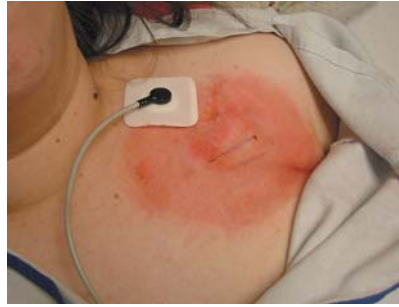

Figure 3 "Rash" over the pacemaker site.

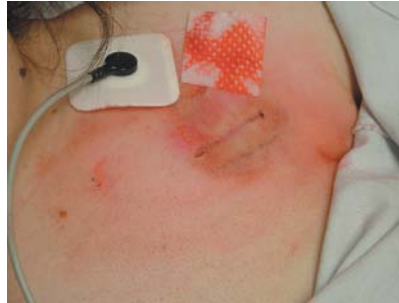

Figure 4 "Rash" over the pacemaker site wiped off with an alcohol swab.

pacemaker infection the patient was readmitted to hospital. During her hospital stay, a closer examination of the rash showed that it could be wiped away by an alcohol swab and the colour

was similar to the lipstick used by the patient (fig 4). A nurse also noted that the patient had a half empty bottle of clonidine under her pillow. When asked about the pills she denied taking any extraneous medicine or any knowledge of the clonidine bottle.

QUESTIONS

- (1) What is the initial work-up of syncope?
- (2) Can Arnold-Chiari malformation and syringomyelia be related to her symptoms?
- (3) What are the final diagnosis, clinical features, and treatment of this disorder?

Postgrad Med J 2004;**80**:679–680.
doi: 10.1136/pgmj.2003.017723

Authors' affiliations

R Gupta, M A Rahman, M Saeed, Y Birnbaum, Division of Cardiology, Department of Medicine, University of Texas Medical Branch at Galveston
S Singh, Department of Internal Medicine, University of Texas Medical Branch at Galveston

Correspondence to: Dr Yochai Birnbaum, Division of Cardiology, University of Texas Medical Branch at Galveston, 301 University Boulevard, Galveston, Texas 77555, USA; yobirbba@utmb.edu

Submitted 3 December 2003
Accepted 18 December 2003