

## SELF ASSESSMENT ANSWERS

### Pigmented sclera: a diagnostic challenge?

#### Q1: What is the diagnosis in the male patient?

Dark pigmented spots in sclera were seen in both eyes (fig 1; see p 491). The combination of chronic arthritis, dark urine, pigmentation, and family history suggests the diagnosis of alkaptonuria.

#### Q2: Does his sister have the same condition?

The sister also has alkaptonuria (fig 2; see p 491). Alkaptonuria is an autosomal recessive disorder. Siblings are more likely to suffer from the condition than parents or offspring. Usually there is a history of consanguineous marriage in the parents of affected offspring. However, the parents of the brother and sister reported here were unrelated to each other before marriage and hailed from widely different geographical areas of the UK. One in 1000 persons in the UK is a carrier for the alkaptonuria gene.

#### Q3: What further investigations would you perform to confirm your diagnosis?

The diagnosis of alkaptonuria is made by demonstrating homogentisic aciduria (fig 1 below). Analytical methods for homogentisic acid are readily available. Methods for demonstrating defective enzyme activity or abnormal genes are only available as research tools. Previously, diagnosis was often made early on in life as nappies turned black due to freshly passed acidic urine becoming alkaline on prolonged exposure to air. Alkalinising the urine in this brother and sister produced an immediate dark colour (fig 1).

The urine estimation by chromatography confirmed the presence of large amounts of homogentisic acid in these siblings.

#### Q4: What are the clinical features of this disease?

The clinical features of alkaptonuria are summarised in box 1. The deposition of melanin-like pigment in tissues is called ochronosis.




Figure 1 Urine colour (Neat, unalkalinised; Alk, alkalinised).

#### Q5: How would you manage this condition?

The treatment is mainly symptomatic and palliative in the form of analgesics and joint replacement. Reducing the conversion of homogentisic acid to the benzoquinone metabolite is an attractive therapeutic objective; the use of reducing agents such as vitamin C in this regard has had mixed success.<sup>1,2</sup> A recent approach tested the idea that the production of homogentisic acid could be suppressed by inhibiting the enzyme hydroxyphenylpyruvate dioxygenase (fig 2 below).<sup>3</sup>

#### Discussion

It is just over 100 years since Garrod described alkaptonuria, a rare autosomal recessive amino acid disorder of phenylalanine and tyrosine metabolism (fig 2). The highest incidence of alkaptonuria has been recorded (one in 19 000) in Slovakia<sup>4</sup> and the Dominican Republic, although the incidence in rest of the world is one in a 1 000 000. Mutations of the alkaptonuria gene, located on chromosome 3q21-q23 in humans, leads to the production of an inactive homogentisic acid oxidase (HGO) protein.<sup>5</sup> Various data have shown that the human HGO gene and the alkaptonuria gene map to the same location providing evidence that alkaptonuria is caused by a defect in the structural gene encoding HGO. The Human Gene Mutation Database reports a total of 42 mutations within the HGO gene to date.

The triad of alkaptonuria consists of homogentisic aciduria, ochronosis, and arthritis. The clinical abnormalities (box 1) can be attributed directly to excess urinary homogentisic acid (renal calculi and renal failure) or indirectly to oxidation of circulating homogentisic acid to a benzoquinone compound that has great avidity for connective tissue (fig 2). The earliest change that can be detected externally is the blue pigmentation of the sclera and ears. Arthritis affects the large joints in the upper and lower limbs. The disease process affects the spine resembling ankylosing spondylitis (sparing the sacroiliac joints). Ochronotic arthropathy (spondylosis or peripheral arthropathy) affects mainly male subjects after the age of 40. It is

### Box 1: Clinical features in alkaptonuria

- Dark urine.
- Scleral pigmentation.<sup>6</sup>
- Subcutaneous cartilage pigmentation.<sup>6</sup>
- Arthritis, kyphosis, intervertebral disc prolapse, paraparesis, osteoporosis.<sup>7</sup>
- Rupture of tendons and ligaments.<sup>7</sup>
- Inflammation, fibrosis, calcification of cardiac valves.<sup>8</sup>
- Renal, urinary bladder and prostatic calculi.<sup>3</sup>

### Learning points

- History of dark pigmentation in sclera, ear cartilage, or mucus membrane along with arthritis should be investigated for alkaptonuria by measurement of homogentisic acid in urine.
- The pattern of inheritance often aids the diagnosis of alkaptonuria and allows recognition of disease in other family members.
- All treatment approaches so far are unsatisfactory and hence mainly palliative.

postulated that accumulation of homogentisic acid in the connective tissues directly or indirectly leads to cartilage destruction.<sup>7</sup> Spinal involvement especially in HLA B27 positive patients, can lead to immobility, kyphosis and spastic paraparesis, by producing degeneration, calcification, narrowing and prolapse of intervertebral discs.

Several treatments have been tried to alleviate alkaptonuria either by reducing the production of HGA or preventing its oxidation to the benzoquinone compound (fig 2). Ascorbic acid inhibits conversion of homogentisic acid to the polymer.<sup>1,2</sup> Low protein diet reduces the daily load of phenylalanine and tyrosine and lower the homogentisic acid

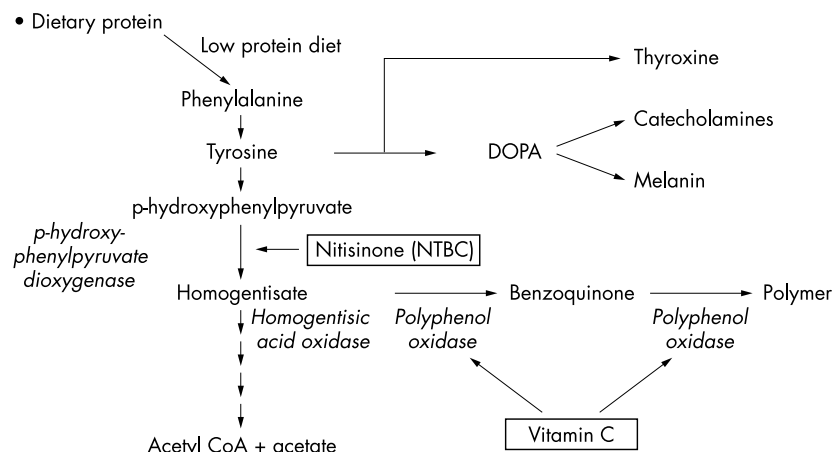


Figure 2 Metabolism of phenylalanine and tyrosine.

excretion.<sup>9</sup> A recent approach is based on the principle of enzyme inhibition. NTBC or nitisinone (Orfadin) is a potent inhibitor of the enzyme that generates homogentisic acid (hydroxyphenylpyruvate dioxygenase)<sup>3</sup> and effectively reduces the homogentisic acid load in animals as well as humans with alkaptonuria.<sup>3</sup> These treatment are unsatisfactory either due to a lack of efficacy or because of concerns about safety. Lastly, the gene therapy to cure alkaptonuria is still some distance in the future.

### Final diagnosis

Alkaptonuria in a man presenting with homogentisic aciduria, ochronosis, arthritis, and renal calculi.

### References

- 1 Forslind K, Wollheim FA, Akesson B, *et al*. Alkaptonuria and ochronosis in three siblings. Ascorbic acid treatment monitored by urinary HGA excretion. *Clin Exp Rheumatol* 1998;**6**:289–92.
- 2 Wolff JA, Barshop B, Nyhan WL, *et al*. Effects of ascorbic acid in alkaptonuria: alterations in benzoquinone acetic acid and an ontogenic effect in infancy. *Pediatr Res* 1989;**26**:140–4.
- 3 Chanika P, Introne JW, Perry MB, *et al*. Natural history of alkaptonuria. *N Engl J Med* 2002;**347**:2111–21.
- 4 Srsen S, Muller CR, Regin A, *et al*. Alkaptonuria in Slovakia: thirty-two years of research on phenotype and genotype. *Mol Genet Metab* 2002;**75**:353–9.
- 5 Pollak MR, Chou YH, Cerda JJ, *et al*. Homozygosity mapping of the gene for alkaptonuria to chromosome 3q2. *Nat Genet* 1993;**5**:201–4.
- 6 Turiansky GW, Levin SW. Bluish patches on the ears and axillae with dark urine: ochronosis and alkaptonuria. *Int J Dermatol* 2001;**40**:333–5.
- 7 La Du BN Jr. Alkaptonuria and ochronotic arthritis. *Mol Biol Med* 1991;**8**:31–8.
- 8 Cercek M, Prokselj K, Kozelj M. Aortic valve stenosis in alkaptonuric ochronosis. *J Heart Valve Dis* 2002;**11**:386–8.

- 9 Morava E, Kosztolanyi G, Engelke U, *et al*. Reversal of clinical symptoms and radiographic abnormalities with protein restriction and ascorbic acid in alkaptonuria. *Ann Biochem* 2003;**40**:108–10.

## Upper gastrointestinal haemorrhage

### Q1: What is the diagnosis?

Dieulafoy's lesion in the stomach. Recommended treatment is thermal ablation.

Dieulafoy's lesion is an important cause of upper gastrointestinal haemorrhage and may account for up to 5% of acute haemorrhages.<sup>1</sup> Dieulafoy *et al* described it in 1897 as exulceratio simplex, cirroid aneurysm.<sup>1</sup> The histological appearance is characteristic; a relatively large calibre artery that lies close to the mucosal surface, likely as a congenital anomaly. Most Dieulafoy lesions are diagnosed by their endoscopic features. The features are arterial bleeding or non-bleeding visible vessel stigmata, all with normal surrounding mucosa. However, this lesion is commonly missed as illustrated by our case and the initial endoscopy is diagnostic in only 63% of cases.<sup>1</sup> It is potentially life threatening and massive haemorrhage can occur with erosion of the mucosa and arterial wall.

### Q2: What is the most appropriate endoscopic haemostatic method?

The study by Norton *et al* suggests endoscopic haemostasis was achieved in 94% of cases.<sup>1</sup> Various endoscopic haemostatic methods have been advocated but most experience has been with thermal ablation (heater probe), which should be available in most centres. Long term recurrence was not evident after successful endoscopic ablation.<sup>1</sup> A recent study advocates endoscopic haemoclipping application as an alternative effective and

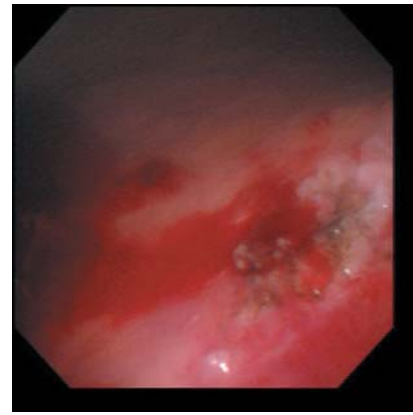


Figure 1 Dieulafoy's lesion in stomach after endoscopic treatment.

safe method with long term benefits.<sup>2</sup> Our patient was initially treated with an injection of epinephrine to slow down the bleeding rate followed by thermal ablation to achieve haemostasis (fig 1 below). The patient made an uneventful recovery with no further bleed within six months of follow up.

### Final diagnosis

Dieulafoy's lesion.

### References

- 1 Norton ID, Petersen BT, Sorbi D, *et al*. Management and long-term prognosis of Dieulafoy lesion. *Gastrointest Endosc* 1999;**50**:762–7.
- 2 Yamaguchi Y, Yamato T, Katsumi N, *et al*. Short-term and long-term benefits of endoscopic hemoclip application for Dieulafoy's lesion in the upper GI tract. *Gastrointest Endosc* 2003;**57**:653–6.