

CASE REPORT

Gastrointestinal stromal tumour in an inguinal hernial sac: an unusual presentation

A Goyal, R E Mansel, S Goyal

Postgrad Med J 2003;**79**:707–708

Malignancy involving hernial sacs is rare. A 72 year old man is reported who had a right inguinal irreducible mass as an initial presentation of gastrointestinal stromal tumour mimicking irreducible inguinal hernia. The diagnosis was missed at the time of surgery and was revealed only by the histology results of the excised sac.

Gastrointestinal stromal tumours (GISTs) are rare and account for 0.1%–3.0% of all gastrointestinal neoplasms and 5.7% of sarcomas.^{1–3} We report a 72 year old man who had a right inguinal irreducible mass as an initial presentation of GIST mimicking irreducible inguinal hernia. We believe this is the first description of inguinal mass as an initial presentation of GIST.

CASE REPORT

A 72 year old man presented as an acute surgical admission with a tender swelling in the right groin that had been present for about 10 days and followed a long walk. The swelling had become more painful over the last couple of days. He was well otherwise and had no symptoms related to the gastrointestinal tract. Physical examination revealed a firm, tender, irreducible, non-pulsatile mass in the right groin which was thought to be an irreducible hernia. His abdomen was soft and non-tender with normal bowel sounds. He underwent emergency surgery which revealed an organised haematoma, identified at the lower end of an empty hernial sac. The sac along with the haematoma was removed. Subsequent histology revealed the haematoma and an extraintestinal GIST. Computed tomography of the abdomen and chest to look for metastatic disease showed the presence of a large lobulated intra-abdominal mass in the right iliac fossa which appeared to be outside the intestine. There was no lymphadenopathy and no hepatic or lung metastasis. Clinical examination repeated postoperatively showed no palpable mass in the right groin or the right iliac fossa. He underwent laparotomy with the aim to radically excise this tumour together with the right testis and cord. At operation, a large lobulated, pedunculated small bowel tumour was found growing exophytically (fig 1). This was excised along with a small piece of small bowel. The histology confirmed a GIST tumour with no infiltration into the margins.

DISCUSSION

GISTs are defined as spindle cell, epithelioid, or occasionally pleomorphic mesenchymal tumours of the gastrointestinal tract, which express the KIT protein (CD117, stem cell factor receptor) detected at immunohistochemistry. There is a continuum from benign to malignant that can be predicted, although not absolutely, according to tumour size and mitotic frequency.⁴ Malignant GISTs are typically large, well

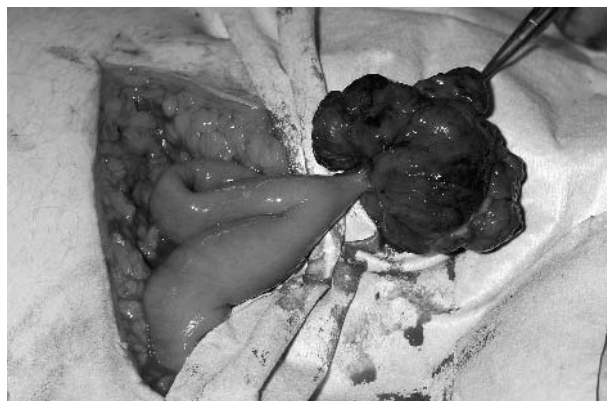


Figure 1 Intraoperative photograph showing a well circumscribed fleshy lobulated stromal tumour arising exophytically from the small bowel.

circumscribed, heterogeneous, centrally necrotic tumours that arise in the wall of the small bowel or stomach.³

Features at clinical presentation are dependent on tumour size. Small tumours are usually an incidental surgical finding, while large tumours are usually symptomatic. Symptoms include gastrointestinal haemorrhage, often with an acute episode, abdominal pain, a mass, weight loss, nausea, and vomiting. Small bowel obstruction is reported in up to 30% of clinical series but accounts for less than 10% of presentations in most reports.^{6–9} This may be due to the fact that a large number of the tumours as in this case are predominantly extraluminal and would therefore be less likely to result in obstruction.⁵ Inguinal mass as an initial presentation of GIST has not been reported in literature.

It is possible that in this case a part of the GIST prolapsed into the inguinal hernial sac and was trapped by the narrow neck of the sac. The contents appeared to have slipped back into the abdomen before the sac was opened. However, damage to the constricted areas resulted in haemorrhage and shedding of tumour cells into the sac. The diagnosis should have come to light at the first operation if the abdomen was explored to examine the contents of the sac that had slipped back.

Learning points

- Empty hernial sacs associated with haemorrhage may suggest an intra-abdominal disease.
- Gross hernia sac abnormalities should be examined microscopically.

Two lessons can be learnt from this case. Firstly, if blood is found in the sac in a case of irreducible inguinal hernia, it is essential to explore the abdomen to find out the causative factor. Secondly, grossly apparent inguinal hernia sac abnormalities should be examined microscopically to avoid missing the diagnosis of cancer as in this case, but routine histological examination of all hernia sacs is not warranted.

Authors' affiliations

A Goyal, R E Mansel, S Goyal, Department of Surgery, University of Wales College of Medicine, Cardiff

Correspondence to: Mr Amit Goyal, Department of Surgery, University of Wales College of Medicine, Heath Park, Cardiff CF14 4XN, UK; goyal@cf.ac.uk

Submitted 26 April 2003

Accepted 18 June 2003

REFERENCES

- 1 **DeMatteo RP**, Lewis JJ, Leung D, et al. Two hundred gastrointestinal stromal tumors: recurrence patterns and prognostic factors for survival. *Ann Surg* 2000;**231**:51–8.
- 2 **Lewis JJ**, Brennan MF. Soft tissue sarcomas. *Curr Probl Surg* 1996;**33**:817–72.
- 3 **Licht JD**, Weissmann LB, Antman K. Gastrointestinal sarcomas. *Semin Oncol* 1988;**15**:181–8.
- 4 **Miettinen M**, Lasota J. Gastrointestinal stromal tumors—definition, clinical, histological, immunohistochemical, and molecular genetic features and differential diagnosis. *Virchows Arch* 2001;**438**:1–12.
- 5 **Burkill GJ**, Badran M, Al Muderis O, et al. Malignant gastrointestinal stromal tumor: distribution, imaging features, and pattern of metastatic spread. *Radiology* 2003;**226**:527–32.
- 6 **Lev D**, Kariv Y, Issakov J, et al. Gastrointestinal stromal sarcomas. *Br J Surg* 1999;**86**:545–9.
- 7 **Ludwig DJ**, Traverso LW. Gut stromal tumors and their clinical behavior. *Am J Surg* 1997;**173**:390–4.
- 8 **McGrath PC**, Neifeld JP, Lawrence W Jr, et al. Gastrointestinal sarcomas. Analysis of prognostic factors. *Ann Surg* 1987;**206**:706–10.
- 9 **Pidhorecky I**, Cheney RT, Kraybill WG, et al. Gastrointestinal stromal tumors: current diagnosis, biologic behavior, and management. *Ann Surg Oncol* 2000;**7**:705–12.

IF ONLY I'D KNOWN.....

Ten things I wish I'd known when I was 25

- (1) Twig 'n' berries are a County Durham euphemism for male genitalia. As a junior doctor I once advised a patient who told me that his twig 'n' berries were not working to pour on cold tea (my wife's cure for ailing houseplants).
- (2) You can ask questions of examiners "Could this be...?" and they will tell you the answer.
- (3) Patients lead much more interesting and amazing lives than doctors "You did what, where, how often...?"
- (4) Medical school does not prepare you for a free living existence. No one taught me how to put up a shelf or how to hammer in a screw (clockwise is best).
- (5) Mosquitoes can fly upside down, backwards while dodging raindrops. Humans, who think they have superior abilities, think that they can avoid mosquito bites and don't need to take malaria prophylaxis.
- (6) In a democracy we can hire and fire politicians. They are our servants, not our masters.
- (7) The fact that something needs a formal trial to demonstrate that it is statistically objectively better than placebo proves only that it is better than nothing.
- (8) A suggestion that a lumbar puncture might be required cures most headaches.
- (9) Teaching is not as sexy or meritorious as research or sitting on committees.
- (10) Medical journals are usually best read from back to front. Information, interest, and comment are maximal at the back whereas industry tends to be to the fore.

P D Welsby
Edinburgh (p.welsby@ed.ac.uk)