

REVIEW

Acute disseminated encephalomyelitis

R K Garg

Postgrad Med J 2003;79:11–17

Acute disseminated encephalomyelitis (ADEM) is an acute demyelinating disorder of the central nervous system, and is characterised by multifocal white matter involvement. Diffuse neurological signs along with multifocal lesions in brain and spinal cord characterise the disease. Possibly, a T cell mediated autoimmune response to myelin basic protein, triggered by an infection or vaccination, underlies its pathogenesis. ADEM is a monophasic illness with favourable long term prognosis. The differentiation of ADEM from a first attack of multiple sclerosis has prognostic and therapeutic implications; this distinction is often difficult. Most patients with ADEM improve with methylprednisolone. If that fails immunoglobulins, plasmapheresis, or cytotoxic drugs can be given. Recent literature suggests that a significant proportion of patients with ADEM will later develop multiple sclerosis; however, follow up experience from developing countries does not support this view.

mortality and morbidity. Because of significant advances in infectious disease control ADEM in developed countries is now seen most frequently after non-specific upper respiratory tract infections and the aetiological agent remains unknown. In a recent study by Murthy *et al*, despite vigorous attempts to identify microbial pathogens in 18 patients, only one patient had Epstein-Barr virus isolated as the definite microbial cause of ADEM. Of the other two patients with rotavirus disease, in one patient infection was considered as possibly associated with ADEM. Failure to identify a viral agent suggests that the inciting agents are unusual or cannot be recovered by standard laboratory procedures.¹ In developing and poor countries, because of poor implementation of immunisation programmes, measles and other viral infections are still widely prevalent and account for frequent occurrences of postinfectious demyelinating diseases. ADEM in developing countries is much more frequent than reported.² In the past it had been observed that ADEM occurred in one out of 1000 measles infections. ADEM was relatively uncommon after varicella infection and the incidence that had been reported was about one per 10 000 patients. The incidence of ADEM after rubella infection was approximately one per 500 infections. Mortality and major neurological sequelae of ADEM after varicella and rubella infections were much lower in comparison with ADEM after measles infection. ADEM found after measles was associated with mortality rates as high as 25% and 25%–40% of survivors were left with permanent neurological sequelae.^{3–5} The main bacterial infection, which has been implicated with the occurrence of ADEM, is mycoplasma. Other viral and bacterial infections that have been implicated with ADEM are listed in box 2.

Another common variant of ADEM is that which follows vaccination (postimmunisation encephalomyelitis). This form is clinically indistinguishable from the postinfectious variety except the former more often involves the peripheral nervous system. When rabies vaccine was generated from virus grown in rabbit brain, the rate of neurological complications was estimated to be as high as one in 400 vaccinations. The reported incidence of neuromyelitis complications with the Semple type of antirabies vaccine varied between one per 600 to one per 1575 vaccinations. Such complications are now

Acute disseminated encephalomyelitis (ADEM) is an acute widespread demyelinating condition, which principally affects brain and spinal cord (box 1). It usually follows an infection or vaccination. The disease is characterised by multifocal white matter lesions on neuroimaging. ADEM is a monophasic disease. Uncommonly ADEM can relapse frequently. If these relapses are thought to represent part of the same acute monophasic illness, the term multiphasic ADEM is used. Any recurrences beyond the first few months of initial clinical illness suggest the presence of a chronic immune process and a diagnosis of multiple sclerosis should be considered. Devic's disease or neuromyelitis optica is characterised by simultaneous attacks of optic neuritis and myelitis with no evidence of involvement of other parts of the central nervous system. Precisely what relationship these distinct entities have with each other is a subject of intense controversy. In the recent past a lot of new information about ADEM and its association with other demyelinating disorders has been made available. In this article all this information will be reviewed.

EPIDEMIOLOGY

The exact incidence of ADEM is not known. In the past ADEM commonly followed common childhood infections (like measles, smallpox, and chickenpox) and was associated with significant

Correspondence to:
Dr R K Garg, Department
of Neurology, King
George's Medical College,
Lucknow 226003, India;
garg50@yahoo.com

Submitted
15 January 2002
Accepted
16 October 2002

Abbreviations: ADEM, acute disseminated encephalomyelitis; EAE, experimental allergic encephalomyelitis; FLAIR, fluid attenuated inversion recovery sequence; HEAE, hyperacute experimental allergic encephalomyelitis; MHC, major histocompatibility complex; MRI, magnetic resonance imaging

Box 1: Acute disseminated encephalomyelitis and related disorders

Acute disseminated encephalomyelitis

- Postinfectious.
- Postvaccinal.

Acute haemorrhagic leucoencephalitis

Restricted form of acute, inflammatory demyelinating diseases

- Transverse myelitis.
- Optic neuritis.
- Cerebellitis.
- Brain stem encephalitis.

Multiphasic form of acute disseminated encephalomyelitis and multiple sclerosis

Box 2: Preceding infectious illnesses

A. Infections

Viral

- Measles.
- Mumps.
- Influenza A or B.
- Hepatitis A or B.
- Herpes simplex.
- Human herpes virus E.
- Varicella, rubella.
- Epstein-Barr virus.
- Cytomegalovirus.
- HIV.

Others

- *Mycoplasma pneumoniae*.
- Chlamydia.
- Legionella.
- Campylobacter.
- Streptococcus.

B. Vaccines

- Rabies.
- Diphtheria, tetanus, pertussis.
- Smallpox.
- Measles.
- Japanese B encephalitis.
- Polio.
- Hepatitis B.
- Influenza.

rare as non-neural tissue based vaccines are being used. An incidence rate of one per 25 000 vaccinations occurred with duck embryo antirabies vaccine, a preparation containing minimal amount of neural tissue. Introduction of the non-neural human diploid cell vaccine has virtually eliminated neuroparalytic complications of rabies vaccinations.⁶⁻¹¹ When smallpox vaccination was a part of a universal immunisation programme, encephalomyelitis followed one in 4000 vaccinations. Currently, postimmunisation encephalomyelitis is most commonly associated with measles, mumps, and rubella vaccinations. The incidence is 1-2 per million for live measles vaccine immunisations, which is significantly lower than that for postinfectious encephalomyelitis from measles itself. The risk of occurrence of ADEM is 20 times lower after vaccination than ADEM after natural measles virus infection.^{2 12 13}

PATHOLOGY AND PATHOGENESIS

The hallmark of the pathological findings of postinfectious encephalomyelitis is areas of perivenous demyelination and infiltration of lymphocytes and macrophages. Other changes include hyperaemia, endothelial swelling, and vessel wall

invasion by inflammatory cells, perivascular oedema, and haemorrhage. These changes are present in the small blood vessels of both white and grey matter. As the lesions become older, the macrophages increase and lymphocytes decrease in number. At a late stage of disease foci of fibrillary fibrosis can also be seen in adjacent brain tissue. Although postinfectious encephalomyelitis typically involves the white matter, lesions in grey matter have also been seen. Basal ganglia, thalamus, and even cortical grey matter may be involved.^{14 15}

The pathological findings described in ADEM are very similar to experimental allergic encephalomyelitis (EAE). EAE is an autoimmune encephalomyelitis that can be induced experimentally in susceptible animals by exposing them to a myelin antigen such as myelin basic protein, proteolipid protein, and myelin oligodendrocyte glycoprotein. In complete Freund's adjuvant these myelin antigens can produce a diffuse white matter encephalomyelitis. Myelin basic protein and proteolipid protein are the most encephalitogenic. The existing evidence suggests that ADEM results from a transient autoimmune response against myelin or other autoantigens, possibly, via molecular mimicry or by non-specific activation of an autoreactive T cell clone. Peptides from microbial proteins that have sufficient structural similarity with the host's self peptides can activate autoreactive T cells; this mechanism is referred to as molecular mimicry. EAE, in the Theiler's murine encephalomyelitis model, is initiated by CD4+ T helper cells by infiltrating the central nervous system and subsequently recruiting additional lymphocytes and mononuclear cells to cross the blood-brain barrier, resulting in inflammation and demyelination. CD8+ T cells have also been implicated in a secondary autoimmune response.¹⁶⁻¹⁹ Disease can be transferred to susceptible mice by injection of T cells that recognise myelin-associated protein. Semple antirabies vaccine contains a fair amount of neural antigens that can excite a cross reactive T cell response.²⁰ Probably genetic susceptibility explains why encephalomyelitic complications develop in only a small minority of patients who have received rabies vaccine prepared from rabbit brain, or have had measles. Of the many candidate polymorphic major histocompatibility complex (MHC) and non-MHC genes, which contribute to disease susceptibility, including those which encode for effector (cytokines and chemokines) or receptor molecules within the immune system, human leucocyte antigen class II genes have the most significant influence.²¹

Acute haemorrhagic leucoencephalitis is a more severe and frequently fatal hyperacute variant of ADEM. The pathological features of acute haemorrhagic leucoencephalitis are similar to that of hyperacute experimental allergic encephalomyelitis (HEAE). The most important distinguishing feature of acute haemorrhagic leucoencephalitis and HEAE (from ADEM and EAE respectively) is necrotising vasculitis of venules. Perivascular infiltrates consist mainly of polymorphonuclear cells. Perivascular haemorrhages are also common (table 1). Genetic susceptibility is possibly responsible for determining the occurrence of a particular type of encephalomyelitic variant.²²⁻²⁴

The exact molecular mechanisms that cause the death of oligodendrocytes in ADEM and its other variants are not known. Possibly, a complex interplay among cytokines, chemokines, and adhesion molecules is responsible for the cellular events of inflammatory encephalomyelitis. For example, tumour necrosis factor-alpha is considered an important factor in the pathogenesis of EAE.²⁵ It has been suggested that upregulation of Fas ligand (FasL) on autoreactive infiltrating T cells together with upregulation of Fas on resident cells in the target organ may lead to direct tissue destruction by an apoptotic pathway.²⁶ Active nitrogen species are overproduced in EAE and nitric oxide has been shown to mediate the death of oligodendrocytes.²⁷ In other suggested mechanisms, free oxygen radicals have been implicated in the death of premature oligodendrocytes.²⁸ Excitotoxicity could also be involved in the pathogenesis of demyelinating disorders.²⁹

Table 1 Pathological features of acute demyelinating disorders (modified from Scully *et al*²³)

Feature	ADEM	Acute multiple sclerosis	Acute haemorrhagic leucoencephalitis	Neuromyelitis optica
Perivascular infiltrates				
Lymphocytes	++	++	++	++
Macrophages or monocytes	++	++	++	++
Polymorphs	–	–	++	++
Eosinophils	–	–	–	++
Perivascular haemorrhage	–	–	++	–
Necrotising venules	–	–	++	+
Perivascular demyelination	±	±	++	++
Axonal damage	±	±	++	++

CLINICAL FEATURES

Systemic symptoms like fever, malaise, myalgias, headache, nausea, and vomiting often precede the neurological symptoms of ADEM. These systemic symptoms begin 4–21 days after the inciting event. The hallmark of clinical features of ADEM is the development of a focal or multifocal neurological disorder. The onset of the central nervous system disorder is rapid with peak dysfunction in several days. Initial clinical features include encephalopathy ranging from lethargy to coma, and focal and multifocal neurological signs like hemiparesis, cranial nerve palsies, and paraparesis. Other commonly reported findings include meningismus, ataxia, and varied movement disorders. Seizure may occur in severe cases, especially in the acute haemorrhagic form of ADEM. Optic neuritis is often bilateral and transverse myelopathy is often complete.^{5 30–34}

Recovery can begin within days; on occasion complete resolution is noted within a few days, but more frequently occurs over the course of weeks or months. The mortality varies between 10% and 30%, with complete recovery in 50%. Poor prognosis is correlated with severity and abruptness of onset of the clinical syndrome. In the case series after rabies vaccine, a mortality of 18% was recorded. After a mean follow up of 17 months, 68% of the survivors had completely recovered, and 32% had partially recovered, most with minimal deficits. In three patients in this series, a relapse of neurological deficit occurred during the recovery period. None of the patients experienced relapse once complete recovery had occurred.⁶ Measles virus associated ADEM may carry a worse prognosis than vaccine associated disease. However, with introduction of effective vaccination strategies and decline of measles, death is rare.

Young adults and children are most commonly affected, Schwarz *et al* recently reported a follow up study of 40 adult patients and noted that the rate of prior infection was lower.³¹ Most adult patients present clinically in a fashion similar to that of children, except that there is a relatively infrequent occurrence of headache, fever and meningismus, and a higher frequency of sensory deficits. Optic neuritis is also infrequent in adult ADEM.³¹

LABORATORY FEATURES

Cerebrospinal fluid

Cerebrospinal fluid may be normal but frequently it shows some changes. Typical cerebrospinal fluid changes include increased pressure, lymphocytic pleocytosis (as much as 1000/mm³, sometimes polymorphonuclear leucocytosis initially), and raised protein (usually <1.0 mg/l). The cerebrospinal fluid may contain increased amounts of gammaglobulin and IgG and raised levels of myelin basic protein. Glucose content is usually normal. Rarely, in cerebrospinal fluid oligoclonal band of IgG may be demonstrated. Production of intrathecal oligoclonal IgG almost ceases as the patient improves.^{2 22 24}

Electroencephalography

Electroencephalographic abnormalities are common but are usually non-specific. At times, specific electroencephalographic pictures like spindle coma pattern and alternating pattern have been described. Because of low sensitivity and specificity, electrophysiological studies are not routinely used to diagnose ADEM. Hollinger *et al* recently reported a series of 10 patients; magnetic resonance imaging (MRI) and cerebrospinal fluid findings were normal in five out of 10 patients and were only mildly abnormal in the remaining five patients. Interestingly, electroencephalography was abnormal in seven out of eight patients in whom it was performed. Abnormal electroencephalographic findings varied greatly and ranged from signs of increased sleepiness, mild generalised slowing, to severe generalised slowing with infrequent focal slowing and epileptiform discharges. Severe findings were recorded in three patients in whom electroencephalographic findings correlated fairly well with severity and the course of the clinical syndrome. In two young women, with initial suspicion of a psychiatric disease, electroencephalograms were helpful to prove the organic nature of unconsciousness.³⁵

Neuroimaging

Neuroimaging is extremely valuable in establishing the diagnosis of ADEM. Computed tomography is generally normal at onset and usually becomes abnormal 5–14 days later. The typical computed tomographic appearance is that of low attenuation, multifocal lesions in the subcortical white matter. At times, constant enhancement of the lesions has been reported.³⁶

Demyelinating lesions of ADEM are better visualised by MRI. These demyelinating lesions of ADEM usually exhibit no mass effect and can be seen scattered throughout the white matter of the posterior fossa and cerebral hemispheres (figs 1 and 2). Involvement of the cerebellum and brainstem is more common in children. Characteristic lesions seen on MRI appear as patchy areas of increased signal intensity on conventional T2-weighted images and on fluid attenuated inversion recovery sequence (FLAIR). Few MRI lesions may enhance after gadolinium administration. Extensive perifocal oedema may be seen. Though white matter involvement predominates grey matter can also be affected, particularly basal ganglion, thalami, and brainstem. Tumour-like lesions have also been reported in a few patients. In order to qualify as ADEM, lesions on MRI should be of the same age and no new lesion should appear on central nervous system imaging studies after the initial clinical attack. The corpus callosum is usually not involved in ADEM; infrequently its involvement has been reported, suggesting extensive lesion load. Corpus callosum involvement is more characteristic of multiple sclerosis. Thalamic involvement is exceedingly rare in multiple sclerosis but may be seen in 40% patients of ADEM, making this finding a potentially useful discriminator.^{31–34 37–40} MRI changes

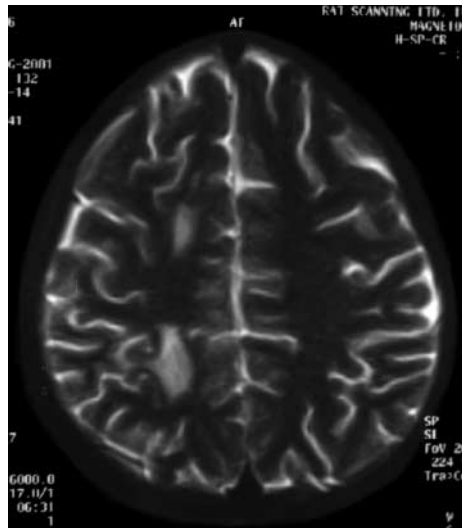


Figure 1 T2-weighted MRI showing multiple hyperintense lesions in the centrum semiovale of right cerebral hemisphere.

usually appear early in the course of the disease. Honkaniemi *et al* reported delayed MRI changes in ADEM. In their series, appearance of ADEM-associated MRI changes was associated with recovery from the disease.⁴¹

DIFFERENTIAL DIAGNOSIS

The diagnosis is considered straightforward when ADEM occurs after an exanthem or immunisation. A clear cut latent period between systemic symptoms and neurological illness favours ADEM along with the typical pattern of diffuse and multifocal involvement of both the central nervous system and peripheral nervous system and the characteristic MRI appearance. The most important issue associated with the diagnosis of ADEM is—can this disorder be diagnosed with certainty and differentiated from the initial manifestation of multiple sclerosis?^{42–44} Schwarz *et al*, in a cohort of 40 patients who were initially diagnosed as having ADEM, noted that 35% developed clinically definite multiple sclerosis (Poser's criteria) over a mean observation period of 38 months.³¹ Schwarz *et al* look at possible discriminating clinical features but fail to identify any exclusive feature characteristic of either condition. Similarly, cerebrospinal fluid findings are not distinctive enough to allow differentiation between ADEM and multiple sclerosis in a single patient. Even MRI studies were not able to differentiate ADEM from multiple sclerosis. Approximately, 50% of the patients with ADEM had MRI features that were suggestive of multiple sclerosis.³¹ In general, adult patients with ADEM tend to present with a more acute, widespread central nervous system disturbance, causing loss of consciousness and multifocal signs. Fever, loss of consciousness, and meningism are infrequently observed but are highly suggestive of ADEM because these symptoms are rare in multiple sclerosis. Hynson *et al* also noted a similar problem of differentiation between an initial attack of multiple sclerosis with ADEM, in children. These authors suggest that a viral prodrome, early onset ataxia, high lesion load on MRI, involvement of the deep cortical grey matter, and absence of oligoclonal bands are more indicative of ADEM.³⁴ Now, it is believed that distinguishing multiple sclerosis from ADEM on single MRI examination is virtually impossible. Serial studies performed at least six months apart may prove more helpful. The findings of new lesions are highly suggestive of multiple sclerosis. In ADEM, new lesions should not appear unless a clinical relapse has occurred.⁵ Gadolinium enhanced MRI can also help to distinguish these two demyelinating disorders as a mixture of enhancing and non-enhancing lesions implies

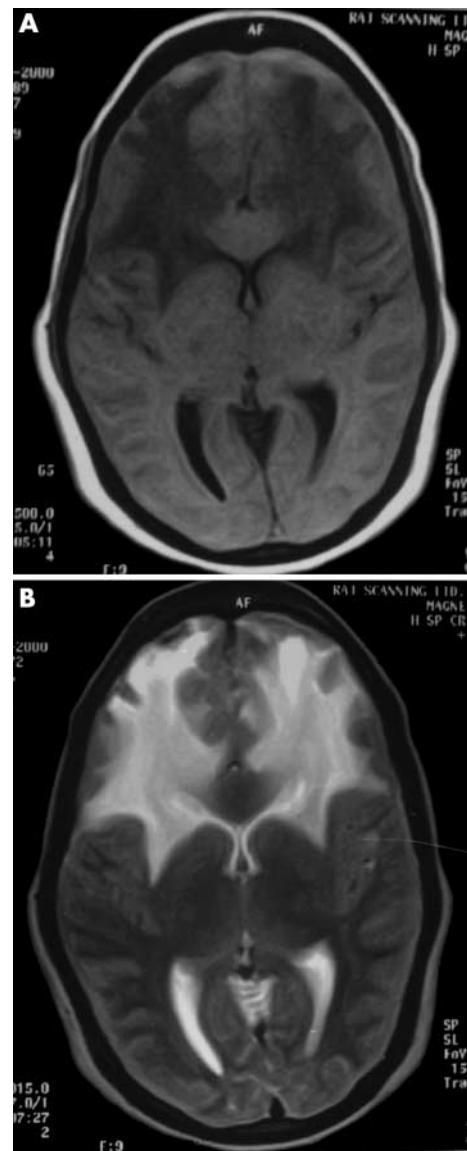


Figure 2 MRI of patient a week before a febrile illness. T1 (A) and T2 (B) images showing extensive bilateral demyelination of white matter of frontal lobes. This 20 year woman presented with bilateral vision loss, cerebellar manifestations, and with extensive pyramidal signs.

the temporal dissemination of multiple sclerosis. It is not clear whether “relapsing ADEM” exists as a separate entity from relapsing-remitting multiple sclerosis. One should be cautious in making the diagnosis, and should refer established criteria for the diagnosis of multiple sclerosis. The newly revised diagnostic criteria for multiple sclerosis allow the diagnosis of to be made after one attack if stringent MRI criteria are met. These criteria also emphasise that in monophasic demyelinating disease such as ADEM a diagnosis of multiple sclerosis should be withheld unless new symptoms and signs or imaging abnormalities appear more than three months after clinical onset.^{42–44–45}

Although ADEM is typically a disseminated process in the central nervous system, often with impaired sensorium, a few cases are dominated by spinal pathology (fig 3). Neuromyelitis optica (Devic's disease), sometimes caused by ADEM or systemic lupus erythematosus, may create diagnostic problems. Although stroke is the most common central nervous system feature in antiphospholipid syndrome, transverse myelitis and optic neuritis including Devic's syndrome have

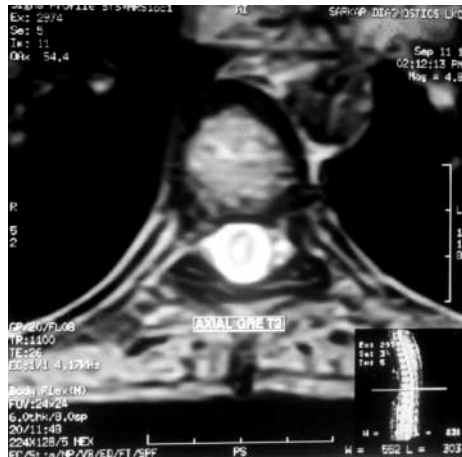

Figure 3 Axial T2-weighted MR image of thoracic spinal cord showing a centrally located hyperintense signal in a patient with ADEM having transverse myelopathy.

been described. MRI features described in patients with demyelinating disorders can also be seen in antiphospholipid syndrome. A clear distinction between an acute demyelinating disorder like ADEM and antiphospholipid syndrome can be difficult. Cuadrado *et al* in a recent article, suggested that a careful medical history, a previous history of thrombosis and/or fetal loss, an abnormal localisation of lesion on MRI, and the response to anticoagulant therapy might be helpful in the differential diagnosis of these two different diseases.⁴⁶

A combination of fever, seizures, altered sensorium, early parenchymal imaging abnormalities, and cerebrospinal fluid pleocytosis can cause confusion with viral encephalitis. A clear cut latent period between systemic symptoms and neurological illness favours ADEM, because of the typical pattern of diffuse and multifocal involvement of both the central nervous system and peripheral nervous system and the usual MRI appearance.⁴² Epidemic occurrence of central nervous system symptoms, absence of focal signs, and persisting systemic involvement are more likely in viral encephalitis. In an endemic region patients with ADEM may also need to be differentiated from a postmalarial neurological syndrome.^{47, 48} This syndrome has been defined as the acute onset of neurological or neuropsychiatric symptoms in patients recently recovered from *Plasmodium falciparum* malaria who have negative blood films at the time of onset of symptoms. There are certain similarities between ADEM and postmalarial neurological syndrome. These are latency from infection to neurological dysfunction, multifocal neurological deficits, response to steroids, good prognosis, and identical white matter MRI abnormalities. Mohsen *et al* believe that ADEM and postmalarial neurological syndrome are indistinguishable,⁴⁸ so *P falciparum* should be added to the list of infections that are able to precipitate ADEM.

On MRI, multiple patchy areas of increased signal intensity—as demonstrated on conventional T2-weighted, proton density weighted MRI and FLAIR sequence—in the subcortical white matter have a long list of differential diagnoses (box 3).⁵ Cerebral MRI abnormalities with other multifocal disease process that give rise to hyperintense T2-weighted lesions may have appearances and locations that are not typical of ADEM. For example, the periventricular lesions of vascular origin tend to be more peripheral than those of ADEM lesions. Multifocal hyperintensities on T2-weighted images associated with aging tend to be smaller and more randomly scattered throughout deep and subcortical white matter. These lesions are usually not visible on T1-weighted images and are confined to the patients who are more than 50 years of age. When such lesions are more extensive they tend to involve the periventricular white matter in a confluent symmetrical fashion.³⁵

Box 3: Causes of patchy areas of increased signal intensity in T2-weighted images on MRI

- Multiple sclerosis.
- Vasculitis.
- Reversible posterior leucoencephalopathy.
- Eclampsia.
- Subcortical arteriosclerotic leucoencephalopathy.
- Neurosarcoidosis.
- Progressive multifocal leucoencephalopathy.
- HIV encephalopathy.
- Subacute sclerosing panencephalitis.
- Mitochondrial encephalopathy.
- Leucodystrophies.
- Toxic encephalopathies.
- Osmotic myelinolysis.
- Aging.

TREATMENT

The treatment of ADEM is targeted to suppress a presumed aberrant immune response to an infectious agent or a vaccination. Treatment with intravenous corticosteroids (methylprednisolone) or adrenocorticotropic hormone in large doses has been shown to improve the outcome.^{31, 49} Approximately two thirds of the patients who are treated with corticosteroids benefit from the treatment; however, it is difficult to evaluate exact potential benefit of these therapies, as only case reports and series with small number of patients are available and there has been no controlled trial of their use. In some cases where corticosteroids have failed to work, use of plasmapheresis⁵⁰ or intravenous immunoglobulin⁵¹⁻⁵³ has been shown to produce dramatic improvement. Keegan *et al* recently reviewed 59 consecutive patients with plasma exchange for acute severe attacks of central nervous system demyelination at the Mayo clinic. This series included 10 patients with ADEM and neuromyelitis optica plus 22 patients with relapsing-remitting multiple sclerosis. The remainder had miscellaneous demyelinating disorders such as acute transverse myelitis and Marburg variant of multiple sclerosis. Among 20 patients with ADEM and neuromyelitis optica 50% showed moderate or marked improvement. For the whole group of 59 patients, it was concluded that certain factors like male sex, preserved reflexes, and early initiation of treatment were associated with improvements. Successfully treated patients improved rapidly after plasma exchange and improvement was sustained.⁵⁴ In some cases cytotoxic agents have been used with success.³¹

As has been suggested previously, a persistent infection may contribute directly to the central nervous system inflammation and demyelination. It has been argued that antimicrobial therapy, if initiated soon enough, could possibly limit the infection and resulting neurotoxic immune response. Unfortunately, there are currently no effective treatments available for many of viruses implicated in ADEM, so this option remains a theoretical possibility.⁵

PROGNOSIS

It has been observed that methylprednisolone therapy shortens the duration of neurological symptoms and immediately halts further progression. As far as long term prognosis of ADEM is concerned, in one of the largest follow up series of 40 adult patients (15–68 years, mean 33.5 years) with ADEM, 14 patients developed clinically definite multiple sclerosis. Out of the remaining 26 patients with a final diagnosis of ADEM, two patients died, nine had minor residual deficits, three had moderate deficits, and 12 patients had no remaining symptoms. In all patients who progressed to multiple sclerosis, the second episode occurred within the first year of initial presentation. In the longest follow up (eight years) of

11 patients with final diagnosis of ADEM, none experienced a new clinical attack during follow up and new white matter MRI lesions were detectable in only one patient. Recurrences in ADEM were defined as appearance of new symptoms and signs at least one month after the previous episode. The patients with the final diagnosis of ADEM were older and more often had a preceding infection, clinical signs of brainstem involvement, a higher cerebrospinal fluid albumin fraction, and infratentorial lesions.³¹ In another study, Cohen *et al* followed up 21 patients with ADEM: five patients had recurrent disease episodes, three patients had three or more recurrences. A very good response to corticosteroids was observed in each recurrence episode. Patients who relapsed tended to have more than one recurrence that usually involved (clinically and radiologically) a brain territory that was affected before. Neuropsychiatric features were the main presentation of a relapse. These authors conclude that recurrence in ADEM is more common than previously recognised; since recurrent ADEM is a corticosteroid-responsive condition, awareness about the disease and early diagnosis are mandatory.⁵⁵

In one of the recently published series of ADEM in 31 children, 81% of patients recovered completely with various immunomodulator agents.³⁴ In the remaining five patients only mild neurological sequelae were recorded. None of the patients died during follow up. In this series, four patients had relapses, and three of these had involvement of the corpus callosum on MRI (the authors considered this a feature suggestive of multiple sclerosis), even then the authors did not think that any of these patients had multiple sclerosis. In another paediatric series by Belopitova *et al*, 25 children aged of 3–18 years with an initial diagnosis of ADEM were followed up for a period of 2–8 years.³⁶ In 10 children there were data for clinically definite or laboratory supported definite multiple sclerosis. The remaining 15 children in this study were suspected to have multiple sclerosis. These authors think that the dynamic long term follow up (with the help of neuroimaging, cerebrospinal fluid, and evoked potential studies) of pathological changes is of prognostic significance for the course of the disease, which could be a definite cessation of the process in ADEM cases or transition to multiple sclerosis.

ADEM—A DISTINCT DISEASE OR PART OF THE MULTIPLE SCLEROSIS SPECTRUM?

One of the most intriguing features of ADEM is its exact relation with multiple sclerosis. Because of many similarities in clinical features, MRI findings, and pathogenesis several authors believe that ADEM is part of the multiple sclerosis spectrum.⁴² The precipitants of demyelination in both conditions may be an infectious (especially viral) illness and share the major pathogenetic characteristic of an obligatory alteration of blood-brain barrier. However, the mechanisms of myelin destruction may be different. It is well known that multiple sclerosis is more prevalent in certain races because of genetic predisposition, while ADEM is seen in all races and geographical areas. In India and other developing countries ADEM is a common disease, but multiple sclerosis is infrequently seen. Here a large number of cases of ADEM occur after specific viral infections (for example, measles) or after the use of outdated vaccines and because the incidence of various specific infections that may predispose to ADEM is still high and Semple antirabies vaccine is still in use.⁵⁷ ADEM caused by Semple antirabies vaccine is often associated with involvement of the peripheral nervous system in the form of radiculoneuropathy.³⁰ In contrast to reports from Western countries, conversion of ADEM to multiple sclerosis has not been reported from developing countries. Modi *et al* recently described eight black South African patients (a population with a low risk of multiple sclerosis) with a new multiphasic

steroid-responsive demyelinating disorder of the central nervous system. Neuroimaging in these patients showed features consistent with those described for ADEM as well as some features that were described in multiple sclerosis. These patients had two or more distinct acute attacks of a demyelinating disorder separated in space and time generally with poor outcome and stepwise disabilities after repeated attacks. Authors were not sure about the exact diagnosis in any of the cases.⁵⁸ Therefore, it can be argued that ADEM seen in developing countries is a distinct syndrome and is not part of the multiple sclerosis spectrum.

CONCLUSION

ADEM is a monophasic inflammatory disease affecting the central nervous system, which usually follows an infection or vaccination. It is difficult to differentiate ADEM from a single episode of multiple sclerosis because of the largely similar clinical presentation, cerebrospinal fluid analysis, histopathological and neuroimaging appearance. Recent literature indicates that a significant proportion of adult and paediatric patients with ADEM develop clinically definite multiple sclerosis in due course. However, it is not possible to identify with certainty any clinical marker, which can differentiate ADEM from the initial presentation of multiple sclerosis. Experts now believe that ADEM and multiple sclerosis are parts of the same spectrum of inflammatory demyelinating conditions. In India and other developing countries ADEM is a common neurological condition, possibly because of the high prevalence of causative infections. However, the reasons for the low occurrence of multiple sclerosis are not known.

.....

Author's affiliation

Department of Neurology, King George's Medical College, Lucknow, India

REFERENCES

- Murthy SNK, Faden HS, Cohen ME, *et al*. Acute disseminated encephalomyelitis in children. *Pediatrics* 2002;**110**(2) (<http://www.pediatrics.org/cgi/content/full/110/2/e21>).
- Murthy JM, Yangala R, Meena AK, *et al*. Acute disseminated encephalomyelitis: clinical and MRI study from South India. *J Neurol Sci* 1999;**165**:133–8.
- Litvak AM, Sands JJ, Gibel H. Encephalitis complicating measles: report of 56 cases with follow-up studies in 32. *Am J Dis Child* 1943;**65**:265–95.
- Miller HG, Evans MJ. Prognosis in acute disseminated encephalomyelitis: with a note of neuromyelitis optica. *Q J Med* 1953;**22**:247–79.
- Stuve O, Zamvil SS. Pathogenesis, diagnosis and treatment of acute disseminated encephalomyelitis. *Curr Opin Neurology* 1999;**12**:395–401.
- Held JR, Adros HL. Neurological disease in man following administration of suckling mouse brain antirabies vaccine. *Bull World Health Organ* 1972;**46**:321–7.
- Label LS, Batts DH. Transverse myelitis caused by duck embryo rabies vaccine. *Arch Neurol* 1982;**39**:426–30.
- Swamy HS, Shankar SK, Satish Chandra P, *et al*. Neurological complications due to beta-propiolactone (BPL) inactivated antirabies vaccination. *J Neurol Sci* 1984;**63**:111–28.
- Hemchudha T, Griffin DE, Giffels JJ, *et al*. Myelin basic protein as an encephalitogen in encephalomyelitis and polyneuritis following rabies vaccination. *N Engl J Med* 1987;**316**:369–74.
- Murthy JMK. MRI in acute disseminated encephalomyelitis following Semple antirabies vaccine. *Neuroradiology* 1998;**40**:420–3.
- Chakrawarty A. Neurologic illness following post-exposure prophylaxis with purified chick embryo cell antirabies vaccine. *J Assoc Physicians India* 2001;**44**:927–8.
- Fenichel GM. Neurological complications of immunization. *Ann Neurol* 1982;**12**:119–28.
- Nalin DR. Mumps, measles and rubella vaccination and encephalitis (letter). *BMJ* 1989;**299**:1219.
- van Bogaert L. Post-infectious encephalomyelitis and multiple sclerosis: the significance of perivenous encephalomyelitis. *J Neuropathol Exp Neurol* 1950;**9**:219–49.
- Allen IV. Demyelinating diseases. *Greenfield's neuropathology*. 4th Ed. In: Adams JH, Corsellis JAN, Duchon LW, eds. London: Edward Arnold, 1984: 338–84.
- Davies JM. Molecular mimicry: can epitope mimicry induce autoimmune disease? *Immunol Cell Biol* 1997;**75**:113–26.

- 17 **Johnson RT**. Pathogenesis of acute viral encephalitis and postinfectious encephalomyelitis. *J Infect Dis* 1987;**155**:359–64.
- 18 **Zamvil SS**, Steinman L. The T lymphocyte in experimental allergic encephalomyelitis. *Annu Rev Immunol* 1990;**8**:579–621.
- 19 **Gold R**, Hartung HP, Toyka KV. Animal models for autoimmune demyelinating disorder of the nervous system. *Mol Med Today* 2000;**62**:88–91.
- 20 **Laouini D**, Kennou MF, Khoufi S, et al. Antibodies to human myelin proteins and gangliosides in patients with acute neuroparalytic accident induced by brain-derived rabies vaccine. *J Neuroimmunol* 1998;**91**:63–72.
- 21 **'t Hart BA**, Brok HP, Amor S, et al. The major histocompatibility complex influences the ethiopathogenesis of MS-like disease in primates at multiple levels. *Hum Immunol* 2001;**62**:1371–81.
- 22 **Scully RE**, Mark EJ, McNeely WF, et al. Case records of the Massachusetts General Hospital, case 37–1995. *N Engl J Med* 1995;**333**:1485–92.
- 23 **Scully RE**, Mark EJ, McNeely WF, et al. Case records of the Massachusetts General Hospital, case 1–1999. *N Engl J Med* 1999;**340**:127–35.
- 24 **Stefansson K**, Hedley-Whyte ET. Case records of the Massachusetts General Hospital, case 8–1996—a 28 years old woman with rapid development of a major personality change and global aphasia. *N Engl J Med* 1996;**334**:715–21.
- 25 **Liu J**, Marino MW, Wong G, et al. TNF is a potent anti-inflammatory cytokine in autoimmune-mediated demyelination. *Nat Med* 1998;**4**:78–83.
- 26 **Sabelko-Downes KA**, Russell JH, Cross AH. Role of Fas–FasL interactions in the pathogenesis and regulation of autoimmune demyelinating disease. *J Neuroimmunol* 1999;**100**:42–52.
- 27 **Boullerne AI**, Nedelkoska L, Benjamins JA. Role of calcium in nitric oxide-induced cytotoxicity: EGTA protects mouse oligodendrocytes. *J Neurosci Res* 2001;**63**:124–35.
- 28 **van der Goes A**, Brouwer J, Hoekstra K, et al. Reactive oxygen species are required for the phagocytosis of myelin by macrophages. *J Neuroimmunol* 1998;**92**:67–75.
- 29 **Matute C**, Alberdi E, Domezq M, et al. The link between excitotoxic oligodendroglial death and demyelinating diseases. *Trends Neurosci* 2001;**24**:224–30.
- 30 **Murthy JMK**, Yangala R, Meena AK, et al. Clinical, electrophysiological and magnetic resonance imaging study of acute disseminated encephalomyelitis. *J Assoc Physicians India* 1999;**47**:280–3.
- 31 **Schwarz S**, Mohr A, Knauth M, et al. Acute disseminated encephalomyelitis: a follow-up study of 40 adult patients. *Neurology* 2001;**56**:1313–18.
- 32 **Apak RA**, Kose G, Anlar B, et al. Acute disseminated encephalomyelitis in childhood: report of 10 cases. *J Child Neurol* 1999;**14**:198–201.
- 33 **Dale RC**, de Sousa C, Chong WK, et al. Acute disseminated encephalomyelitis, multiphasic disseminated encephalomyelitis and multiple sclerosis in children. *Brain* 2000;**123**:2407–22.
- 34 **Hynson JL**, Kornberg AJ, Coleman IT, et al. Clinical and neuroradiologic features of acute disseminated encephalomyelitis in children. *Neurology* 2001;**56**:1308–12.
- 35 **Hollinger P**, Sturzenegger M, Mathis J, et al. Acute disseminated encephalomyelitis in adults: a reappraisal of clinical CSF, EEG and MRI findings. *J Neurol* 2002;**249**:320–9.
- 36 **Lukes SA**, Norman D. Computed tomography in acute disseminated encephalomyelitis. *Ann Neurol* 1983;**13**:567–72.
- 37 **Caldmeyer KS**, Smith RR, Harris TM, et al. MRI in acute disseminated encephalomyelitis. *Neuroradiology* 1994;**36**:216–20.
- 38 **Singh S**, Alexander M, Korah IP. Acute disseminated encephalomyelitis: MR imaging features. *AJR Am J Roentgenol* 1999;**173**:1101–7.
- 39 **O'Riordan JI**, Gomez-Anson B, Moseley IF, et al. Long term MRI follow-up of patients with post-infectious encephalomyelitis: evidence for a monophasic disease. *J Neurol Sci* 1999;**167**:132–6.
- 40 **Bizzi A**, Ulug AM, Crawford TO, et al. Quantitative proton MR spectroscopic imaging in acute disseminated encephalomyelitis. *AJNR Am J Neuroradiol* 2001;**22**:1125–30.
- 41 **Honkaniemi J**, Dastidar P, Kahara V, et al. Delayed MR imaging changes in acute disseminated encephalomyelitis. *AJNR Am J Neuroradiol* 2001;**22**:1117–24.
- 42 **Hartung HP**, Grossman RI. ADEM: distinct disease or part of MS spectrum? *Neurology* 2001;**56**:1257–60.
- 43 **Singh S**, Prabhakar S, Korah IP, et al. Acute disseminated encephalomyelitis and multiple sclerosis: magnetic resonance imaging differentiation. *Australas Radiol* 2000;**44**:404–11.
- 44 **Barkhof F**, Filippi M, Miller DH, et al. Comparison of MR imaging criteria at first presentation to predict conversion to clinically definite multiple sclerosis. *Brain* 1997;**120**:2059–69.
- 45 **Hung KL**, Liao HT, Tsai ML. Post-infectious encephalomyelitis: etiologic and diagnostic trends. *J Child Neurol* 2000;**15**:666–70.
- 46 **Cuadrado MJ**, Khamashta MA, Ballesteros A, et al. Can neurologic manifestations of Hughes (antiphospholipid) syndrome be distinguished from multiple sclerosis? *Medicine* 2000;**79**:57–68.
- 47 **Dey KB**, Trikha I, Banerjee M, et al. Acute disseminated encephalomyelitis—another cause of postmalaria cerebellar ataxia. *J Assoc Physicians India* 2001;**49**:756–8.
- 48 **Mohsen AH**, Mckendrick MW, Schmid ML, et al. Postmalaria neurological syndrome: a case of disseminated encephalomyelitis. *J Neurol Neurosurg Psychiatry* 2000;**68**:388–90.
- 49 **Straub J**, Chofflon M, Delavelle J. Early high-dose intravenous methyl prednisolone in acute disseminated encephalomyelitis: a successful recovery. *Neurology* 1997;**49**:1145–7.
- 50 **Kanter DS**, Horensky D, Sperling RA, et al. Plasmapheresis in fulminant acute disseminated encephalomyelitis. *Neurology* 1995;**45**:824–7.
- 51 **Pradhan S**, Gupta RP, Shashank S, et al. Intravenous immunoglobulin therapy in acute disseminated encephalomyelitis. *J Neurol Sci* 1999;**165**:56–61.
- 52 **Sahlas DJ**, Miller SP, Guerin M, et al. Treatment of acute disseminated encephalomyelitis with intravenous immunoglobulin. *Neurology* 2000;**54**:1370–2.
- 53 **Marchioni E**, Marinou-Aktipi K, Uggetti C, et al. Effectiveness of intravenous immunoglobulin treatment in adult patients with steroid resistant monophasic or recurrent acute disseminated encephalomyelitis. *J Neurol* 2002;**249**:100–4.
- 54 **Keegan M**, Pineda AA, McClelland RL, et al. Plasma exchange for severe attacks of CNS demyelination: predictors of response. *Neurology* 2002;**58**:143–6.
- 55 **Cohen O**, Steiner-Birmanns B, Biran I, et al. Recurrence of acute disseminated encephalomyelitis at the previously affected brain site. *Arch Neurol* 2001;**38**:797–801.
- 56 **Belopitova L**, Guerguellecheva PV, Bojinova V. Definite and suspected multiple sclerosis in children: long term follow-up and magnetic resonance imaging findings. *J Child Neurol* 2001;**16**:317–24.
- 57 **Chou HVV**, Hien TT, Sellar R, et al. "Can't you use another vaccine"? Post-rabies vaccination encephalitis [letter]. *J Neurol Neurosurg Psychiatry* 1999;**67**:555–6.
- 58 **Modi G**, Mochan A, Modi M, et al. Demyelinating disorder of the central nervous system occurring in black South Africans. *J Neurol Neurosurg Psychiatry* 2001;**70**:500–5.