

Complication of alcoholism

Purple skin and a swollen thigh in an alcoholic

**A R Vasudevan, S Kumar, A Lim, R Kimani,
J M Brensilver, F M Tamarin**

Answers on p 434.

A 46 year old man with a history of alcohol abuse was admitted with insidious onset, progressive left thigh swelling and abnormal skin lesions over an extensive part of his left thigh. There was no history of trauma. Examination revealed a jaundiced adult male, with hepatomegaly (liver edge felt 4 cm beneath the right costal margin; liver span 14 cm) and prominent skin lesions mainly involving the left thigh (fig 1). These lesions were not palpable. There was no mucosal or joint involvement. The left thigh was enlarged (girth about 1.4 times that of the right) and exquisitely tender, but there was no evidence of neurovascular compromise in the affected limb. The spleen was not palpable and there were no stigmata of chronic liver failure.

Laboratory test results (normal range in parentheses) were as follows: haemoglobin 92 g/l (140–180 g/l); leucocyte

count $8.1 \times 10^9/l$ ($4-11 \times 10^9/l$); platelet count $87 \times 10^9/l$ ($130-400 \times 10^9/l$); mean corpuscular volume 102.3 fl (86–98 fl); red cell distribution width 15.2% (13%–15%); reticulocyte count 3.63% (0.2%–2%); total bilirubin 241 $\mu\text{mol/l}$ (5.1–17 $\mu\text{mol/l}$); direct bilirubin 132 $\mu\text{mol/l}$ (1.7–5.1 $\mu\text{mol/l}$); serum albumin 25 g/l (33–55); aspartate aminotransferase 197 U/l (0–35 U/l); alanine aminotransferase 32 U/l (0–35 U/l); alkaline phosphatase 221 IU/l (30–120 IU/l); γ -glutamyl transpeptidase 107 IU/l (8–51 IU/l); international normalised ratio (INR) 1.33 (0.7–1.1); and activated partial thromboplastin time 36.2 sec (control 33.4 sec). Serum levels of vitamin B12, folate, ferritin, iron, transferrin, thyroid stimulating hormone, and α -fetoprotein were within normal limits. Hepatitis viral screen for A, B, and C viruses were negative. Ultrasonography

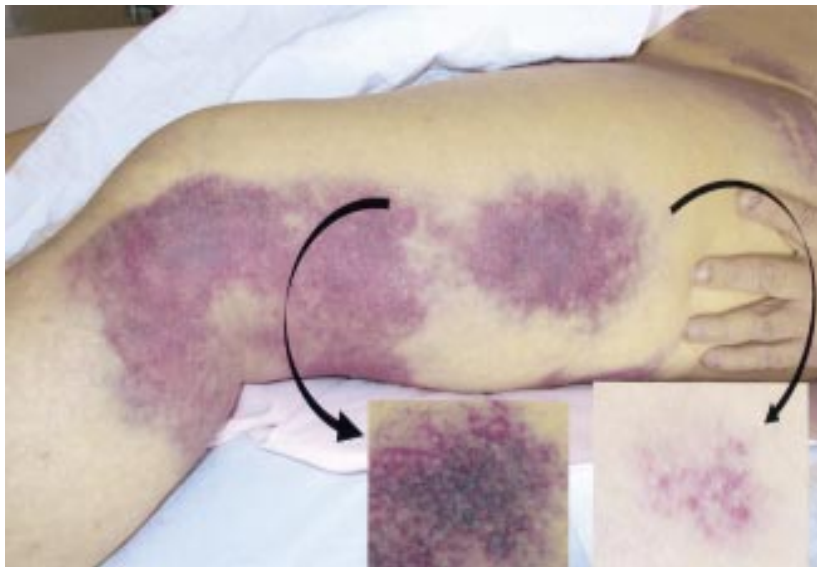


Figure 1 Skin lesions on left thigh.

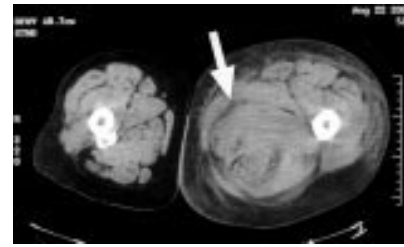


Figure 2 Computed tomogram showing grossly enlarged left thigh.

and computed tomography of the abdomen were consistent with a diagnosis of steatohepatitis and gallstones. Magnetic resonance cholangiopancreatography revealed cholelithiasis, a dilated common bile duct (9 mm) without stones and a normal pancreatic duct. Arterial and venous Doppler studies of lower extremities excluded arterial insufficiency and deep venous thrombosis. Radiography of the left thigh did not reveal long bone fracture. A non-contrast computed tomogram (fig 2) showed a grossly enlarged left thigh with areas of increased attenuation in between, and within muscle groups, most prominent in the posteromedial aspect (fig 2, white arrow). This was thought to represent an extensive soft tissue haematoma.

QUESTIONS

- (1) How would you describe these skin lesions? What is the differential diagnoses?
- (2) What is the most likely cause of this patient's skin lesions and thigh abnormality? What features of the skin lesion (fig 1, inset) suggests this diagnosis? How will you confirm the diagnosis?
- (3) How is this condition treated?

Postgrad Med J 2002;**78**:430

Authors' affiliations

A R Vasudevan, S Kumar, A Lim, R Kimani, J M Brensilver, F M Tamarin, Department of Medicine, Sound Shore Medical Center of Westchester, New York Medical College, 16 Guion Place, New Rochelle, NY 10802, USA

Correspondence to: Dr Tamarin; ssmcw@hotmail.com

Submitted 8 January 2002

Accepted 20 February 2002

Multiple infarcts

An unusual case of multiple infarcts

A K O Denniston, J M Beattie

Answers on p 434.

A 44 year old woman presented to the accident and emergency department with sudden onset of severe dyspnoea, right sided weakness, and loss of speech. She was a smoker, but had no other identifiable risk factors for premature atherosclerotic disease. There was no significant medical history and no history of recent trauma. She was afebrile with a regular tachycardia at 120 beats/min. She was hypoxic with inspiratory crackles up to the mid-zones bilaterally. She had an expressive dysphasia with a right sided hemiparesis. An electrocardiogram (ECG) demonstrated sinus tachycardia with extensive anterior ST elevation consistent with acute anterior myocardial infarction. A chest radiograph confirmed the clinical impression of pulmonary oedema; heart size was normal.

The patient exhibited progressive respiratory failure requiring ventilatory support. Thrombolysis for the extensive anterior myocardial infarct was contraindicated by the apparent stroke. An emergency computed tomogram of the head showed no abnormality, but could not exclude an early cerebral infarct. Full blood count and routine biochemistry

were normal; the erythrocyte sedimentation rate was 63 mm/hour. Cardiological intervention was sought with a view to primary angioplasty. Emergency coronary angiography showed normal coronary artery anatomy with no obstructive lesion or occlusion. Left ventriculography showed extensive anterior hypokinesia consistent with an acute myocardial infarction, but also disclosed a mobile filling defect limited to diastole. The ECG (fig 1), transthoracic echocardiogram (fig 2), and a biopsy taken during a subsequent procedure (fig 3) are shown.

QUESTIONS

- (1) What are the differential diagnoses before imaging?
- (2) What does the echocardiogram show?
- (3) What is the final diagnosis?
- (4) What is the treatment?
- (5) What is the prognosis?
- (6) Is there any risk to her children?
- (7) How could the diagnosis have been made earlier?

Postgrad Med J 2002;**78**:431

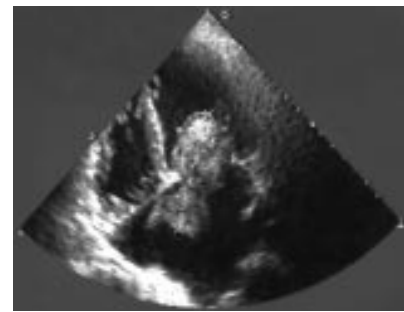


Figure 2 Transthoracic echocardiogram (four chamber view).



Figure 3 Histology.

Authors' affiliations

A K O Denniston, J M Beattie, Birmingham Heartlands Hospital, UK

Correspondence to: Dr Alastair Denniston, Department of Cardiology, Birmingham Heartlands Hospital, Bordesley Green East, Birmingham B9 5SS, UK; alastair@denniston.org

Submitted 3 October 2001

Accepted 4 January 2002

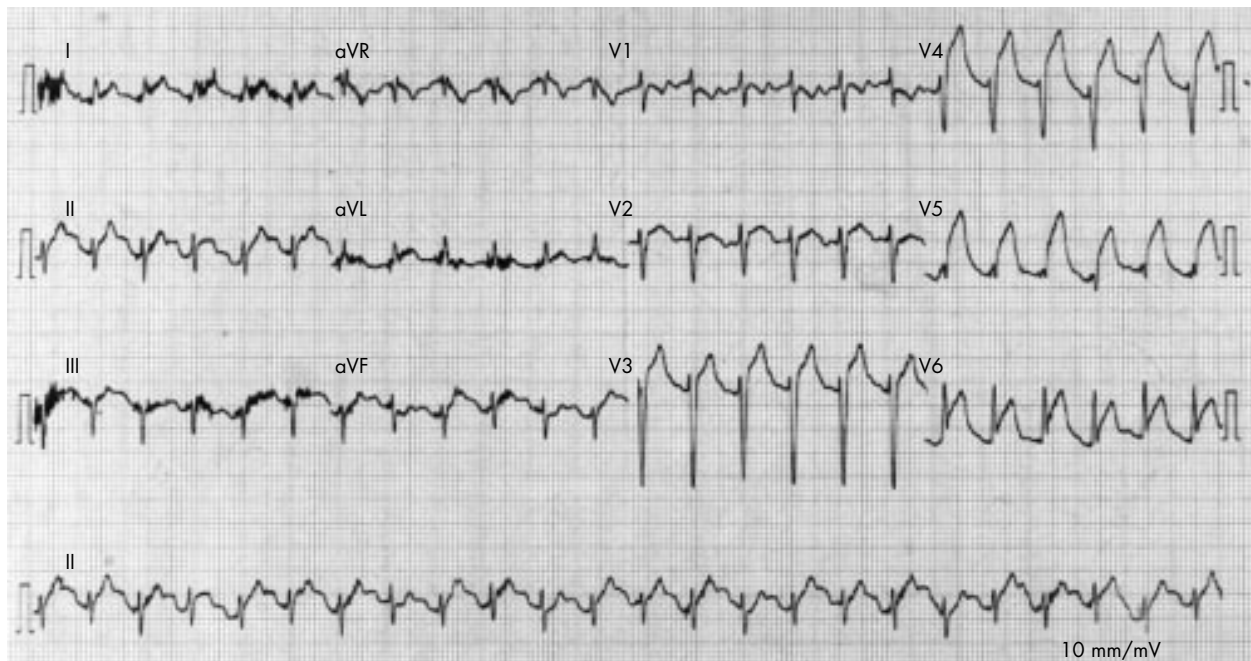


Figure 1 Electrocardiogram.

Abdominal distension

Abdominal distension

A Mukhtar, N Sundar, I A Finnie

Answers on p 435.

An 87 year old woman presented with a two month history of abdominal distension and vomiting. Previous investigations for iron deficiency anaemia had been normal. There was no recent change in bowel habit. On examination she was afebrile. The abdomen was soft, distended, with no tenderness or guarding and the bowel sounds were normal. A detail from the plain abdominal radiograph is shown (fig 1), together with a representative film from a subsequent investigation (fig 2).

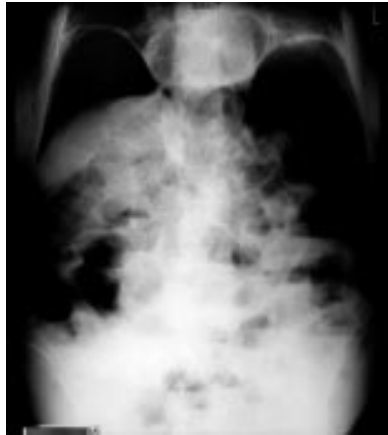

Figure 1 Plain abdominal radiograph.

QUESTIONS

- (1) What does the plain abdominal radiograph (fig 1) show? What was the subsequent investigation (fig 2) and what does this show?
- (2) How would you manage this patient?

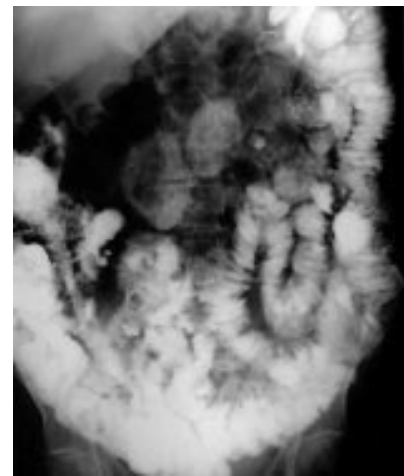


Figure 2 Film from a subsequent investigation.

- (3) What mechanism results in the development of the radiological abnormality shown in fig 1?

Postgrad Med J 2002;**78**:432

Authors' affiliations

A Mukhtar, N Sundar, I A Finnie, Department of Gastroenterology, Glan Clwyd Hospital, Bodelwyddan, Denbighshire LL18 5UJ, UK

Correspondence to: Dr Finnie; Jo.Barlow@cd-tr.wales.nhs.uk

Submitted 8 January 2002

Accepted 6 February 2002

Infection

Prolonged fever with recurrent diarrhoea

R Sivakumar, A Edey, A Thakore, M D Pelly

Answers on p 436.

A 52 year old man presented with a history of right groin pain. He also recollected at least three self limiting episodes of rigors, diarrhoea, and vomiting lasting for about four days in the recent past. Over the past year he had

travelled worldwide with no reported medical illness. He was febrile and a pulsatile tender mass was felt in the right iliac fossa. Ultrasound scan revealed a common iliac aneurysm measuring 3.5 cm in diameter.

QUESTIONS

- (1) What is the single most important investigation?
- (2) What is the diagnosis?
- (3) What are the risk factors for this complication?

Postgrad Med J 2002;**78**:432

Authors' affiliations

R Sivakumar, A Edey, A Thakore, M D Pelly, Department of Medicine, Chelsea and Westminster Hospital, London, UK

Correspondence to: Dr R Sivakumar, 4 Aston Close, Lister Hospital, Stevenage SG1 4TT, UK; sivasiva51@hotmail.com

Submitted 30 July 2001

Accepted 19 October 2001

Pleuritic pain

Pleuritic pain and a rare complication

J M Pillai, P Mitchenere, S Smith, D J B Thomas

Answers on p 436.

A 25 year old man presented with a two week history of malaise. Following a sore throat he had developed dyspnoea, a productive cough, anorexia, and vomiting. Two days before admission he had haemoptysis and left sided pleuritic pain with shoulder discomfort. On examination he had a pyrexia (38°C), mild cervical lymphadenopathy, and right sided chest crepitations. His chest radiograph showed pneumonia (see fig 1) and on electrocardiography there was T wave inversion in lead 3. Arterial blood gas analysis showed hypoxia (oxygen tension 7.19 kPa). He was given oxygen, rehydrated, and treated with co-amoxiclav and erythromycin. The next day he developed severe left sided pleuritic pain and further treatment was added. On day 3 he had an episode of syncope but the electrocardiogram and observations remained stable. His haemoglobin level had dropped from 158 g/l to 86 g/l.

By day 4 he had a tachycardia (140 beats/min) and developed generalised abdominal pain. At this stage clinical

examination of the abdomen was normal. An urgent abdominal computed tomogram was done (see fig 2). His haemoglobin dropped further to 62 g/l. The surgeons were immediately informed of his condition and he underwent emergency surgery. He made a gradual uncomplicated postoperative recovery.

QUESTIONS

(1) Given his history of haemoptysis and subsequent severe pleuritic pain, what

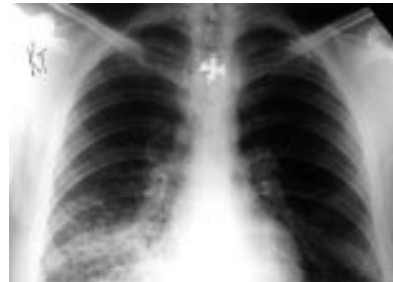

Figure 1 Chest radiograph.

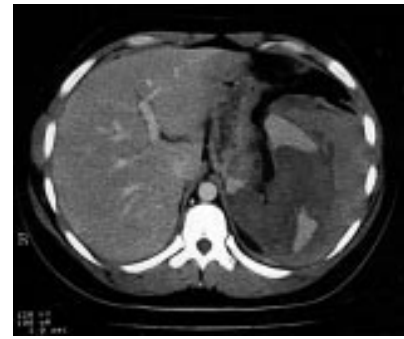

Figure 2 Abdominal computed tomogram.

further diagnosis would you consider and how would you treat this?

(2) What condition was diagnosed from his computed tomogram and what further management was indicated?

(3) What did the laboratory find on reviewing this patient's blood film?

(4) What follow up testing did they perform and what diagnosis was made?

(5) What is the significance of his shoulder discomfort?

Postgrad Med J 2002;78:433

Authors' affiliations

J M Pillai, P Mitchenere, S Smith, D J B Thomas, Hillingdon Hospital, Pield Heath Road, Uxbridge, Middlesex UB8 3NN, UK

Correspondence to: Dr Thomas; djbowenthomas@lineone.com

Submitted 29 January 2002

Accepted 26 March 2002

and chest were normal and blood culture was negative. An ultrasound scan of the abdomen was unremarkable. She was given intravenous fluids and treated symptomatically with antiemetics.

QUESTIONS

(1) What further investigations would you perform and how would they help you?

(2) What is "short bowel" syndrome and how does it cause hyponatraemia?

(3) What is the diagnosis here and how did this possibly cause hyponatraemia?

Postgrad Med J 2002;78:433

Authors' affiliations

P De, R K Shrimali, S Subramonian, D F Child, Department of Medicine, Diabetes and Endocrinology, Wrexham Maelor Hospital, Wrexham LL13 7TD, UK

Correspondence to: Dr P De; parijatde@tesco.net

Submitted 13 February 2002

Accepted 4 April 2002

Hyponatraemia

An unusual endocrine cause of hyponatraemia

P De, R K Shrimali, S Subramonian, D F Child

Answers on p 437.

A 60 year old woman with no medical history of note except panproctocolectomy and ileostomy for Crohn's disease was admitted with a week's history of dizziness, lethargy, anorexia, vomiting, and confusion. She was found to have increased stoma volumes for a few days before admission and was on no particular medication. On examination, she was afebrile, dehydrated, and slightly disorientated with a pulse of 110 beats/min and blood pressure 100/60 mm Hg (no postural drop).

Her abdomen was soft and stoma site intact but there was diffuse abdominal tenderness with intact peristaltic sounds. The rest of the general and systemic examination was unremarkable.

Investigations revealed a normal full blood count, C reactive protein, plasma glucose, liver function, arterial blood gas, and lipid profile. Her serum sodium concentration was low at 107 mmol/l, potassium 6.0 mmol/l, urea 8.5 mmol/l, and creatinine 80 mmol/l. Electrocardiography and radiography of the abdomen