

## CASE REPORT

# Adult Still's disease and respiratory failure in a 74 year old woman

G S Stoica, R I Cohen, L J Rossoff

*Postgrad Med J* 2002;**78**:97–98

A case of adult onset Still's disease in an elderly woman, that was associated with severe respiratory failure and multiorgan dysfunction, is reported. Histopathology was confirmed on open lung biopsy.

**A**dult onset Still's disease is an uncommon rheumatological syndrome, usually encountered in persons 16–35 years of age, with only one previous case reported in the elderly.<sup>1</sup> Pulmonary involvement is unusual and severe respiratory failure and biopsy confirmation rare.<sup>2–8</sup>

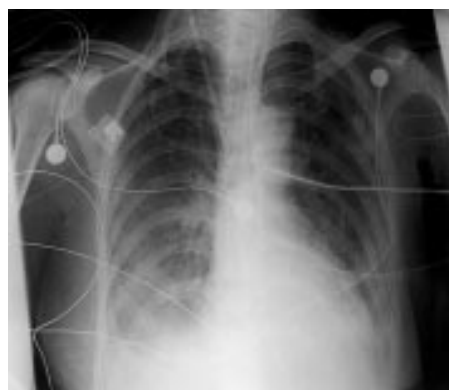### CASE REPORT

A 74 year old woman with mild controlled hypertension presented with two months' complaint of migratory, bilateral shoulder and knee arthralgias, myalgias, and intermittent high fevers. This followed an initial three day episode of sore throat treated unsuccessfully with several courses of antibiotics and non-steroidal anti-inflammatory drugs (NSAIDs). The persistent fever, rising leucocyte count, and anaemia prompted admission to hospital. On physical examination she was thin and in mild respiratory distress. Her temperature was 38.7°C, pulse 130 beats/min and regular, respiratory rate 20 breaths/min, and blood pressure 128/76 mm Hg. Heart and lung examinations were normal. Severe pain was elicited on palpation of shoulders and knees with a decreased range of movement. There was no evidence of a rash, change in skin turgor, active arthritis, or joint swelling. The rest of the examination was unremarkable.

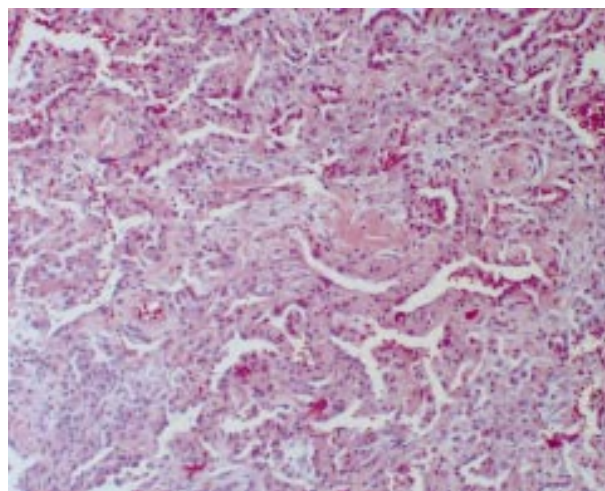
Laboratory findings included a leucocyte count of  $20 \times 10^9/L$ , with 86% neutrophils, and a haemoglobin concentration of 69 g/l (mean corpuscular volume 74 fl, serum ferritin 892 µg/l). Total iron binding capacity and haptoglobin were normal. Reticulocyte count was 2.2%, platelet count  $275 \times 10^9/L$ , and Coombs test was negative. Electrolytes and renal and liver function tests were all normal. The sedimentation rate was 85 mm/hour with antinuclear antibody, rheumatoid factor, antineutrophil cytoplasmic antibody, and anti-dsDNA all negative. Serum protein electrophoresis, complement C3 and C4, urine analysis, blood cultures, and the electrocardiogram were all normal. The chest radiograph revealed no infiltrates with borderline cardiomegaly.

Initial treatment included empiric vancomycin, gentamycin, and ciprofloxacin for presumed infection (penicillin allergy) pending cultures. Her purified protein derivative was negative but she was anergic. A bone marrow biopsy was normal.

On the fourth evening she developed a temperature of 38.9°C and a transient maculopapular, pruritic, pink rash. Over the next few days she became progressively dyspnoeic with a room air arterial blood gas revealing a pH of 7.49, carbon dioxide pressure of 3.73 kPa, and oxygen pressure of 526.93 kPa. A repeat radiograph (fig 1) showed diffuse bilateral infiltrates and small pleural effusions. Computed tomography of



**Figure 1** Portable anteroposterior chest radiograph with bilateral interstitial infiltrates and effusions.



**Figure 2** Wedge resection of left lower lobe (hematoxylin and eosin stain, original  $\times 100$ ). There is evidence of extensive diffuse interstitial fibrosis, hyperplasia of type II pneumocytes, fibroblast proliferation, and thickened alveolar septa.

the chest demonstrated non-specific pulmonary fibrosis. Transbronchial biopsies via fiberoptic bronchoscopy revealed acute inflammation without granulomatous disease and all cultures were negative. Ceftazidime and tobramycin were substituted in response to continuing fevers and leucocytosis. A thoracentesis revealed an exudate with negative Gram stain, cultures, and cytology. Her respiratory distress worsened and she required intubation and mechanical ventilation. A

**Abbreviations:** NSAIDs, non-steroidal anti-inflammatory drugs

diagnosis of adult Still's disease was entertained, antibiotics discontinued, and a course of intravenous pulse steroids (1 g of methylprednisolone per day for three days) started, followed by a corticosteroid taper. The absence of significant clinical improvement prompted a five day course of intravenous gammaglobulin and open lung left lower lobe wedge biopsy. Histology (fig 2) revealed extensive diffuse interstitial fibrosis with organising pneumonitis but no evidence of infection. She improved clinically, became afebrile, and was successfully extubated. Within a week, on corticosteroids, her respiratory status deteriorated. She was reintubated, developed an autoimmune and alloimmune thrombocytopenia with a severe bleeding diathesis, and died within two weeks.

## DISCUSSION

Adult onset Still's disease is identical to that described in children with systemic juvenile rheumatoid arthritis. In children systemic manifestations are usually self limited and rarely life threatening. The aetiology is unknown and it may complicate viral or other infection, with inconclusive linkage to HLA antigens and stress.<sup>2 9</sup>

There are no specific laboratory tests and pathognomonic rash, described by Still, is transient and easily missed. The differential diagnosis includes vasculitides (for example, polyarteritis nodosa, Wegener's granulomatosis), connective tissue diseases (for example, systemic lupus erythematosus), malignancies (for example, leukaemia, lymphoma, angiohistiocytosis), infections (for example, viral, tuberculosis, Lyme disease, syphilis), as well as granulomatous disorders (for example, sarcoidosis).

The diagnosis is one of exclusion and is based on clinical signs, symptoms, and laboratory findings. The diagnosis is established by three major and two minor criteria.<sup>10</sup> The major criteria are: 1, fever greater than 39°C, with a spiking pattern once daily; 2, arthralgia or arthritis; 3, negative antinuclear antibodies and rheumatoid factor. The minor criteria are: 1, leucocyte count greater than  $15 \times 10^9/l$ ; 2, Still's pathognomonic rash (85% of patients) which is maculopapular, mildly pruritic, salmon pink, and found on the trunk and proximal extremities and precipitated by mechanical irritation (Koebner's phenomenon); 3, pleuritis or pericarditis; 4, hepatomegaly, splenomegaly or generalised lymphadenopathy. Our patient met all three of the major criteria and three of four minor criteria.

Adult Still's disease generally has a favourable prognosis, however, studies have shown a slightly increased incidence of premature death.<sup>9</sup> Causes of death include hepatic failure, disseminated intravascular coagulation, amyloidosis, and sepsis.<sup>9</sup> Pulmonary manifestations include pleuritis, transient radiological infiltrations, interstitial lung disease, and rare respiratory failure requiring mechanical ventilation.<sup>2</sup> Pulmonary manifestations have, in general, a good prognosis but there are no published data on mortality or prognosis.<sup>2</sup>

Two of the only three reports of histopathological lung involvement in adult onset Still's disease were based on transbronchial biopsy and one at necropsy.<sup>3 7 8</sup> Ours is the only reported open lung biopsy. Findings include non-specific fibrosis, thickened alveolar walls, hyperplasia of type II pneumocytes, hyaline membrane formation, and lymphocytic infiltration. In our case a large wedge resection ( $8 \times 2.8 \times 0.9$  cm) revealed uniform features throughout (fig 2). There was extensive diffuse interstitial fibrosis with some hyperplasia of type II pneumocytes. Additionally, focal infiltration with neutrophils and foamy histiocytes was evident within the alveolar lumina. There was no evidence of vasculitis or granulomatous inflammation.

The disease can have an acute or chronic form. The acute form usually responds to NSAIDs alone in about 25% of patients.<sup>9</sup> Patients who fail to respond to NSAIDs, those with severe disease, coagulopathy, or increased liver function tests require systemic corticosteroids, usually in the form of prednisone 0.5–1 mg/kg/day. Pulse corticosteroids (for example, methylprednisolone), intravenous gammaglobulin, immunosuppressive, and/or cytotoxic agents appear indicated in life threatening acute disease.<sup>2</sup>

## Authors' affiliations

**G S Stoica, R I Cohen, L J Rossoff**, Long Island Jewish Medical Center, Long Island Campus of the Albert Einstein College of Medicine, New York, USA

Correspondence and reprint requests to: Dr Leonard J Rossoff, Division of Pulmonary and Critical Care Medicine, Long Island Jewish Medical Center, Long Island Campus of the Albert Einstein College of Medicine, Room C-20, 270-05 76th Avenue, New Hyde Park, NY 11042, USA; lrossoff@lij.edu

Submitted 22 June 2001

Accepted 24 July 2001

## REFERENCES

- 1 **Uson J**, Pena JM, Del Arco A, *et al*. JJ. Still's disease in a 72-year-old man. *J Rheumatol* 1993;**20**:1608–9.
- 2 **Cheema GS**, Quismorio FP Jr. Pulmonary involvement in adult-onset Still's disease. *Curr Opin Pulm Med* 1999;**5**:305–9.
- 3 **Hirohata S**, Kamoshita H, Taketani T, *et al*. Adult Still's disease complicated with adult respiratory distress. *Arch Intern Med* 1986;**146**:2409–10.
- 4 **Jottrand M**, Lienart F, Decaux G. Manifestations inhabituelles de la maladie du Still de l'adulte. A propos de deux observations. *Rev Med Brux* 1985;**6**:699–704.
- 5 **Paccalin M**, Chapon C, Roblot P, *et al*. Severe pulmonary manifestations in adult-onset Still's disease. *Rev Med Interne* 1997;**18**:575–7.
- 6 **Ohta A**, Yamaguchi M, Kaneoka H, *et al*. Adult Still's disease: review of 228 cases from the literature. *J Rheumatol* 1987;**14**:1139–1146.
- 7 **Shimamoto H**, Imaizumi K, Mizoguchi K, *et al*. A case of adult Still's disease with severe pulmonary complications. *Nihon Kokyuki Gakkai Zasshi* 1989;**27**:1092–9.
- 8 **Suyama T**, Yokoyama K. Interstitial pneumonitis detected by bronchoalveolar lavage and transbronchial lung biopsy in adult-onset Still's disease. *Nihon Kokyuki Gakkai Zasshi* 1998;**36**:545–50.
- 9 **Esdaile JM**. Adult Still's disease. In: Klippel JH, ed. *Primer on rheumatic diseases*. 11th Ed. Atlanta: Arthritis Foundation, 1997.
- 10 **Masson C**, Le Loet X, Liote F, *et al*. Comparative study of six types of criteria in adult Still's disease. *J Rheumatol* 1996;**23**:495–7.