

## SELF ASSESSMENT QUESTIONS

## A case of venous thrombosis

D Yeomanson, V Nagareddy, M Auger, A Hastings, M Vassallo

*Answers on p 606.*

An 81 year old man presented with an asymptomatic swelling of his left upper limb. The patient's past medical history included angina, hypertension, and a stroke (five years previously) which left him with mild dysphasia, but no other deficit. There was no past medical or family history of thrombosis.

There was a two day history of swelling. The arm was not painful, hot or red, and there was no history of trauma. Apart from pain in the left side of his neck, which had been present for three weeks, the patient was well. System

review revealed nothing apart from mild expressive dysphasia.

Examination revealed a non-tender arm, swollen to the elbow. Pulses were present and the skin was normal. No abnormalities were detected on examination of the axilla. A firm immobile lymph node was palpable in the anterior triangle of the neck. Prominent vessels were noted on the anterior chest wall. Examination was otherwise unremarkable. The patient was afebrile with a blood pressure of 136/55 mm Hg.

Initial investigations revealed a haemoglobin concentration of 147 g/l, a white cell count of  $8.8 \times 10^9/l$ , with an erythrocyte sedimentation rate of 18 mm/hour. His international normalised ratio was 0.9. Chest radiography showed left basal shadowing, and a widened mediastinum. Further investigations included venography (fig 1), computed tomography of the thorax (fig 2) and, on the basis of this, high resolution abdominal computed tomography (fig 3).

**Questions**

- (1) What abnormalities are shown on this venogram (fig 1)?
- (2) Figure 2 is from the thoracic computed tomography performed with contrast via the right arm. What abnormalities can be seen on this view?
- (3) Look at fig 3. What is the diagnosis?

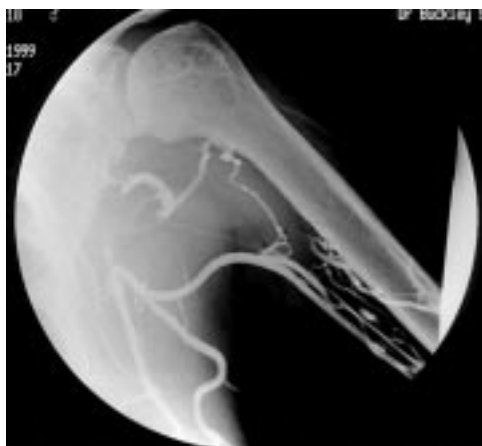

Figure 1 Venogram.

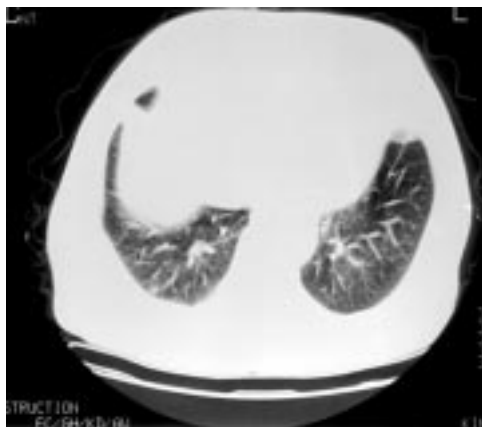

Figure 2 Computed tomogram of the thorax.

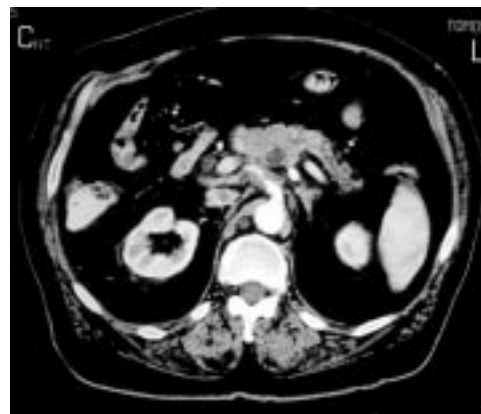

Figure 3 High resolution abdominal computed tomogram.

King's Mill Centre,  
Mansfield Road,  
Sutton-in-Ashfield,  
Notts NG17 4JL, UK  
D Yeomanson  
V Nagareddy  
M Auger  
A Hastings  
M Vassallo

Correspondence to:  
Dr Vassallo  
michael.vassallo@  
kmc-tr.nhs.uk

Submitted 18 April 2000  
Accepted 5 June 2000

## An elderly woman with chronic knee pain and abnormal chest radiography

Answers on p 606.

A A Karcic, V Maudar, E Karcic

Department of  
Medicine, Nassau  
County Medical  
Center, New York,  
USA

A A Karcic  
V Maudar  
E Karcic

Correspondence to:  
Dr A A Karcic, Department  
of Cardiology, Nassau  
County Medical Center,  
2201 Hempstead Turnpike,  
East Meadow, New York  
11554, USA

Submitted 10 May 2000  
Accepted 23 June 2000

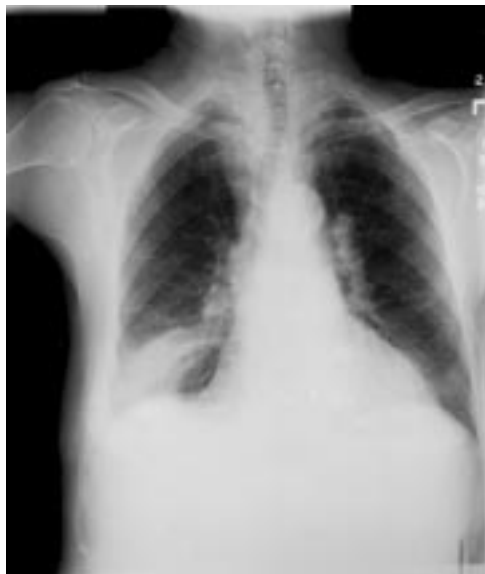

Figure 1 Chest radiograph showing old right lower lung and hilar infiltrates, unchanged from four years before.

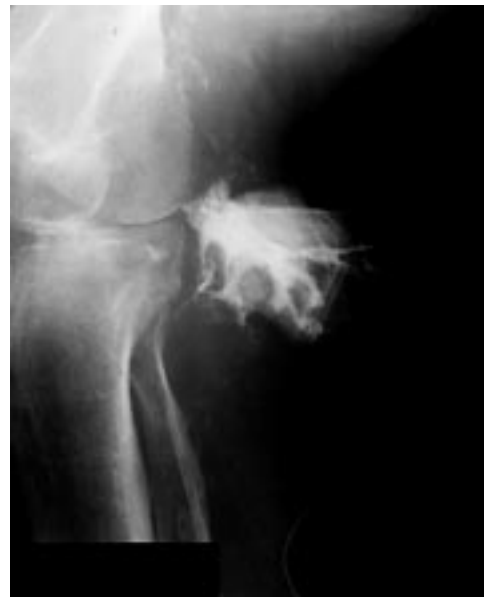

Figure 3 Sinogram (with contrast) of the right popliteal fossa sinus.

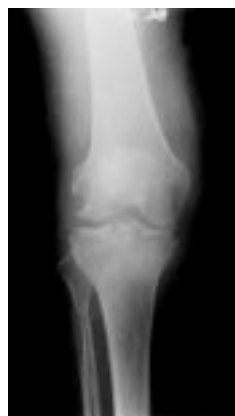

Figure 2 Right knee radiograph.

An 83 year old Portuguese woman presented to the hospital with worsening chronic right knee pain, dull in nature, worse after a recent fall and with weight bearing. She had a history of hypothyroidism and chronic atrial fibrillation. Her medications included levothyroxine, digoxin, and warfarin. The patient had been an immigrant to the United States 10 years previously and had not visited home since then.

The physical examination revealed a flexed and swollen right knee with a moderate effusion but no surrounding oedema. A small skin opening draining serosanguineous fluid was noticed in the popliteal fossa. The laboratory findings included a raised erythrocyte sedimentation rate of 86 mm/hour and C reactive protein of 10.3 µg/ml. Other laboratory tests were unremarkable. The patient's chest radiograph (fig 1) was unchanged from an old

x ray done four years before, and it shows old right lower lung and hilar shadows.

Aspiration of the knee, besides revealing large amounts of red blood cells, was essentially unremarkable. The plain knee radiograph (fig 2) was abnormal. A popliteal sinogram was performed (fig 3) showing a sinus tract, opening into the popliteal fossa, but not quite communicating with the knee joint. Finally, the patient underwent arthroscopy with synovial biopsy that was diagnostic. Cultures of the biopsy tissue confirmed the diagnosis.

### Questions

- (1) What is the differential diagnosis?
- (2) What is the diagnosis?
- (3) What is the pathophysiology of these abnormalities?

# Stridor, malaise, and visual loss in a woman from Sierra Leone

S E Brice, M D Oldfield, R Barker

Answers on p 607.

A 20 year woman from Sierra Leone, presented with a three week history of pain and blurred vision in her left eye. She reported feeling unwell for one month with malaise, anorexia, weight loss, and night sweats. Her general practitioner had recently diagnosed asthma as she had been short of breath on exertion, and she had a dry cough. She was a non-smoker on no other medication.

On examination she was thin, alert, and apyrexial. She had no rash or lymphadenopathy. Her respiratory rate was 20 breaths/min, and her trachea was central. On auscultation she had inspiratory stridor, with a peak expiratory flow rate of 240 l/min, and oxygen saturations on air that fell from 94% to 78% on exertion. Cardiovascular and abdominal examinations were unremarkable except for a tattoo on her abdomen. Visual acuity was light-dark discrimination in the left and 6/6 in the right. Colour perception was maintained, and fundoscopy was normal. Other cranial nerves were normal. Peripheral nervous system examination revealed normal tone, power and reflexes, with flexor plantar responses. There was no sensory disturbance.

Investigations showed a haemoglobin concentration of 136 g/l, platelet count  $325 \times 10^9/l$ , and white cell count  $6.7 \times 10^9/l$  (neutrophils 5.2, lymphocytes 0.71). Urea and electrolytes, liver function tests, and arterial blood gases were within normal limits. Total protein was 88 g/l, albumin 41 g/l, and erythrocyte sedimentation rate of 72 mm/hour. Lumbar puncture showed an opening pressure of 13 cm, white cell count  $<5/mm$ , protein 164 mg/l, glucose 4.7 mmol/l (plasma glucose 9.3 mmol/l); no organisms were seen on Gram stain.

Chest radiography and magnetic resonance imaging (MRI) of the orbit are shown in figs 1 and 2.

## Questions

- (1) What do the chest radiograph and orbital MRI scan show? Give a differential diagnosis for the radiological findings.
- (2) What investigation would give the diagnosis?
- (3) What other serology would be helpful?

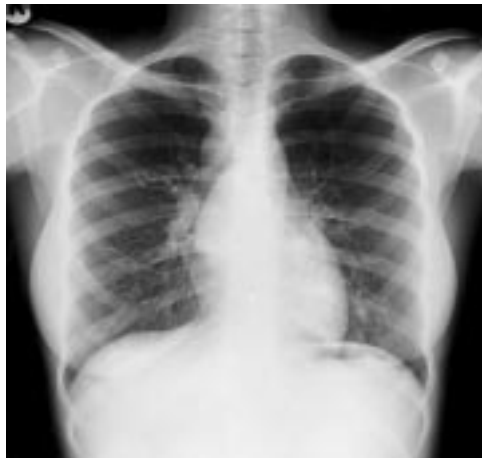

Figure 1 Chest radiograph.

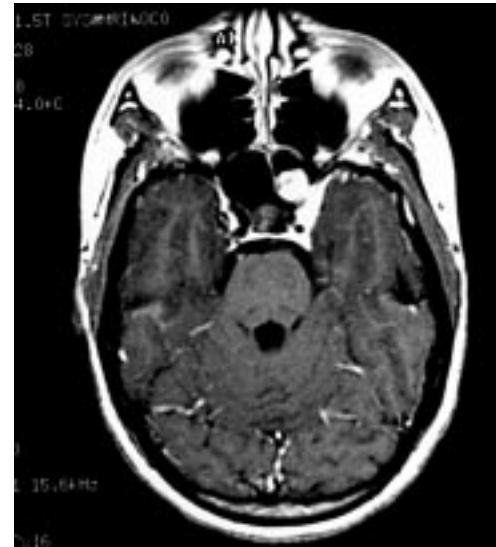

Figure 2 MRI scan.

**King's College  
Hospital, London, UK**  
S E Brice  
M D Oldfield  
R Barker

Correspondence to:  
Dr S E Brice, Department of  
Care of the Elderly, Hemel  
Hempstead General  
Hospital, Hillfield Road,  
Hemel Hempstead, Herts  
HP2 4AD, UK  
sarah.brice@talk21.com

Submitted 17 April 2000  
Accepted 19 July 2000

## Abdominal pain in an intrauterine contraceptive device user

Answers on p 608.

S Chitturi, J Hui, E Salisbury, D Mitchell, J George

University of Sydney at  
Westmead Hospital,  
Westmead, Australia:  
Storr Liver Unit

S Chitturi  
J Hui  
J George

Department of  
Anatomical Pathology  
E Salisbury

Department of  
Infectious Diseases  
D Mitchell

Correspondence to:  
Dr S Chitturi, Storr Liver  
Unit, Westmead Hospital,  
NSW 2145, Australia  
sumibob@hotmail.com

Submitted 21 February 2000  
Accepted 22 June 2000

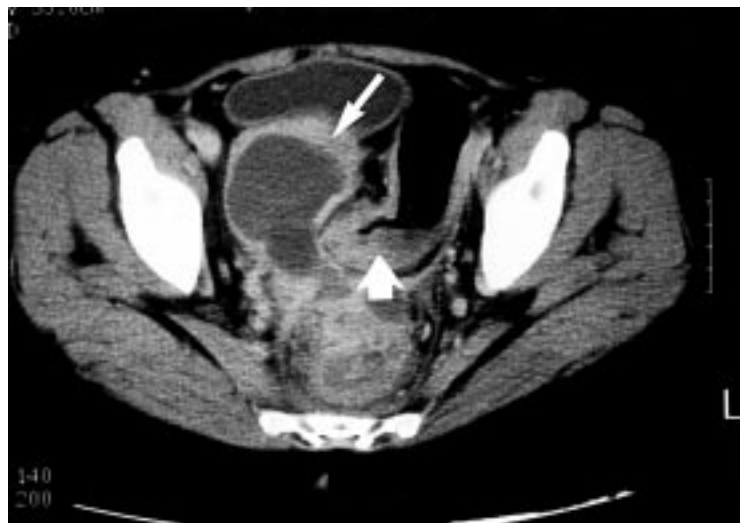

Figure 1 Abdominal computed tomogram.

A 41 year old shop assistant was admitted with a seven week history of colicky lower abdominal pain associated with alternating constipation and diarrhoea. In the preceding three weeks, she had experienced night sweats and had lost 5 kg in weight. The patient was not taking any regular medication apart from steroid inhalers for mild asthma. Her periods were regular with no abnormal vaginal bleeding. She had recently developed a creamy white vaginal discharge, which had not been evaluated. The last menstrual period was three weeks before admission but a recent pregnancy test was negative. The obstetric history was gravida 5, para 3. An intrauterine contraceptive device (IUCD) had been inserted five years before.

Examination revealed a thin, emaciated woman distressed by pain. She was afebrile and the vital signs were within normal limits. Mild suprapubic tenderness was noted on palpation. No organomegaly was discernable. Vaginal and

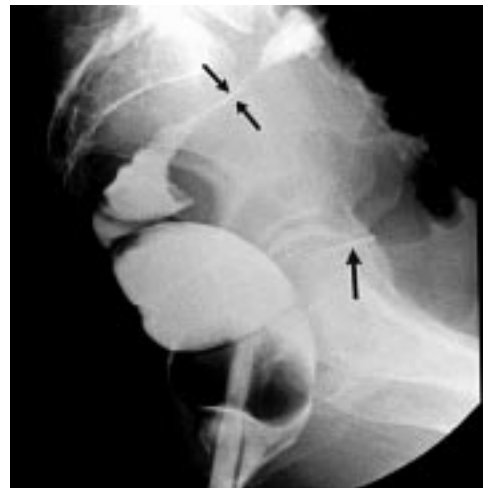

Figure 2 Barium enema.

rectal examination were normal. The laboratory findings were as follows: haemoglobin 111 g/l, white cell count  $8.8 \times 10^9/l$  (85% neutrophils), and platelet count  $547 \times 10^9/l$ . The biochemical profile was normal apart from mild hypokalaemia (potassium 3.1 mmol/l) and hypoalbuminaemia (albumin 31 g/l). Dipstick urine examination showed 3+ proteinuria and moderate leucocytes but several mid-stream urine cultures showed no growth. Vaginal smear examination revealed no abnormality. Multiple blood cultures were sterile. Plain abdominal radiography showed multiple fluid levels and dilated bowel loops suggestive of large bowel obstruction. Abdominal computed tomography (fig 1) and a barium enema examination (fig 2) were performed.

### Questions

- (1) What does the abdominal computed tomogram show?
- (2) What does the barium enema show?

## Abdominal pain after trauma in a young man

B L Samaga, M V Nagaraj

Answers on p 610.

A 27 year old man presented with vague abdominal pain two weeks after trauma to the abdomen by a cricket ball. The pain was felt in the right lower quadrant with an intermittent increase in severity. There were no systemic or other gastrointestinal symptoms. On physical examination there was a firm, non-tender mass

in the right lumbar region. The mass was not mobile, not ballotable. Abdominal sonography showed hypoechoic mass lesion on both sides of the spine, extending from the lumbar region up to the pelvis. His complete haemogram (haemoglobin, total leucocyte count, differential leucocyte count, platelet count), serum

glucose, renal and liver function tests, chest radiograph, and electrocardiogram were normal; his erythrocyte sedimentation rate was 60 mm/hour.

Computed tomography of the abdomen (figs 1 and 2) showed bilateral, rounded, hypodense, and fluid dense mass lesions (rim enhancing on contrast) within the psoas muscle sheath, extending from lumbar region up to the pelvis. Psoas muscles on both sides showed curvilinear compression. Similar fluid dense lesions were visualised in the gluteal muscles (fig 3). Liver, spleen, kidneys, pancreas, and para-aortic areas were normal.

### Questions

- (1) What is the differential diagnosis?
- (2) What other investigations would you consider?

Department of  
Clinical Medicine,  
Kasturba Medical  
College, Manipal,  
Karnataka, India  
B L Samaga  
M V Nagaraj

Correspondence to:  
Dr B L Samaga, KMC Qtrs  
135, Manipal Udipi,  
Karnataka, PIN 576119,  
India  
bl\_samaga@yahoo.com

Submitted 5 November  
1999  
Accepted 11 May 2000

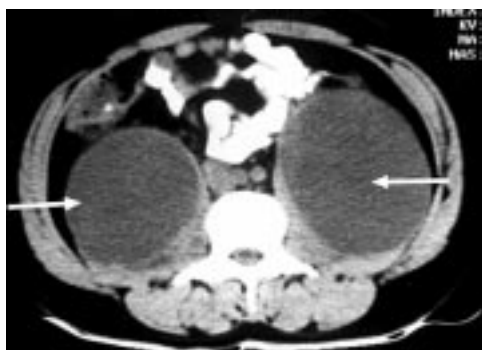

Figure 1 Computed tomography of the abdomen showing bilateral, rounded, hypodense lesions within the psoas sheath (arrows). Note curvilinear compression of psoas muscles on both sides.

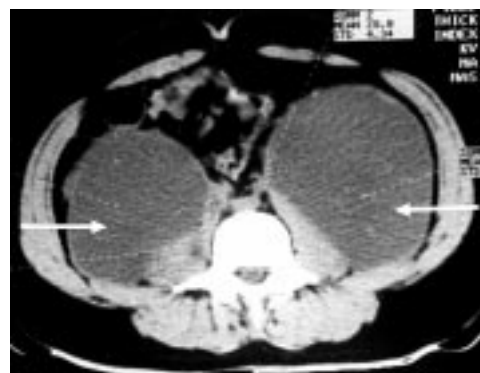

Figure 2 Computed tomography of the abdomen showing similar changes as in fig 1 but at a lower level.

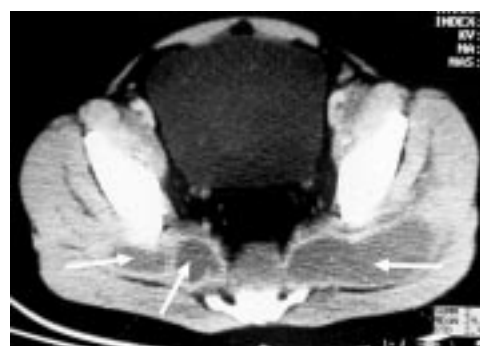

Figure 3 Computed tomography findings showing hypoattenuated fluid dense lesions within gluteal muscles (arrows).

## Transient ST segment changes mimicking early repolarisation phenomenon in a patient with angina at rest

A Altun, O Akdemir, E Tatli, G Özbay

Answers on p 611.

Cardiology  
Department, Trakya  
University, Faculty of  
Medicine, Edirne,  
Turkey  
A Altun  
O Akdemir  
E Tatli  
G Özbay

Correspondence to:  
Dr Armağan Altun, Esen 91  
Sitesi, B Blok D: 4, 22030  
Edirne, Turkey

Submitted 7 February 2000  
Accepted 4 July 2000

A 60 year old woman suffering from hypertension secondary to diabetic nephropathy was being followed up in a nephrology clinic. Her leg was amputated four years ago. At her fifth day of admission she had been seen by a cardiologist because of chest discomfort lasting 20 minutes and ST elevations on her electrocardiogram (ECG) (fig 1). Blood pressure was 150/80 mm Hg and heart rate 75 beats/min. A pansystolic murmur graded 3/6 was heard at the apex. Neither gallop sounds nor pulmonary rales were present. She was taken to the coronary care unit; aspirin, heparin, and nitrate were started.

Laboratory analyses, performed at follow up in the nephrology clinic, were as follows: haemoglobin 94 g/l, packed cell volume 0.29, urea 43.2 mmol/l, creatinine 406.6 µmol/l, sodium 126 mmol/l, potassium 3.5 mmol/l,

creatinine MB fraction 12 U/l. The latter was in normal limits during the first 24 hours. The ECG before her complaint showed coarse atrial fibrillation without ST change. The ECG findings persisted 72 hours despite recovery of the symptom in 20 minutes and the one recorded at fourth day was completely identical with the baseline. Tc-99m pyrophosphate myocardial scintigraphy performed 48 hours after the event showed no necrosis.

### Questions

- (1) Describe the ECG.
- (2) List the electrocardiographic characteristics of early repolarisation.
- (3) Compare the electrocardiographic features of early repolarisation, pericarditis, and myocardial infarction.

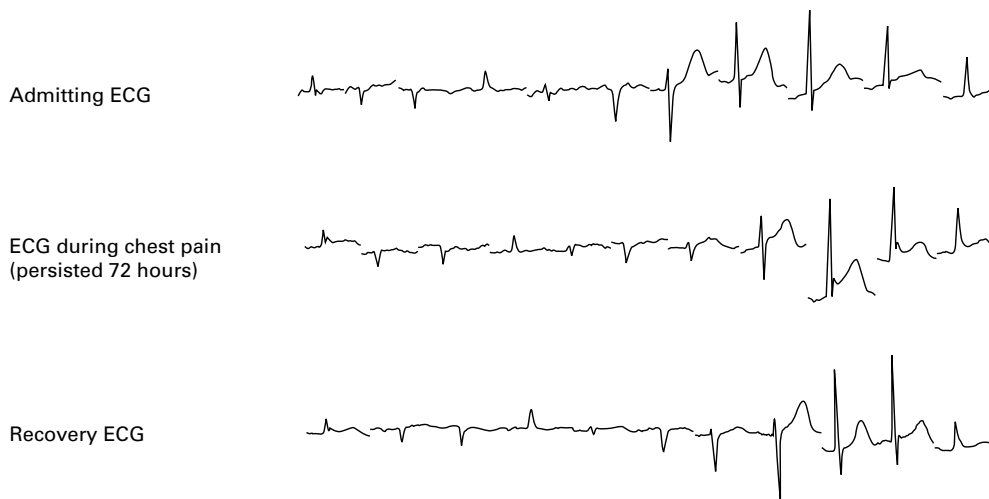


Figure 1 Serial ECGs of the patient.

## Two diagnoses from one electrocardiogram

Answers on p 612.

I Beeton, E Leatham

Cardiology  
Department, Royal  
Surrey County  
Hospital, Egerton  
Road, Guildford,  
Surrey, GU2 5XX, UK  
I Beeton  
E Leatham

Correspondence to:  
Dr Beeton

Submitted 20 March 2000  
Accepted 18 May 2000

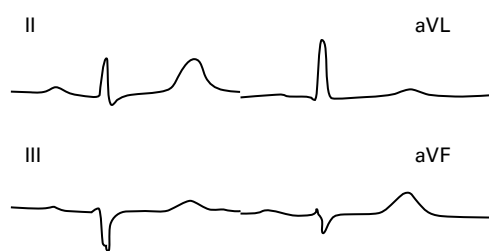


Figure 1 Inferior leads of an ECG 18 months before current admission.

A 76 year old women presented to casualty with a three hour history of central chest pain radiating to the back and left arm. She was dyspnoeic at rest and four doses of sublingual glycerine trinitrate (GTN) had provided only partial relief. Past medical history included stable angina for a year and deep vein thrombosis.

Medication on admission was aspirin, GTN, and isosorbide mononitrate. Cardiorespiratory, abdominal, and neurological examination was normal. Blood pressure was 187/88 mm Hg with a heart rate of 61 beats/min. Full blood count, creatine kinase, and electrolytes were within normal limits. Random cholesterol was 6.8 mmol/l and urea (10.9 mmol/l) and creatinine (141  $\mu$ mol/l) were raised. An electrocardiogram (ECG) from a previous clinic visit (fig 1) and the admission ECG (fig 2) are shown.

### Questions

- (1) What is the diagnosis?
- (2) What complication of treatment is suggested by the ECG (fig 3) taken the next morning?
- (3) How should this be managed?

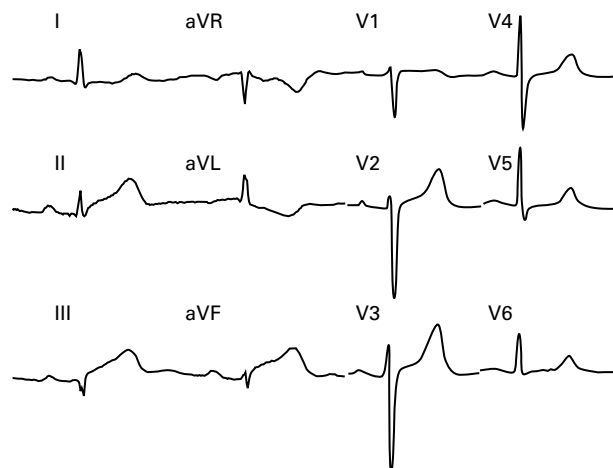


Figure 2 Twelve lead ECG taken during chest pain on admission.

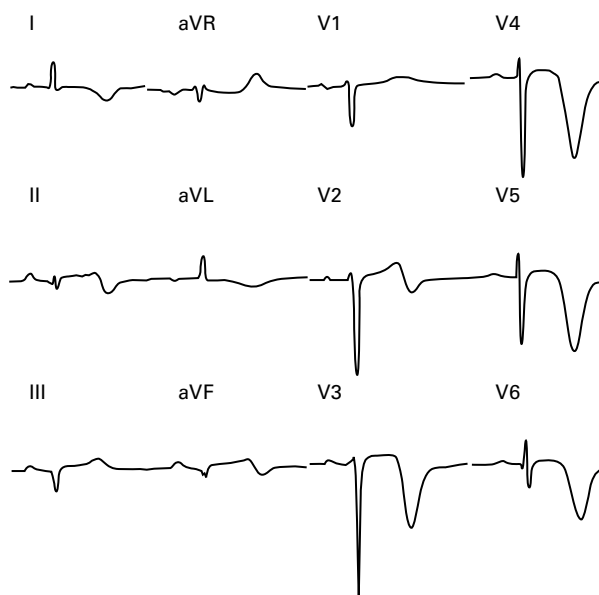


Figure 3 Twelve lead ECG taken 18 hours after admission. The patient was not in pain when this ECG was recorded.

## An unusual intra-abdominal tumour

M H Shiwani, D J Breen, T Giles, K R Wedgwood

Answers on p 613.

**Castle Hill Hospital,  
Hull, UK: Department  
of Surgery**  
M H Shiwani  
K R Wedgwood

**Department of  
Radiology**  
D J Breen

**Department of  
Pathology**  
T Giles

Correspondence to:  
Mr K R Wedgwood,  
Department of Surgery,  
Castle Hill Hospital,  
Cottingham, Hull  
HU16 5JQ, UK  
kevwed@aol.com

Submitted 27 March 2000  
Accepted 5 June 2000

A 72 year old men presented with a five week history of intermittent upper abdominal pain radiating to the flanks, lasting for several hours, aggravated by walking and movement and with one episode of vomiting. There were no other associated gastrointestinal symptoms. General examination was unremarkable. Abdominal examination revealed a large, smooth, and non-tender mass in the upper abdomen, which moved with respiration. Baseline haematology and biochemistry were normal. Ultrasound scan of the abdomen suggested a soft tissue mass, arising from either stomach or pancreas. Upper gastrointestinal endoscopy did not show any abnormality in the stomach or duodenum. A contrast enhanced computed tomogram is shown in fig 1. Distal partial gastrectomy was performed with en bloc resection of omentum and gastrojejunostomy fashioned. The gross pathological specimen is shown in fig 2 and microscopy in figs 3 and 4. The patient made an uneventful postoperative recovery.

### Questions

- (1) Comment on the computed tomogram.
- (2) Describe the macroscopic appearance of the specimen.
- (3) Describe the histological features.

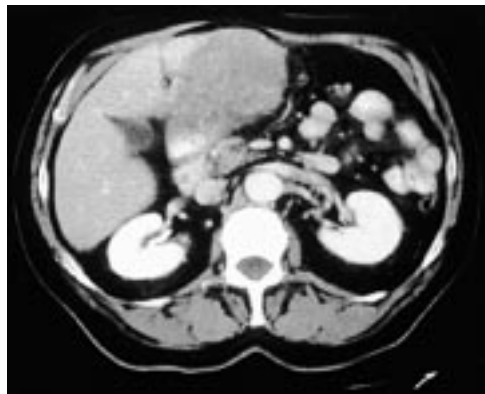

Figure 1 Computed tomogram.

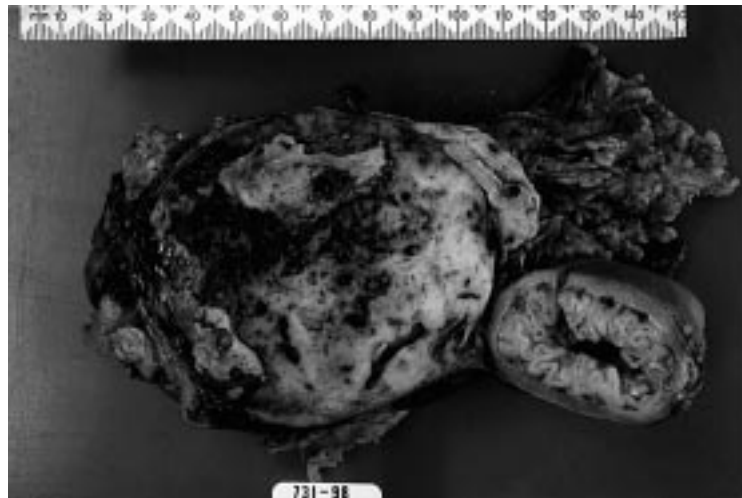

Figure 2 Gross pathology specimen.

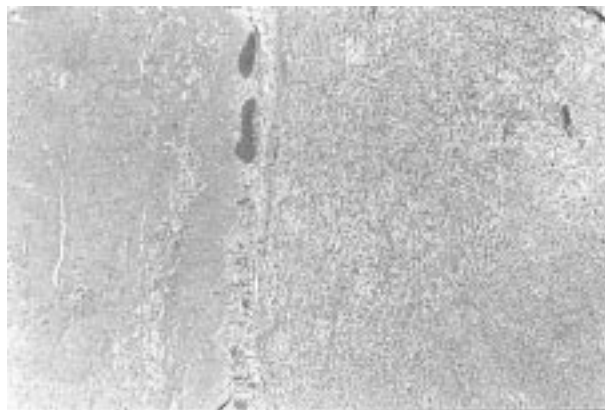


Figure 3 Microscopy.

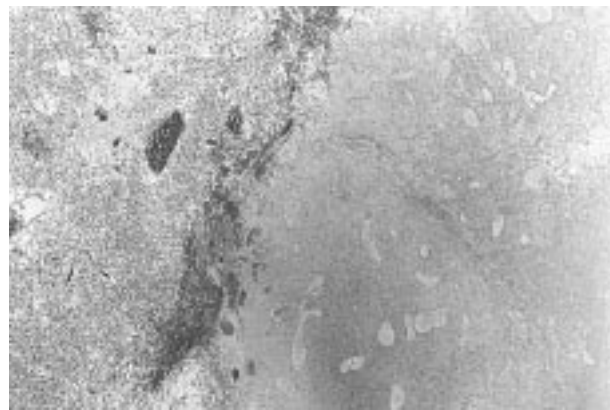

Figure 4 Microscopy.

## SELF ASSESSMENT ANSWERS

### A case of venous thrombosis

#### Q1: What abnormalities are shown on this venogram (fig 1)?

Figure 1 (see p 599) shows occlusion of the cephalic vein, with no filling of the left axillary or subclavian veins. There is extensive collateral formation. Although no thrombus is demonstrated, it was thought that this was likely to exist more centrally.

#### Q2: Figure 2 is from the thoracic computed tomography performed with contrast via the right arm. What abnormalities can be seen on this view?

Figure 2 (see p 599) shows that the superior vena cava is patent, and that there was no abnormality or mass in the mediastinum. There are multiple chest wall and axillary collaterals on both sides, suggesting bilateral axillary vein occlusion.

#### Q3: Look at fig 3. What is the diagnosis?

Figure 3 (see p 599) shows an ill defined mass in the body of the pancreas, extending around the coeliac axis. The most likely diagnosis is pancreatic cancer. This was later confirmed at postmortem examination.

### Discussion

Patients with cancer often have a hypercoagulable state. The association between venous thromboembolism and malignancy is well known, a fact which is recognised on deep vein thrombosis risk assessment schemes.<sup>1</sup>

The mechanism by which thrombotic tendency is increased is complex. It is thought that tumour cells directly express procoagulants, while the host response to certain tumour cells includes the expression of similar substances, such as tissue factor (from monocytes).<sup>2</sup>

Host factors, such as age, immobility, sepsis, and drug therapy also effect clotting tendency, while tumour mass or lymphadenopathy can directly compress vessels.<sup>2</sup>

Patients with malignancy may present with a variety of clotting disorders including migratory superficial thrombophlebitis (Trousseau's syndrome), disseminated intravascular coagulation or, as in this case, with venous thrombosis.

A Swedish study in 1994 found that the incidence of cancer diagnosed within six months of venogram for suspected deep vein thrombosis was increased from 1.4% (negative) to 4.8% (positive venogram). Six months after venography the chances of being diagnosed with cancer were not significantly different between the two groups.<sup>3</sup>

Pancreatic cancer is especially strongly associated with thrombosis; it is historically linked to Trousseau's syndrome and a number of studies looking for occult malignancy in patients with idiopathic deep vein thrombosis place pancreatic cancer among the most frequently found. One study found evidence of

thrombosis in 30% of patients who died from pancreatic cancer, the incidence rising to over 50% in those with tumour in the body or tail of the pancreas.<sup>3,4</sup> However, clearly not all patients with venous thromboembolic disease have cancer, and doubt exists about the prognostic significance of an idiopathic venous thrombosis, as well as over the extent to which an occult malignancy should be pursued.

Studies place the percentage of cancers detectable after thorough history taking and examination on presentation with deep vein thrombosis between 50% and 75% of all cancers detected within six months to one year after positive venography. Analysis of cancers detected during a subsequent admission within six months of positive venography suggests that earlier diagnosis (for example, at the time of venography), and therefore more intensive investigation, would only benefit a small number of patients.<sup>3,5,6</sup>

This is because a number of the tumours were asymptomatic, and were detected at necropsy in patients who died from co-morbid conditions, and because the more strongly associated cancers, such as pancreas and liver, are generally incurable, earlier diagnosis only increasing lead time.<sup>3,5,6</sup>

This case is particularly unusual in that the axillary vein thromboses were bilateral, and had been present subclinically for some time, as evidenced by the extensive collateral formation.

There remains debate in the literature about whether certain types of thromboses have more prognostic significance than others. It may be that patients with recurrent thromboses during anticoagulation, or unusual thromboses such as the ones we have described, warrant a more aggressive search for a possible malignancy.

### Final diagnosis

Bilateral axillary vein thrombosis associated with pancreatic cancer.

- 1 Thromboembolic Risk Factors (THRIFT) Consensus Group. Risk and prophylaxis for venous thromboembolism in hospital patients. *BMJ* 1992;305:568.
- 2 Levine M. Treatment of thrombotic disorders in cancer patients. *Haemostasis* 1997;27(suppl 1):38-43.
- 3 Nordström M, Lindblad B, Anderson H, et al. Deep venous thrombosis and occult malignancy: an epidemiological study. *BMJ* 1994;308:891-4.
- 4 Sproul E. Carcinoma and venous thrombosis: the frequency of association of carcinoma in the body or tail of the pancreas with multiple venous thrombosis. *Am J Cancer* 1938;34:566.
- 5 Hettiarachchi R, Lok J, Prins M, et al. Undiagnosed malignancy in patients with deep vein thrombosis. *Cancer* 1998;83:180-5.
- 6 Sorenson HT, Mellekjaer L, Steffensen FH, et al. The risk of a diagnosis of cancer after primary deep vein thrombosis or pulmonary embolism. *N Engl J Med* 1998;338:1169-73.

### An elderly woman with chronic knee pain and abnormal chest radiography

#### Q1: What is the differential diagnosis?

A history of recent fall in a patient on anticoagulation therapy, particularly when linked with a bloody knee joint aspirate, should



prompt the suspicion of traumatic haemarthrosis. Against this diagnosis goes the chronicity of symptoms preceding the injury, the x ray findings, the fistula, etc. Blood during aspiration might merely be the consequence of a traumatic tap.

The other likely diagnosis is tuberculous monoarthritis, suggested with the abnormal knee and chest radiographs, draining popliteal fossa sinus, and fact that the diagnosis was established with synovial tissue biopsy and culture. Additionally, the patient had emigrated from an area endemic for tuberculosis.

### Q2: What is the diagnosis?

The patient had tuberculous arthritis. The synovial biopsy showed multiple granulomas and multinucleated giant cells. Rare acid fast bacilli were seen as well. Synovial tissue cultures subsequently grew mycobacterium tuberculosis.

### Q3: What is the pathophysiology of these abnormalities?

Tuberculous monoarthritis, once common, is now rare because of the availability of antitubercular treatment. Articular involvement is seen in less than 1% of tuberculous infections. If untreated it may lead to complete joint destruction.

Only a minority of patients will have concurrent active tuberculosis that might be pulmonary or extrapulmonary. Other patients will usually have evidence suggesting previous exposure to tuberculosis (for example, see the chest radiograph, fig 1, on p 600). The vast majority will typically have a tuberculin positive skin test, but not all. In one report, up to 40% of patients with tubercular monoarthritis had a negative skin test.<sup>1</sup>

Articular tuberculosis, like other forms of extrapulmonary tuberculosis, is usually due to reactivation of a haematogenously seeded focus and need not be associated with active tuberculosis elsewhere.<sup>2</sup>

The most frequently affected joints are the knee, followed by the hip, wrist, and other small joints.<sup>3</sup> Weight bearing joints are more frequently affected. It is possible that daily microtrauma of weight bearing predisposes these joints to infection.<sup>4</sup>

After local trauma experimental animals were predisposed to tuberculous joint infection. Tuberculous monoarthritis presents insidiously with joint pain and joint swelling. Sinuses and fistulas are not a rare finding in tuberculous arthritis.<sup>5</sup>

Figure 1 (see p 600) shows the characteristic radiographic appearance of tuberculous arthritis. Changes seen classically include joint space narrowing, metaphyseal and subchondral erosions (all seen on fig 1), and subchondral cysts. The pattern of vascular anatomy predisposes to this typical radiographic appearance. Metaphyseal capillaries loop sharply in the area of the metaphyseal plate. They anastomose extensively and become dilated, causing turbulence and slowing of blood flow. This in turn predisposes to bacterial localisation and growth.

### Learning points: tuberculous monoarthritis

- Seen in 1% of tuberculous infections.
- Seen in active or dormant tuberculosis.
- Patients have evidence of exposure to tuberculosis like a positive skin test (typically but not always) or suggestive chest radiography findings.
- Weight bearing joints preferably affected: knee > hip > wrist > other small joints.
- Typical findings on the knee radiograph: joint space narrowing, metaphyseal and subchondral erosions, and subchondral cysts.
- Gold standard of diagnosis: synovial tissue biopsy and tissue cultures
- Treatment is similar to other forms of tuberculosis.

The gold standard for diagnosing tuberculous arthritis remains synovial biopsy and tissue cultures. The chemotherapy for articular tuberculosis is the same as for other forms of tuberculosis.

In summary, tuberculous arthritis should be suspected typically in tuberculin skin test positive patients with chronic monoarticular pain and abnormal chest and joint radiographs. Excisional synovial biopsy and tissue culture give the best diagnostic yield. Treatment is the same as for other forms of tuberculosis.

### Final diagnosis

Tuberculous monoarthritis of the knee joint.

1 Negesse W. Bone and joint tuberculosis in childhood in a children's hospital, Addis Ababa. *Ethiop Med J* 1993;31:51-61.

2 Singh MM, Bhargava AN, Kranti PJ. Tuberculous peritonitis. An evaluation of pathogenic mechanisms, diagnostic procedures, and therapeutic measures. *N Engl J Med* 1969; 281:1091.

3 Berney S, Goldstein M, Bishko F. Clinical and diagnostic features of tuberculous arthritis. *Am J Med* 1972;53:36-42.

4 Blacklock JWS, Williams JRB. The localization of tuberculous infection at the site of injury. *Journal of Pathology and Bacteriology* 1957;74:1119-28.

5 Zielinski CC, Savoini E, Ciotti M, et al. Dialyzable leukocyte extract (transfer factor) in the treatment of superinfected fistulating tuberculosis of the bone. *Cell Immunol* 1984;84: 200-5.

### Stridor, malaise, and visual loss in a woman from Sierra Leone

#### Q1: What do the chest radiograph and orbital MRI scan show? Give a differential diagnosis for the radiological findings

The chest radiograph (see p 601) shows paratracheal lymphadenopathy, and the orbital MRI scan (see p 601) shows a mass around the left optic nerve. The differential diagnosis of these radiological findings would include sarcoid, tuberculosis, other infections such as brucella, toxoplasmosis and fungi, and also lymphoma and other malignancies.

### Q2: What investigation would give the diagnosis?

Bronchoscopy. The likely diagnosis in this woman of African origin with systemic symptoms, mediastinal lymphadenopathy, and masses elsewhere is tuberculosis. Bronchoscopy is particularly appropriate in the presence of stridor and also because most patients with suspected tuberculosis who have only mediastinal lymphadenopathy and no lung shadowing are smear negative on sputum samples.

In this case, bronchoscopy revealed copious white (caseous) material infiltrating the right main bronchus, presumably from an adjacent lymph node. In older subjects it can be difficult to distinguish macroscopically between tuberculosis and carcinoma. Histology in this patient demonstrated caseating granulomata with acid fast bacilli. Culture confirmed that the organism was *Mycobacterium tuberculosis*, fully sensitive to all first line drugs. Mediastinoscopy or trans-sphenoidal biopsy of the lesion on the optic nerve would be further options for diagnosis.

### Q3: What other serology would be helpful?

HIV serology. In the young African population HIV infection is an increasingly common cause of malaise, weight loss, fever, and isolated mediastinal lymphadenopathy. Once tuberculosis has been confirmed the issue of HIV seropositivity must be considered, with the increasing rates of co-infection in the African population.<sup>1,2</sup> It has implications not only for future therapy, but also raises questions about the nature of the optic nerve lesion. In the immunocompetent host the mass could confidently be labelled a tuberculoma. However, in the compromised patient other conditions such as fungal infections, syphilitic gummas, toxoplasmosis, lymphoma, and other malignancies are possibilities and definite histology would be needed for accurate diagnosis.

Our patient had multiple risk factors for HIV infection, but was antibody negative. For this reason and also because the optic nerve mass lay close to the carotid artery, the lesion was not biopsied. It was assumed to represent a tuberculoma, and its size monitored during treatment on serial MRI scans.

### Outcome

The patient was initially treated with standard antituberculous therapy except for streptomycin instead of ethambutol to avoid visual complications. Once the mycobacterium was found to be fully sensitive, the streptomycin was stopped. Although vision in the affected eye failed to improve, the patient improved systemically and made a good recovery.

### Discussion

Involvement of the central nervous system occurs in about 10% of all patients with tuberculosis.<sup>3</sup> The most common form is meningitis, although encephalopathy, abscesses and tuberculomas also occur, the latter especially in patients with impaired cell mediated immunity.<sup>1</sup> On computed tomography tuberculomas

appear as ring enhancing lesions which may be difficult to differentiate from toxoplasmosis or neurocysticercosis, particularly in India where both tuberculosis and cysticercosis are endemic.<sup>4</sup> MRI can be helpful, although stereotactic biopsy may be necessary for accurate diagnosis. A further problem is that tuberculomas may enlarge or develop during treatment, often raising questions about diagnosis and requiring steroid therapy or even surgical management.<sup>5</sup>

The increasing incidence of tuberculosis worldwide is largely due to the rising prevalence of HIV infection.<sup>1</sup> Clinical presentation in the HIV positive patient depends on the degree of immunocompromise. Early on, tuberculosis resembles typical post-primary disease with predominant lung involvement. As the CD4 count falls, the presentation becomes more non-specific, with weight loss, fevers, malaise, and manifestations of extrapulmonary disease.<sup>2</sup> To further confound the diagnosis, these patients are frequently sputum smear negative, the chest radiograph may only show mediastinal lymphadenopathy, and the tuberculin skin test is negative.

Treatment of tuberculosis with HIV co-infection is with conventional antituberculous agents. Although the clinical response is good, survival is poor, especially with central nervous system involvement.

### Final diagnosis

Tuberculosis with optic nerve tuberculoma.

- 1 Harries AD. Association between HIV and tuberculosis in the developing world. In: Davies PDO, ed. *Clinical tuberculosis*. 2nd Ed. London: Chapman & Hall Medical, 1998: 315–45.
- 2 Barnes PF, Bloch AB, Davidson PT, et al. Tuberculosis in patients with human immunodeficiency virus. *N Engl J Med* 1991;324:1644–50.
- 3 Garg RK. Tuberculosis of the central nervous system. *Postgrad Med J* 1999;75:133–40.
- 4 Wadley J. Differential diagnosis of cerebral tuberculomas (letter). *J R Soc Med* 1997;90:469.
- 5 Teoh R, Humphries MJ, Mahony G. Symptomatic intracranial tuberculoma developing during treatment of tuberculosis: a report of 10 patients and review of the literature. *Q J Med* 1987;241:449–60.

### Abdominal pain in an intrauterine contraceptive device user

#### Q1: What does the abdominal computed tomogram show?

The abdominal computed tomogram (see p 602) shows large multiloculated collections in the pelvis with thickening (arrow) of surrounding tissues. Wall thickening of the upper sigmoid (arrow head) corresponds to the sigmoid stricture in the barium enema study.

#### Q2: What does the barium enema show?

The barium enema study (see p 602) shows a stricture (opposing arrows) in the lower sigmoid colon. The IUCD is also shown (single arrow).

### Clinical course

The patient was initially treated with intravenous fluids and nasogastric tube aspiration. She continued to experience bouts of severe

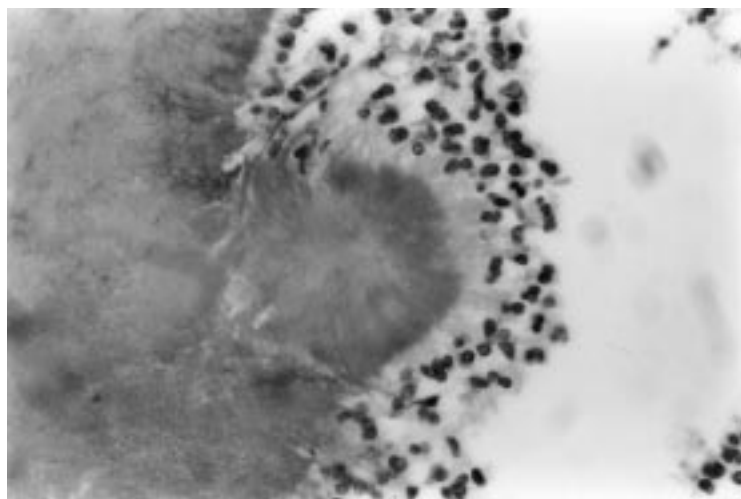


Figure 1 The edge of a typical "sulphur" granule showing filamentous actinomycetes embedded along the periphery of the matrix, surrounded by inflammatory cells (haematoxylin and eosin stain  $\times 500$ ).

lower abdominal pain and vomiting necessitating laparotomy (10 days after admission). At surgery, a large pelvic abscess was seen with dense adhesions between the pelvic viscera, appendix, and bowel loops. Appendectomy and hysterectomy with right salpingo-oophorectomy were performed along with a covering loop colostomy.

Histology of the uterus showed severe chronic endometritis with numerous branching Gram positive rods in the endometrial cavity and endocervix. Sections from the Fallopian tube showed numerous actinomycotic granules (fig 1 above). No evidence of malignancy was detected. The appendix and right ovary showed non-specific inflammation only. Although bacterial culture was not performed, the clinical and histological findings were consistent with pelvic actinomycosis. She was treated with intravenous benzylpenicillin 9.6 million units daily for four weeks and then intravenous ceftriaxone 2 g daily for two weeks as an outpatient. She is currently taking oral amoxicillin 1.5 g daily, which is to be continued for a year. She remains well at six months of follow up and the colostomy was closed recently.

### Discussion

Actinomycosis is a bacterial infection caused by members of the genus actinomycetes, a group of Gram positive, filamentous, and microaerophilic bacilli. *Actinomyces israelii* is most commonly associated with human disease. They occur as commensals in the oropharynx and gastrointestinal tract and do not usually breach mucosal barriers, unless there is disruption of tissue planes after surgery, trauma, or perforation. Presence of necrotic tissue or foreign bodies may also favour the development of actinomycosis.<sup>1</sup>

Three major clinical patterns are recognised: cervicofacial, thoracic, and abdominal. Florid granulation tissue, abscesses, cutaneous sinuses, and fistulae are common.<sup>1</sup> Diagnosis is established by biopsy, fine needle aspiration of abscess contents, or culture. Examination of

the purulent exudate shows characteristic "sulphur" granules, which are clusters of actinomycetes colonies embedded in an amorphous matrix (fig 1). The presence of "sulphur" granules is suggestive but not pathognomonic of actinomycosis. Other organisms may show similar appearances and only the Gram stain (showing Gram positive, branching, filamentous rods) can differentiate these from actinomycetes.<sup>2</sup> Definitive identification is obtained only by culture or species specific antibodies.

Abdominal actinomycosis usually occurs in the ileocaecal area and appendix (65% of cases).<sup>1</sup> It typically follows emergency gallbladder or colonic surgery. Clinical features include fever, weight loss, abdominal pain, abdominal mass, and signs of partial intestinal obstruction. Fistulae develop in about one third of abdominal actinomycotic abscesses. Abdominal actinomycosis is well recognised as a "great imitator" and is readily mistaken for neoplastic disease, Crohn's disease, or tuberculosis. Preoperative diagnosis is infrequent (<10%). Crohn's disease and ovarian malignancy were the preoperative diagnoses being considered in this patient.

Actinomycosis of the female genital tract is much less common (less than 1/100 000 women discharged from hospital).<sup>3</sup> The spectrum of pelvic actinomycosis includes endometritis, pelvic inflammatory disease, and pelvic abscess. Occasionally, the disease may be confined to the bowel, bladder, abdominal wall, or retroperitoneum. Rarely systemic (liver, brain, and lung) abscesses may develop.<sup>4,5</sup> Pelvic actinomycosis results from ascending perineal infection or through orogenital/anogenital contact.<sup>5</sup>

The presence of the IUCD is an important factor in the pathogenesis of pelvic actinomycosis. Occasionally, other foreign bodies (for example, vaginal pessaries) may be involved. Actinomycetes can be demonstrated by cervical smears or immunofluorescence in about 7% (range 0%–31%) of IUCD users. However, a higher rate of deep pelvic infection has not been clearly demonstrated in those with positive smears. The relationship between a positive cervical smear and subsequent pelvic actinomycosis is therefore uncertain and the utility of the cervical smear as a screening tool is controversial. However, a positive smear in an IUCD user with a pelvic abscess should at least prompt further evaluation.

Pelvic abscess associated with the modern IUCD was first reported in 1973. Most reported cases have occurred in long term IUCD or pessary users (average eight years).<sup>5</sup> Symptoms include abdominal pain (85%), weight loss (44%), and vaginal discharge (24%). Anaemia (70%), leucocytosis (76%), and a raised erythrocyte sedimentation rate are other features. Physical examination is unhelpful except in those with obvious pelvic masses or skin sinuses. Radiological appearances are not distinctive. Ultrasound and computed tomography studies may demonstrate a solid mass with areas of attenuation, a cystic mass

with wall thickening, or diffuse tissue thickening.<sup>1,6</sup> Fine needle aspiration performed at the same time may help in establishing the diagnosis.

Clinically stable patients are treated with a prolonged course of antibiotics. Surgery is reserved for bowel obstruction, abscess drainage, or antibiotic failure. High dose intravenous penicillin G is the treatment of choice and is given for four to six weeks, followed by a prolonged course (6–12 months) of oral penicillin. Alternatives to penicillin are ceftriaxone, tetracycline, erythromycin, and clindamycin. Superinfection with other organisms particularly *Actinobacillus actinomycetemittans* should be considered if there is poor progress after four weeks of treatment.

Removal of the IUCD and antibiotic treatment is recommended in the presence of pelvic inflammatory disease. Antibiotics are usually withheld when actinomyces are detected on a routine cervical smear or culture from an asymptomatic IUCD user. Further management in this situation varies from centre to centre. Most but not all authors advocate IUCD removal, repeating the cervical smear in 6–12 weeks, and IUCD reinsertion if the repeat smears are negative.<sup>4</sup>

In conclusion, actinomycosis should be considered in the differential diagnosis of any unexplained abdominal or pelvic mass, abdominal pain or intestinal obstruction. This is particularly important in young women with an IUCD in situ.

- 1 Cintron JR, Del Pino A, Duarte B, *et al.* Abdominal actinomycosis: report of two cases and review of the literature. *Dis Colon Rectum* 1996;**39**:105–8.
- 2 O'Brien PK, Roth-Moyo LA, Davies BD. Pseudo-sulphur granules associated with intrauterine contraceptive devices. *Am J Clin Pathol* 1981;**75**:822–5.
- 3 Lippe J. Pelvic actinomycosis: a review and preliminary look at prevalences. *Am J Obstet Gynecol* 1999;**180**:265–9.
- 4 Garland SM, Rawling D. Pelvic actinomycosis in association with an intrauterine device. *Aust N Z J Obstet Gynaecol* 1993;**33**:96–8.
- 5 Fiorino AS. Intrauterine contraceptive device-associated actinomycotic abscess and actinomyces detection on cervical smear. *Obstet Gynecol* 1996;**87**:142–9.
- 6 Williams CE, Lamb GHR, Lewis-Jones HG. Pelvic actinomycosis: beware the intrauterine contraceptive device. *Br J Radiol* 1990;**63**:134–7.

### Abdominal pain after trauma in a young man

#### Q1: What is the differential diagnosis?

The differential diagnosis is (1) a haemorrhagic diathesis (haemophilia) with haematoma formation in psoas and gluteal muscles and (2) a bilateral psoas abscesses.

Though haemarthrosis, spontaneous/traumatic, is the most common and characteristic manifestation of haemophilia, spontaneous bleed into fascial planes and muscles of the abdomen causing retroperitoneal haematoma is also relatively common in haemophilia A.<sup>1</sup> Bleed into or around the iliopsoas muscle produces pain of progressive and increasing intensity and tenderness. When it occurs on the right side, it may very closely mimic acute appendicitis, appendicular mass or abscess, pelvic abscess, psoas cold abscess, and in females tubo-ovarian mass.<sup>2–4</sup> Fluid dense

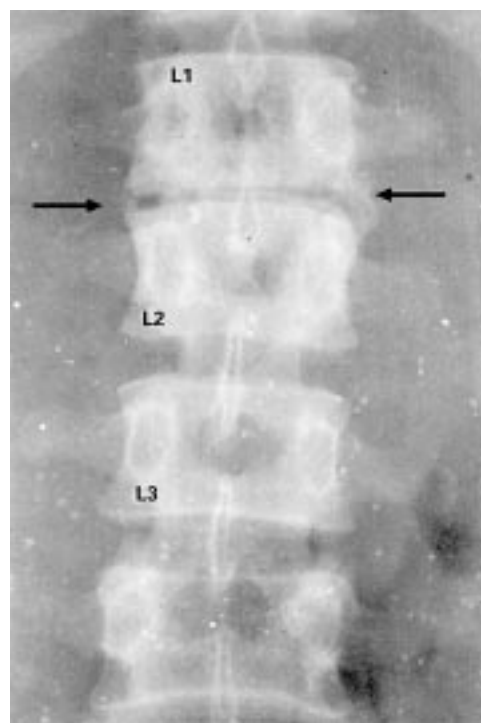


Figure 1 Radiograph of lumbar spine (anteroposterior view). Note narrowing of the L1–L2 space (arrows).

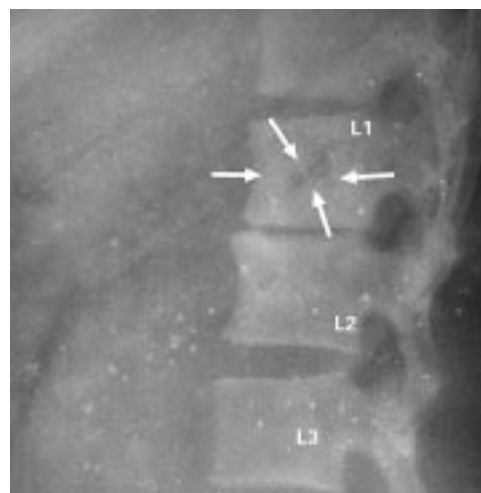


Figure 2 Radiograph of lumbar spine (lateral view) showing osteolytic area in the body of L1 vertebra (arrows). Note narrowing of the L1–L2 space.

lesions in the gluteal muscles in addition to those of the psoas muscle region favour the presumptive diagnosis of haemophilia.

Tubercular psoas abscess can be a sensible differential diagnosis for a mass lesion in the ilio-lumbar region. As atypicality is the rule with tuberculosis, cold abscess of psoas also is a high diagnostic possibility, despite bilateral occurrence being rare. It usually presents as pain in the abdomen, hip, flank, spine with limping, psoas sign, and a fluctuant mass both above and below the inguinal ligament, with a gibbus deformity in the spine. In the case illustrated, trauma was probably incidental, misleading the clinician towards a diagnosis of traumatic psoas haematoma.

**Q2: What other investigations would you consider?**

Other investigations to be considered are complete coagulation profile and radiography of the thoracolumbar spine.

**Q3: What features are atypical in the case illustrated?**

Atypical features in the case illustrated are:

- Lack of local symptoms such as backache and gibbus deformity.
- Absence of systemic symptoms of fever and weight loss.
- Lack of psoas sign and flexion deformity of the hip.
- Bilateral occurrence of psoas abscess.
- Fluid dense lesions in the gluteal muscles in a psoas abscess are very unusual.
- Trauma to the abdomen—a coincidental history may mislead the clinician to a haemorrhagic diathesis.

**Discussion**

This case illustrates an unusual presentation of caries spine with bilateral psoas abscess extending up to the gluteal region. In the context of steadily increasing abdominal discomfort after a blunt injury and mass lesions in the psoas and gluteal muscles, one should suspect a coagulation disorder such as haemophilia. But coagulopathy was ruled out as the clotting time, bleeding time, prothrombin time, activated partial thromboplastin time, and clotting factors 8 and 9 were normal. Radiography of the thoracolumbar spine showed reduced disc space between the L1 and L2 spine with osteolytic areas and sclerosis in the L1 and L2 vertebrae (see figs 1 and 2). A closed vertebral biopsy was done. Histopathological examination revealed a granuloma composed of epithelioid cells, multinucleated Langhans type giant cells, fibroblasts, and lymphocytes around a central area of caseous necrosis, suggestive of tubercular osteomyelitis. Ultrasonography guided aspiration of the mass drained around 900 ml of pus from the right side and 500 ml from the left side. The pus was abundant with acid fast bacilli, but was sterile on culture.

**Final diagnosis**

Tubercular osteomyelitis of lumbar spine with bilateral tubercular psoas abscesses.

- 1 Rodgers GM, Greenberg CS. Inherited coagulation disorders. In: Lee GR, *et al*, eds. *Winthobes clinical hematology*. Vol 2, 10th Ed. Baltimore: Williams and Wilkins, 1999: 1689.
- 2 Lobo DN, Iftikar SY, Dunn WK, *et al*. Psoas abscess complicating colonic disease: imaging and therapy. *Ann R Coll Surg Engl* 1998;**80**:405–9.
- 3 Finnerty RV, Vordumark JS, Modarelli RO, *et al*. Primary psoas abscess: case report and review of the literature. *J Urol* 1981;**126**:108–9.
- 4 Santanella RO, Fishman EK, Lipsett PA. Primary vs secondary iliopsoas abscess: presentation, microbiology and treatment. *Arch Surg* 1995;**130**:1309–13.

**Transient ST segment changes mimicking early repolarisation phenomenon in a patient with angina at rest****Q1: Describe the ECG**

The ECG shows 1 mm concave ST elevation in SII, aVF and V6, which reached 2 and 3 mm in V4 and V5, respectively. Small notches at the junctions of QRS waves and elevated ST segments are consistent with the displacement of J points (fig 1 below).

**Q2: List the electrocardiographic characteristics of early repolarisation**

The characteristics are: an upward concave elevation of the RS-T segment with distinct or “embryonic” J waves, slurred downstroke of R waves or distinct J points or both, RS-T segment elevation commonly encountered in the precordial leads and more distinct in these leads, rapid QRS transition in the precordial leads with counterclockwise rotation, and persistence of these characteristics for many years, although some intraindividual changes are common. Less commonly found are: tall R and T waves in the precordial leads, “labile” or “juvenile” T wave patterns, “pseudo R” waves, and isolated T negativity.<sup>1</sup>

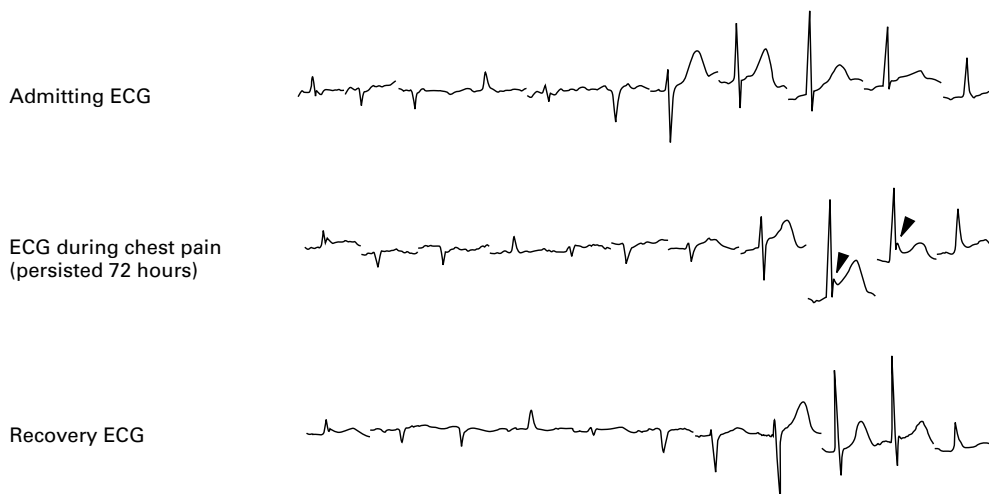


Figure 1 ECG at follow up four years after leg amputation showing small notches at the junctions of QRS waves and elevated ST segments that persisted for three days (arrow heads).

### Q3: Compare the electrocardiographic features of early repolarisation, pericarditis, and myocardial infarction

ECG manifestations of acute pericarditis or ischaemia evolve in a matter of hours or days, while ECG changes in early repolarisation remain stable over an extended period. In acute myocardial infarction, the evolving ECG changes (Q wave, ST segment) are confined to the leads reflecting the area of myocardium involved with reciprocal changes in the opposite leads. In pericarditis, the ST-T changes are almost always found in precordial as well as limb leads; but in early repolarisation mostly precordial leads, or rarely limb leads, are involved. No consistent reciprocal changes of significance are to be relied upon in the latter two conditions. In early repolarisation, the axis is usually vertical and in pericarditis is horizontal. Early repolarisation shows tall, slightly asymmetrical T waves. In myocardial injury, they are tall and symmetrical. In pericarditis, the T waves are not usually tall, and in disputable cases an ST/T ratio  $>0.25$  in V6 helps in reaching a diagnosis.<sup>2</sup>

### Discussion

Early repolarisation, also known as benign early repolarisation or normal variant, is noted in approximately 1% of the population and in up to 48% of patients seen in the emergency department with chest pain.<sup>3</sup> It represents a benign variant of the normal ECG and is one of the several syndromes producing electrocardiographic ST elevation.<sup>3</sup> It occurs almost exclusively in males under 40 years of age and is a permanent feature of their ECGs and usually disappears at older ages.<sup>4</sup> The ECG manifestations may mimic acute myocardial injury or pericarditis. Exercise and isoproterenol tend to normalise the RS-T segment elevation. The presence of early repolarisation does not preclude diagnosis of exercise induced myocardial ischaemia by treadmill testing, and coronary vaso-occlusive lesions may be demonstrated in some patients with the early repolarisation pattern on ECG. The presence of ST elevation in a patient with chest pain of possible cardiac origin mandates hospitalisation and cardiac monitoring even if the ECG demonstrates a classic pattern of early repolarisation; in this context, the diagnosis of early repolarisation is one of exclusion.<sup>5</sup>

The initial examination of the case mentioned above represented two main characteristics: chest discomfort at rest and ST elevations consistent with early repolarisation. The patient, therefore, was transferred to our coronary care unit with the initial diagnosis of acute inferolateral myocardial injury. Myocardial necrosis was excluded with the absence of cardiac enzyme changes and typical ECG evolution of an acute myocardial infarction, and with the negative scintigraphic test result. Angina pectoris and ST elevations persisted for 20 minutes and three days, respectively. The transient nature of ECG finding excluded the diagnosis of early repolarisation. Medical therapy was ordered with the final diagnosis of

coronary artery spasm and she re-transferred to the nephrology clinic in her sixth day.

Our patient was evaluated while she was followed up in hospital, therefore we had the opportunity to compare the ECG with the baseline measurements. In the majority of subjects admitted to emergency departments with any kind of chest pain, however, there is no chance of comparing the ECG with any other. In patients with chest pain a diagnosis of early repolarisation should only be considered when a cardiac cause has been excluded.

### Final diagnosis

Coronary artery spasm.

- 1 Kambara H, Philips J. Long term evaluation of early repolarization syndrome (normal variant RS-T segment elevation). *Am J Cardiol* 1976;38:156-7.
- 2 Mehta M, Jain AC, Mehta A. Early repolarization. *Clin Cardiol* 1999;22:59-65.
- 3 Brady WJ, Chan TC. Electrocardiographic manifestations: benign early repolarization. *J Emerg Med* 1999;17:473-8.
- 4 Spodick DH. Early repolarization. An underinvestigated misnomer. *Clin Cardiol* 1997;20:913-14.
- 5 Eastaugh JA. The early repolarization syndrome. *J Emerg Med* 1989;7:257-62.

### Two diagnoses from one electrocardiogram

#### Q1: What is the diagnosis?

Inferior myocardial infarction as suggested by ST segment elevation in leads II, III, and aVF. The presence of pathological Q-waves indicates that the myocardial infarction may be older than the three hours suggested by the history.

#### Q2: What complication of treatment is suggested by the ECG (fig 3; see p 604) taken the next morning?

Thrombolysis with 1.5 MU streptokinase was complicated by cerebral haemorrhage (fig 1; see p 613). Deep symmetrical T-wave inversion ("neurogenic T-waves") can occur in subarachnoid and intracerebral haemorrhage in the absence of coronary artery disease. Other ECG changes associated with cerebral haemorrhage in order of frequency are QTc prolongation, ST segment changes<sup>1</sup> and arrhythmia.<sup>2</sup> Elderly patients (>75 years) have 2-4 times the risk of this complication with 2% of those treated with tissue plasminogen activator and intravenous heparin affected.<sup>3</sup>

#### Q3: How should this be managed?

Management can be divided into reversal and/or discontinuation of precipitating factors, prophylaxis against vasospastic complication of subarachnoid haemorrhage, and neurological rehabilitation.

If neurological deterioration occurs during thrombolysis then the thrombolytic infusion should be stopped. Reversal of thrombolytic activity with tranexamic acid or fresh frozen plasma should be considered especially if signs are progressive. This patient became confused with left facial weakness more than 12 hours after thrombolysis and the only treatment modification required was discontinuation of aspirin.

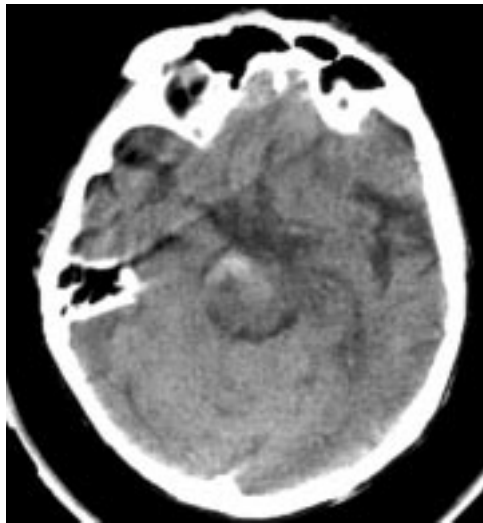


Figure 1 Computed tomography without contrast showing blood in and around the pons and deep white matter of the right cerebral hemisphere.

In the presence of subarachnoid haemorrhage prophylaxis against delayed ischaemic deficits caused by vasospasm is particularly important as the treatment of this complication involves haemodilution, hypervolaemic and hypertensive treatment (triple-H therapy) and would be perilous after myocardial infarction. Oral nimodipine, a calcium channel blocker, decreases the risk of vasospasm.<sup>4</sup> Antifibrinolytics such as aminocaproic acid have been evaluated as a means of preventing rebleeding, but do not improve outcomes probably because of increased cerebral ischaemia.<sup>5</sup> Their use should therefore be limited to acute reversal of a thrombolytic state. Sequential neurological observations are necessary to detect deterioration early, as outcomes following neurosurgical intervention and triple-H therapy are strongly affected by the level of consciousness before treatment.

The patient was transferred to another hospital for rehabilitation. Aspirin was contraindicated in the short term, but a  $\beta$ -blocker and statin were started.

#### Final diagnosis

Inferior myocardial infarction and cerebral haemorrhage.

- Ramani A, Shetty U, Kundaje GN. Electrocardiographic abnormalities in cerebrovascular accidents. *Angiology* 1990;41:681–6.
- Sen S, Stober T, Burger L, et al. Recurrent torsade de pointes type ventricular tachycardia in intracranial hemorrhage. *Intensive Care Medicine* 1984;10:263–4.
- The GUSTO Investigators. An international randomized trial comparing four thrombolytic strategies for acute myocardial infarction. *N Engl J Med* 1993;329:673–82.
- Weir B, MacDonald L. Cerebral vasospasm. *Clin Neurosurg* 1993;40:40–55.
- Beck DW, Adams HP, Flamm ES, et al. Combination of aminocaproic acid and nicardipine in treatment of aneurysmal subarachnoid hemorrhage. *Stroke* 1988;19:63–7.

#### An unusual intra-abdominal tumour

##### Q1: Comment on the computed tomogram (see p 605)

This is a contrast enhanced computed tomogram through upper abdomen. There is a well

#### Learning points

- Isolated primary omental leiomyosarcomas (stromal tumours) should be considered in the differential diagnosis of an upper abdominal mass.
- Awareness of the rare pathologies that involve the omentum and the characteristic radiological appearance of these abnormalities is essential for improving diagnosis and management of these conditions.

circumscribed, enhancing soft tissue mass in the right upper quadrant lying immediately subjacent to the stomach and the left lobe of liver.

##### Q2: Describe the macroscopic appearance of the specimen (see p 605)

The specimen shows a fleshy soft tissue mass measuring  $11 \times 8 \times 7.5$  cm within the omentum. This has extended to the stomach but has not invaded the stomach wall.

##### Q3: Describe the histological features (see p 605)

Histology shows that the omental tumour (cellular area) and muscularis propria of the stomach are completely separated by serosal vessels. The tumour is composed of spindle cells arranged in interwoven fascicles.

#### Discussion

A leiomyosarcoma is a malignant tumour of smooth muscle. Leiomyosarcomas of soft tissue (as opposed to those arising in the gastrointestinal tract) are most common in the retroperitoneum. The most important criteria for distinguishing a leiomyoma from a leiomyosarcoma is the number of mitotic figures present. The size of the lesion should also be taken into consideration. Golden and Stout stated that “if two or more mitosis per high power field are present, one can feel fairly secure in predicting malignancy”.<sup>1</sup> They have been recorded in virtually every organ but are relatively uncommon soft tissue sarcomas.<sup>2</sup> The greater omentum is rarely involved primarily by disease. In tuberculous peritonitis and carcinomatous peritonei greater omentum may present as a solidified and thickened mass.<sup>3</sup> Stout *et al* examined 24 solid tumours of the greater omentum, and leiomyomas predominated among benign neoplasms with leiomyosarcomas the most common malignant tumour.<sup>4</sup> A few more cases of this rare pathology have been reported in the literature; some of these were diagnosed on computed tomography.<sup>5,6</sup> Other rare entities involving the greater omentum that have been reported include rhabdomyosarcoma,<sup>7</sup> malignant haemangioendothelioma,<sup>8</sup> haemangiopericytoma,<sup>9</sup> actinomycosis,<sup>10</sup> and cystic lymphangioma of the omentum.<sup>11</sup> Computed tomography is usually the modality of choice for the evaluation of unusual solid mass lesions, although the site of

origin can be difficult to determine before surgery. Knowledge of the spectrum of abnormalities involving the omentum and the characteristic appearance on computed tomography of these is essential for the improved management of these conditions. Leiomyosarcomas are not responsive to either radiotherapy or chemotherapy and the only hope of cure lies in the appropriate surgical resection.

### Final diagnosis

Primary leiomyosarcoma of greater omentum.

- 1 Golden T, Stout AP. Smooth muscle tumors of gastrointestinal tract and retroperitoneal tissues. *Surg Gynecol Obstet* 1941;73:784.
- 2 Spence RAJ, Watt PC. The soft tissue. *Pathology for surgeons*. 2nd Ed. London: Butterworth Heinemann, 1993 (chap 18).
- 3 Mann CW, Williams NS, eds. The greater omentum. *Bailey and Love's short practice of surgery*. 20th Ed. London: Arnold, 1988 (chap 49).
- 4 Stout AP, Hendry J, Purdie FJ. Primary solid tumours of the greater omentum. *Cancer* 1963;16:231–4.
- 5 Vallego Soto M. Primary leiomyosarcoma of omentum. *Rev Gastroenterol Mex* 1996;61:243–5.
- 6 Mahon DE, Carp NZ, Goldhahn RT Jr, et al. Primary leiomyosarcoma of the great omentum: case report and review of literature. *Am Surg* 1993;59:160–3.
- 7 Seenu V, Misra MC, Parshad R, et al. Omental rhabdomyosarcoma presenting with pyrexia. *Indian J Gastroenterol* 1995;14:27–8.
- 8 Shih SL, Sheu J C, Chen BF, et al. Malignant haemangioendothelioma presenting as omental mass in a child. *J Pediatr Surg* 1995;30:118–19.
- 9 Cajano P, Heys SD, Ermin O. Haemangiopericytoma of the greater omentum. *Eur J Surg Oncol* 1995;21:323–4.
- 10 Lyama K, Watahiki H, Saitou M, et al. A case of actinomycosis of greater omentum. *Japanese Journal of Gastroenterology* 1995;92:894–989.
- 11 Fassler C, Vic P, Mazingue F, et al. Radiological case of the month, cystic lymphangioma of omentum. *Arch Pediatr* 1995;2:793–5.