

ADVERSE DRUG REACTION

Churg-Strauss syndrome associated with montelukast

A Mukhopadhyay, N N Stanley

Abstract

Churg-Strauss syndrome (CSS) has recently been reported in patients with asthma receiving leukotriene receptor antagonists (LTRAs). In this paper a case of CSS after treatment with montelukast is described. As in other LTRA treated cases, prior withdrawal of maintenance oral steroid may have unmasked a previously occult CSS in the patient, but a dramatic improvement in his eosinophilia after withdrawing montelukast implied that the drug also had a direct effect in activating this condition.

(*Postgrad Med J* 2001;77:390–391)

Keywords: leukotriene receptor antagonists; Churg-Strauss syndrome; eosinophilia; asthma

A 56 year old man presented with recurrent cough and wheeziness in April 1998 that responded poorly to antibiotic treatment. In July underlying asthma was suspected. His chest radiograph was normal and blood eosinophil count was $4.1 \times 10^9/l$. He was given prednisolone 30 mg daily for two weeks. His chest symptoms resolved and his peak flow rose from 300 to 450 l/min. Inhaled budesonide 400 µg daily and terbutaline 400 µg as required were started, but in September he required another two week course of prednisolone 30 mg daily. In November his cough returned. He then started prednisolone 5 mg daily for continuing medication, but during the next three months he increased its dose temporarily during two relapses. On 1 February 1999 montelukast 10 mg at night was also started and his prednisolone dosage increased to 10 mg daily. He was referred to our hospital's respiratory clinic and attended on 8 April 1999. His chest radiograph remained normal. His blood eosinophils had fallen to $0.7 \times 10^9/l$, but the serum IgE concentration was substantially increased (1279 ku/l). Skin prick tests were negative. Further adjustments to his medication made during the next month included dose reduction of prednisolone to 5 mg daily while his inhaled medication was changed to fluticasone 1000 µg and salmeterol 100 µg daily. He then became asymptomatic with his peak flow averaging 500 l/min. On 2 June 1999 he stopped taking prednisolone. For one month he remained well, but then developed diarrhoea, vomiting, and abdominal pain with dry cough and breathlessness, even though his peak flow had not declined substantially. His

blood count on 9 July 1999 showed recrudescent eosinophilia ($18.9 \times 10^9/l$). He reattended our clinic 13 days later and crackles were heard over both lungs. Chest radiography showed bibasilar infiltrates without cardiac enlargement. He was admitted that afternoon. Blood eosinophil count was $36.8 \times 10^9/l$ and by the next morning it had risen to $40.9 \times 10^9/l$. Serum IgE was 4365 ku/l, erythrocyte sedimentation rate 71 mm/hour, and C reactive protein 154 mg/l; antinuclear and anticytoplasmic antibodies were not detected. There was proteinuria (3 g/l). Overnight he developed a non-pruritic rash over both legs. A skin biopsy specimen revealed a leucocytoclastic vasculopathy with perivascular cuffing by an inflammatory exudate which included numerous eosinophils (fig 1). We diagnosed Churg-Strauss syndrome (CSS) possibly provoked by montelukast, which was discontinued. By the third day he felt well and an initial fever had disappeared. His blood eosinophil count had fallen spontaneously to $7.8 \times 10^9/l$ 60 hours after the last dose of montelukast. Given his systemic vasculitis, however, he was then restarted on prednisolone 60 mg daily. By the fifth day his eosinophil count was normal ($0.4 \times 10^9/l$) and he was discharged home. When

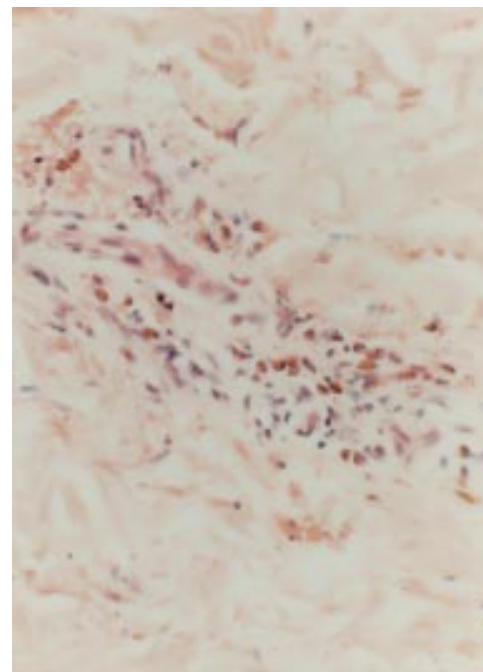


Figure 1 Photomicrograph of skin biopsy showing capillaries cuffed by an eosinophil-rich inflammatory exudate (haematoxylin and eosin, original $\times 200$).

Department of
Medicine, Lister
Hospital, Coreys Mill
Lane, Stevenage, Herts
SG1 4AB, UK

Correspondence to:
Dr Stanley

Submitted 20 June 2000
Accepted 25 September
2000

reviewed one week later he was asymptomatic with his lungs clear on auscultation. His chest radiograph had returned to normal, he had no significant proteinuria, and his skin lesions were fading. During 12 months of follow up he has kept well overall, but has been unable to reduce his prednisolone dosage below 10 mg daily without recurrent cough and feverishness accompanied by increases in blood eosinophils and IgE.

Discussion

The literature associating leukotriene receptor antagonist (LTRA) usage and CSS has recently been critically reviewed¹; this included 13 cases given zafirlukast and one given pranlukast. One case of pulmonary eosinophilia receiving montelukast had then been described²; subsequently four more patients given this drug have been reported with systemic features,³ as in our patient, which satisfy the criteria of the American College of Rheumatology for diagnosing CSS.⁴ The Medicines Control Agency (UK) has also received notification of 16 reports of CSS in patients receiving montelukast showing that the frequency of this association has not been reflected by the published record hitherto (Committee on Safety of Medicine, personal communication, 2000).

The duration of LTRA administration before our patient developed CSS was five months, compared with the average of 3.3 months (range two days to 10 months) in earlier reports. All published cases had received an oral steroid at least intermittently in the previous year and in most the steroid dosage had been reduced within two months of the onset of CSS as in our patient. Therefore using an LTRA in a steroid sparing role may have unmasked a pre-existing occult CSS in most of them. CSS has likewise been linked occasionally with other antiasthma drugs given while reducing steroid dosage.^{5,6} In cases with little previous steroid treatment the occurrence of florid CSS during LTRA usage has suggested a direct drug effect, but even these might reflect a coincidental transition from the condition's prodromal phase of asthma to its later stages with eosinophilic infiltration and vasculitis. Indeed one analysis of case rates of CSS in LTRA treated patients has suggested that these are no higher than predictable from another estimate of its background incidence in asthma.³ Whether LTRA withdrawal in such cases induces prolonged remission without continued steroid treatment might be informative and this question has received little attention. Possible direct mechanisms for LTRAs causing CSS include an idiosyncratic reaction as described with other drugs,^{7,8} or an imbalance of leukotriene production whereby inhibition of cysteinyl leukotriene type 1 receptor causes increased production of LTB₄, which is a strong chemotactic factor for eosinophils.⁹

Learning points

- LTRAs including montelukast have recently been introduced for treatment of asthma.
- CSS may be associated with LTRA administration.
- Particular caution is required if steroid dosage is reduced in patients receiving an LTRA.
- LTRA administration should be withdrawn if patients develop eosinophilia or clinical features suspicious of CSS.

Unpublished cited cases of CSS in patients receiving zileuton,³ a 5-lipoxygenase inhibitor that also blocks LTB₄, do not exclude this hypothesis if the causation is multifactorial. We believe that CSS developed in our patient through a combination of indirect and direct mechanisms. His systemic features developed one month after the withdrawal of prednisolone. His blood eosinophilia before starting any anti-inflammatory agent and continuing need for maintenance prednisolone after stopping montelukast are consistent with the presence of CSS in an occult form. A direct role of montelukast in activating florid CSS was also identified through his spontaneous clinical improvement and dramatic fall in blood eosinophils within three days after stopping its administration before restarting prednisolone.

We believe that montelukast is a useful and relatively safe drug for treating asthma, but its linkage with CSS requires particularly cautious administration if patients have features consistent with CSS in its prodromal phase and in whom steroid reduction is considered. Moreover the implication that montelukast had activated CSS also by a direct effect in our patient emphasises that LTRA treatment should be withdrawn in any patient developing systemic symptoms with hypereosinophilia.

- 1 Stirling RG, Chung KF. Leukotriene antagonists and Churg-Strauss syndrome: the smoking gun. *Thorax* 1999;54:885-6.
- 2 Franco J, Antes MJ. Pulmonary eosinophilia associated with montelukast. *Thorax* 1999;54:558-60.
- 3 Wechsler ME, Finn D, Gunawardena D, et al. Churg-Strauss syndrome in patients receiving montelukast as treatment for asthma. *Chest* 2000;117:708-13.
- 4 Masi AT, Hunder GG, Lie JT, et al. The American College of Rheumatology 1990 criteria for classification of Churg-Strauss syndrome (allergic granulomatosis and angiitis). *Arthritis Rheum* 1990;33:1094-100.
- 5 Lobel H, Machtley I, Eldor MY. Pulmonary infiltrates with eosinophilia in an asthmatic patient treated with disodium cromoglycate. *Lancet* 1972;ii:1032.
- 6 Hart B. Replacing or reducing high dose oral corticosteroid with alternative asthma controller therapies : implications for leukotriene receptor antagonists. *Eur Respir Rev* 1998; 8(63):1056-8.
- 7 Dietz A, Hubner C, Andrassy K. Macrolide antibiotic-induced vasculitis (Churg-Strauss syndrome). *Laryngorhinootologie* 1998;77:111-14.
- 8 Imai H, Nakamoto Y, Hirokawa M, et al. Carbamazepine-induced granulomatous necrotising angitis with acute-renal failure. *Nephron* 1989;51:405-8.
- 9 Spada CS, Nieves AL, Krauss AH, et al. Comparison of leukotriene B4 and D4 effects on human eosinophil and neutrophil motility in vitro. *J Leukoc Biol* 1994;55:183-91.