

## SELF ASSESSMENT QUESTIONS

## An elderly woman with dyspnoea and bronchorrhoea

J Polo, P Gil, R Arboiro, J García, P Beringola, G Marín

Answers on p 347.

A 78 year old woman presented with progressively increasing dyspnoea and cough, initially dry and later with production of whitish sputum with foamy appearance, which she had had for the last three months, accompanied by anorexia and loss of 5 kg of weight. There was no history of fever, chest pain, oedema, orthopnoea, or haemoptysis. Except for arterial hypertension treated with calcium antagonists, she had never experienced any medical or surgical problem. Examination revealed tachycardia (128 beats/min) and tachypnoea. Inspiratory crackles were heard over the lower and middle fields of both lungs. The rest of the examination was normal. During her hospital admission, sputum production increased to 600 ml in one day.

Routine blood and biochemistry values were normal. Her erythrocyte sedimentation rate was 36 and 58 mm/hour after one and two hours respectively. Arterial blood gases while breathing room air revealed oxygen tension 6.67 kPa and carbon dioxide tension 3.73 kPa, with little improvement after receiving 40%

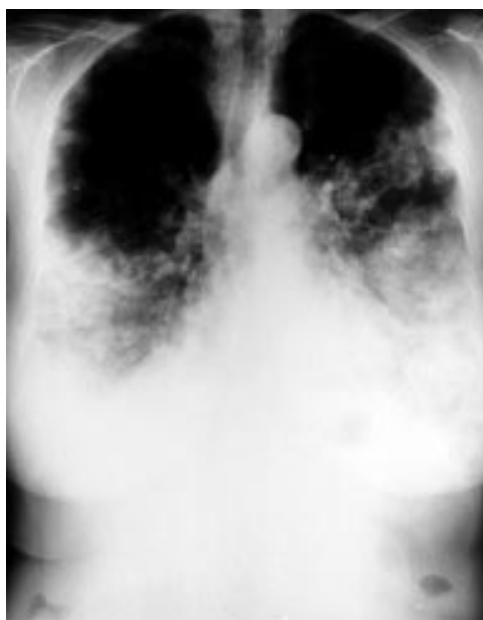

Figure 1 Radiograph of the chest.

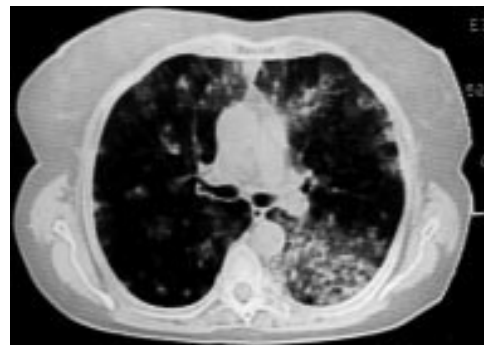

Figure 2 Computed tomogram of the thorax at the level just below the carina trachealis.

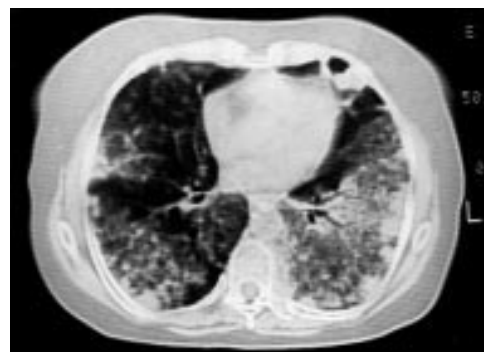

Figure 3 Computed tomogram of the thorax at the level of the axilla.

oxygen (7.73 kPa and 4.61 kPa, respectively). Serum precipitins for alternaria, aspergillus, cladosporum, penicillium, candida and thermoactinomyces, as well as cytological and microbiological studies of sputum, were all negative. Levels of angiotensin converting enzyme and total IgE were normal.

A radiograph of the chest (fig 1) showed diffuse alveolar disease. Computed tomography showed a bilateral alveolar interstitial pattern with pseudonodular densities (figs 2 and 3).

### Questions

- (1) What is your diagnosis?
- (2) What other disorders may show a diffuse alveolar pattern?
- (3) What are other causes of bronchorrhoea?

**Fundación Jiménez Díaz, Madrid, Spain:**  
Department of Internal Medicine

J Polo  
P Gil  
R Arboiro  
G Marín

**Department of Pneumology**  
J García

**Department of Radiology, CEP "Pontones", Madrid, Spain**  
P Beringola

Correspondence to:  
Dr Jorge Polo, O'Donnell 56,  
28007 Madrid, Spain  
polosabau@yahoo.com

Submitted 25 November 1999

Accepted 28 January 2000

# Unexplained weight loss and a palpable abdominal mass in a middle aged woman

N D Hawkes, G A O Thomas

Answers on p 348.

A 52 year old woman presented to the gastroenterology department with a six month history of unexplained weight loss of 2 stone (12.7 kg). She had experienced intermittent abdominal cramp-like pains but was otherwise well. In particular, there had been no alteration to her bowel habit and no rectal bleeding. Her appetite had been normal. She denied any systemic symptoms such as fatigue or night sweats. She was born in the UK, and had not travelled abroad, however her father had originated from the Yemen. Her brother had suffered bony tuberculosis 30 years previously but she had not had previous documented infection.

Three months before review she had been seen in another department for unexplained weight loss. Routine blood tests and a chest radiograph were normal. A barium meal examination showed an 8 cm, non-distensible narrowing in the upper oesophagus but a follow up endoscopy was normal. Because of ongoing weight loss she was referred to the gastroenterology department.

Apart from a thin appearance (weight 40.4 kg), general, cardiovascular, and respiratory examinations were normal. On abdominal examination a firm, non-tender, fixed mass was palpable in the right iliac fossa. Rectal examination and a rigid sigmoidoscopy were normal.

Initial investigations revealed an iron deficiency anaemia (haemoglobin concentration 104 g/l, mean corpuscular volume 79.2 fl, mean corpuscular haemoglobin 24.9 pg, ferritin 12.0 µg/l), total leucocyte count  $6.79 \times 10^9/l$ , platelets  $413 \times 10^9/l$ , serum albumin 34 g/l, erythrocyte sedimentation rate 60 mm/hour, and C reactive protein 27 mg/l. Urea and electrolytes, creatinine, glucose, liver and thyroid function tests, serum B12 and folate screen, a chest radiograph, and an electrocardiogram were normal. Abdominal ultrasound demonstrated a 2 cm ill defined mass in the right iliac fossa.

To further investigate her iron deficiency anaemia, weight loss, and right iliac fossa mass a small bowel follow-through and barium enema (figs 1 and 2) were performed.

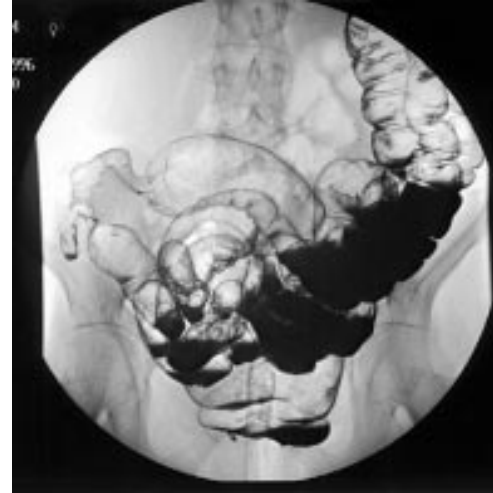

Figure 1 Double contrast barium enema study.

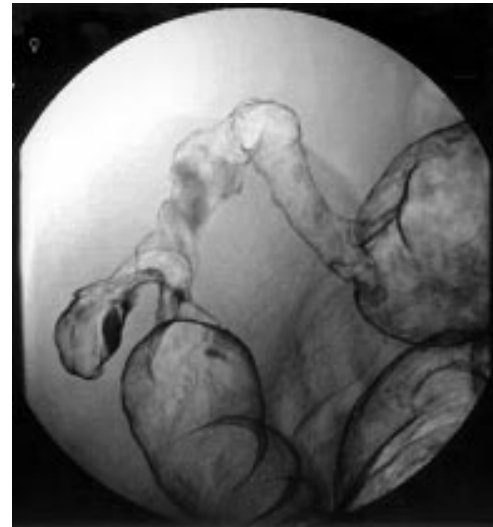


Figure 2 Detailed view of the diseased area seen in fig 1.

Department of  
Gastroenterology,  
University Hospital of  
Wales, Heath Park,  
Cardiff CF14 4XN, UK  
N D Hawkes  
G A O Thomas

Correspondence to:  
Dr Thomas

Submitted 22 June 2000  
Accepted 20 September 2000

## Questions

(1) What does the barium enema study (figs 1 and 2) show?

- (2) What is the differential diagnosis and what test should be performed to confirm the diagnosis?
- (3) What treatment would you initiate?

## Low back pain in a child—a diagnostic dilemma

S M Gajjar, S K Srivastav, S Thakur

Answers on p 349.

Department of  
Orthopaedics, King  
Edward VII Memorial  
Hospital and Seth G S  
Medical College, Parel,  
Mumbai,  
Maharashtra, India  
S M Gajjar  
S K Srivastav  
S Thakur

Correspondence to:  
Dr Shreyash M Gajjar, 3/13  
Varmanagar, Old Nagardas  
Road, Andheri (East),  
Bombay 400 069, India  
sgajjar@usa.net

Submitted 24 February 1999  
Accepted 16 February 2000

A 4 year old boy was brought with history of low back pain of seven days' duration after a trivial fall. On examination the child had tenderness in the lower lumbar spine. There was no paraspinal swelling or spinal deformity. The spinal movements were globally restricted and there was no regional lymphadenopathy or any neurovascular deficit. Systemic examination revealed no abnormality. Plain radiographs of the spine revealed a collapse of the L3 and osteopenia of L4 vertebral body (fig 1A and B). Haematological investigations showed a haemoglobin concentration of 100 g/l, leucocyte count of  $7.2 \times 10^9/l$  (polymorphs 83%, lymphocytes 12%, and eosinophils 4%), and an erythrocyte sedimentation rate of 70 mm at one hour. The child did not attend follow up

for a month, but later presented with insidious onset high grade fever not responding to salicylates. On examination of the abdomen, the liver was just palpable. There was no splenomegaly; however, the cervical lymph nodes were palpable. Repeat radiographs showed collapse of D9, D11, L2, L3 vertebral bodies (fig 2A, B, and C). A haemogram showed anaemia (haemoglobin 50 g/l), leucocyte count  $12.7 \times 10^9/l$  (polymorphs 22%, lymphocytes 76%, eosinophils 2%).

### Questions

- (1) What is the differential diagnosis?
- (2) What further investigations should be performed?
- (3) What is the treatment of this condition?

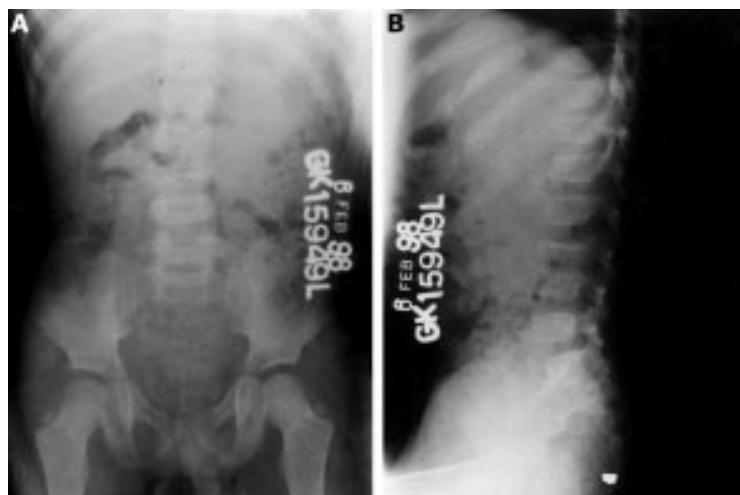

Figure 1 (A) Plain anteroposterior radiograph of the lumbar spine and (B) plain lateral radiograph of the lumbar spine.

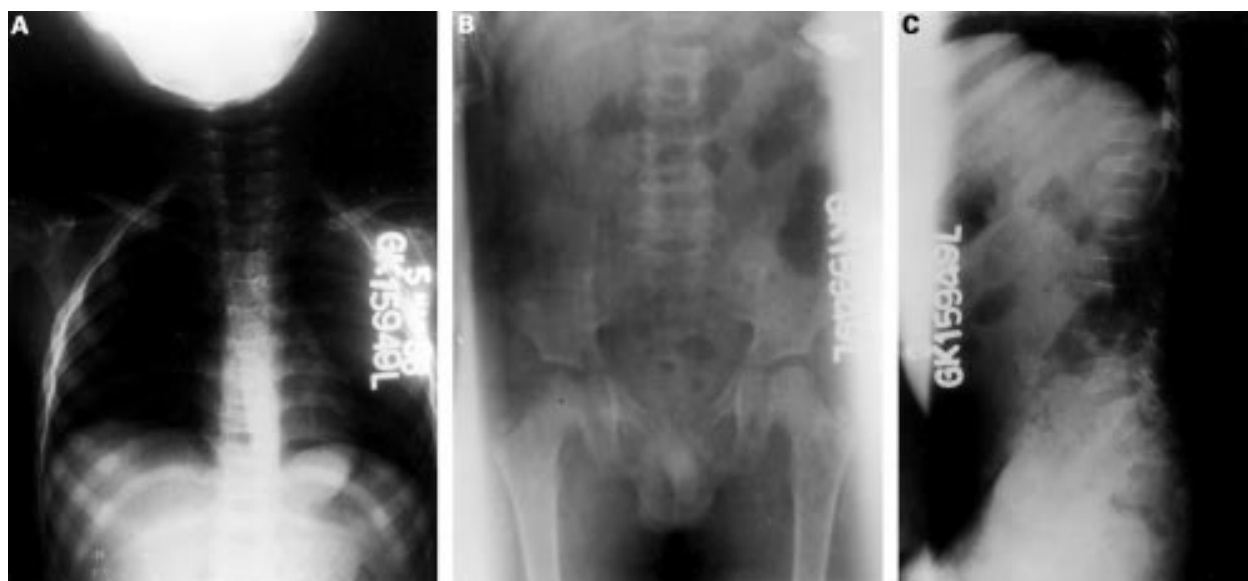


Figure 2 (A) Plain AP radiograph of the dorsal and upper lumbar spine after one month, (B) plain AP radiograph of the lower dorsal and LS spine after one month, and (C) plain lateral radiograph of the dorsal and LS spine after one month.

# Atopy, proptosis, and nasal polyposis

V Rupa, M Jacob, M S Mathews

Answers on p 350.

**Christian Medical  
College and Hospital,  
Vellore, India:  
Department of Ear,  
Nose, and Throat**  
V Rupa

**Department of  
General Pathology**  
M Jacob

**Department of  
Microbiology**  
M S Mathews

Correspondence to:  
Dr V Rupa, Department of  
ENT, Christian Medical  
College and Hospital,  
Vellore-632004, India  
rupavedantam@hotmail.com

Submitted 4 January 2000  
Accepted 28 January 2000

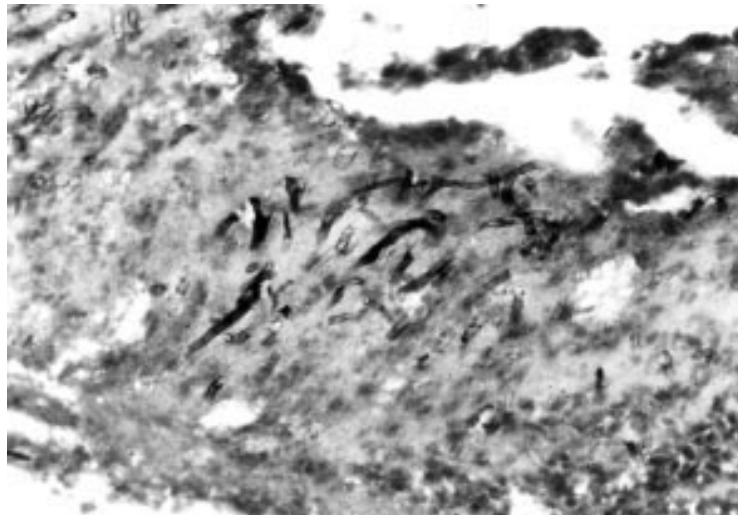


Figure 2 Haematoxylin and eosin stained section of allergic mucin showing eosinophilic mucin with layers of necrotic cells and fungal hyphae; there is no tissue invasion.

A 24 year old women presented with a history of increased prominence of the right eye and right sided headache of two months' duration. She had a two year history of recurrent, right sided nasal obstruction. She had undergone nasal polypectomy on two occasions previously at a local hospital. There was no history of diminution in vision, diplopia, fever, seizures, loss of consciousness, or epistaxis. She was not a diabetic, hypertensive, or asthmatic. There was a strong history of atopy.

On examination, she was found to be alert and afebrile. There was right sided proptosis. Fundoscopy and vision were normal. Nasal examination revealed multiple pale glistening polyps filling the right nasal cavity appearing to arise from the middle and superior meatus bilaterally. Computed tomography (fig 1) of the paranasal sinuses showed a hypodense mass filling the right anterior and posterior ethmoids, maxillary, frontal, and sphenoid sinuses bilaterally. The mass had eroded the floor and roof of the frontal sinus and roof of ethmoid sinus without dural invasion. The lamina papyraceae was thinned out. The mass extended into the superior part of the orbit but there was no optic nerve compression. Irregular hyperdense areas were seen within the mass.

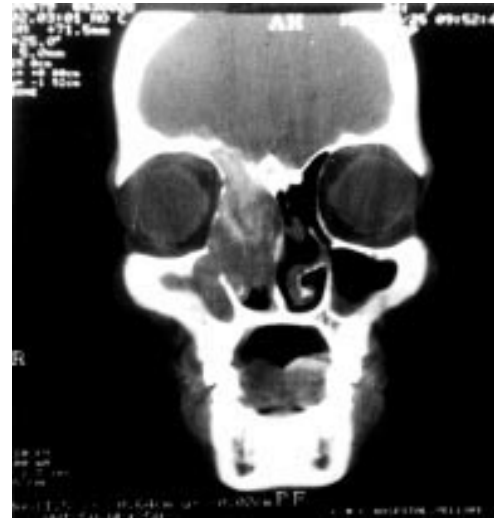

Figure 1 Computed tomography of paranasal sinuses showing hypodense soft tissue masses filling right ethmoid and maxillary sinuses and expanding right ethmoid sinuses with thinning of lamina papyraceae and erosion of the roof; hyperdense areas representing allergic mucin are seen within the mass.

Blood tests results were normal except for eosinophilia (13%). The patient underwent excision of the nasal mass via a lateral rhinotomy approach using a Lynch-Howarth incision. This approach was preferred over an endoscopic approach because of better access to the frontal sinus. Operative findings included the presence of multiple polyps interspersed with clumps of blackish-brown material with a peanut butter-like consistency (allergic mucin) filling the ethmoid and sphenoid sinuses bilaterally. The excised specimen was sent for histopathology and fungal culture. The histopathological appearance was diagnostic (fig 2). *Aspergillus flavus* was isolated on fungal culture. Postoperatively, she had complete resolution of proptosis, nasal obstruction, and headache.

## Questions

- (1) What is the diagnosis?
- (2) What is allergic mucin?
- (3) What is the pathophysiology of the disease?



## Recurrent syncope

R J R Mansfield, R D Thomas

Answers on p 352.

A 31 year old man was admitted with recurrent syncope.

### Questions

(1) Describe the abnormal features on his 12 lead electrocardiogram (fig 1).

(2) What is the diagnosis and what are the causes of this condition?

(3) What classical arrhythmia is associated with this condition?

(4) How would you treat this man?

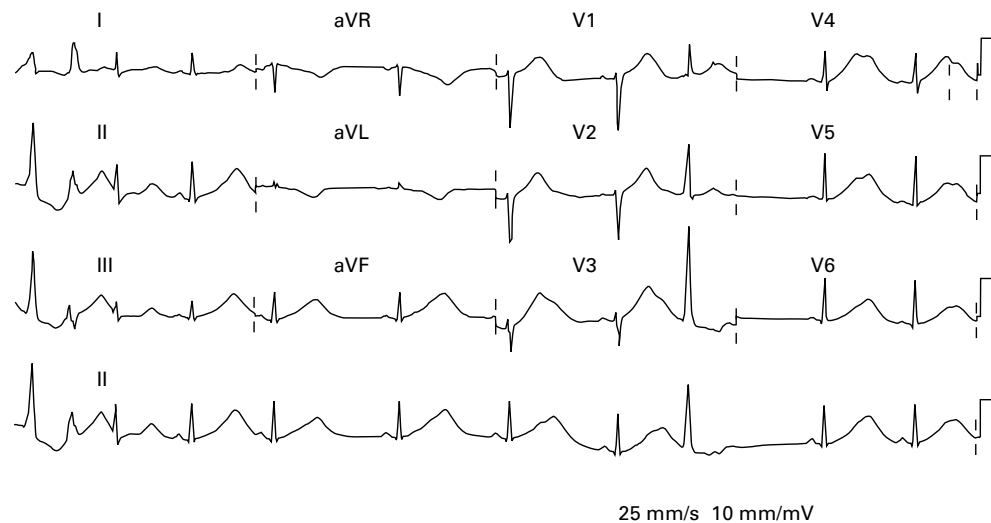


Figure 1 12 lead electrocardiogram.

Cardiac Centre, Royal United Hospital, Bath, UK  
R J R Mansfield  
R D Thomas

Correspondence to:  
Dr R J R Mansfield,  
Cardiovascular Repair and Remodelling Group, 5th Floor Sir Jules Thorn Institute, Middlesex Hospital, Mortimer Street, London W1N 8AA, UK  
r.mansfield@ucl.ac.uk

Submitted 10 January 2000  
Accepted 16 February 2000

## Sequential occurrence within three years in a premenopausal woman of cervical, ovarian, and endometrial cancers

G P Cumming, G V Narayansingh, D E Parkin, N Haites

Answers on p 353.

A 36 year old woman (para 0 + 1) was referred to the colposcopy clinic in August 1995 after a routine cervical smear had shown severe dyskaryosis. Her previous smears had been unremarkable and she had no risk factors for developing cervical abnormalities. She suffered from ulcerative colitis and two paternal uncles had developed colorectal cancer.

The colposcopic directed punch biopsy was reported as showing cervical intraepithelial neoplasia (CIN) III with an area of squamous carcinoma.

After subsequent examination under anaesthesia she was staged as having an 1B cervical carcinoma. Histologically the tumour had invaded to a depth of 1 mm and had spread laterally to 10 mm. Because of her desire to preserve fertility, she decided after extensive counselling to be treated as conservatively as possible and a cone biopsy was performed. As the tumour was close to the excision margins a repeat cone biopsy was performed to obtain more extensive tumour-free margins. Subsequent histology

was negative and follow up colposcopy was arranged.

In September 1996 she presented with abdominal discomfort. A pelvic ultrasound scan demonstrated an 8 cm left simple ovarian cyst. The serum CA 125 (a tumour marker for epithelial ovarian cancer) was normal. At surgery the cyst appeared to be benign and only a left oophorectomy was performed.

However histological examination diagnosed a clear cell variant of endometrioid carcinoma with an intact capsule. She was therefore referred to the gynaecological oncological unit for further management. A staging laparotomy was performed which included peritoneal washings, examination of all peritoneal surfaces and biopsy of right ovary, an infracolic omentectomy, and pelvic lymphadenectomy. All specimens were reported as negative and the ovarian carcinoma was staged as an 1A.

Thereafter she was followed up in the gynaecological oncology clinic at three monthly intervals. In early 1998, at a review

Aberdeen Royal Hospitals, Aberdeen Maternity Hospital, Cornhill Road, Aberdeen, UK

G P Cumming  
G V Narayansingh  
D E Parkin  
N Haites

Correspondence to:  
Dr G P Cumming,  
2 Reidhaven Street, Elgin IV30 1QG, Scotland, UK  
grant.cumming@arh.grampian.scot.nhs.uk

Submitted 5 January 2000  
Accepted 10 February 2000

appointment, she reported a new symptom of menorrhagia. As clinical examination was unremarkable and as her symptoms were tolerable, reassurance was given. However, the menorrhagia persisted and in September 1998 at the age of 38 years, an endometrial biopsy with a Pipelle de Cornier was attempted. This was unsuccessful, secondary to narrowing of the cervical canal from her previous cone biopsies. Definitive endometrial assessment in the form of hysteroscopy and dilatation and curettage was therefore performed in October 1998. At this procedure, thick suspicious cur-rettings were obtained from a normal sized uterine cavity.

These were reported as grade 2 endometrioid adenocarcinoma. She was therefore counselled that treatment would entail a

hysterectomy and right oophorectomy with loss of childbearing potential. Two weeks later she underwent surgery and the endometrial carcinoma was staged as a 1B. This was considered by the pathologist to be a new primary after her ovarian pathology had been reviewed.

Postoperatively she made an uneventful recovery.

### Questions

- (1) What is the management of a 1B squamous cervical carcinoma in a patient who wishes to preserve fertility?
- (2) What are the guidelines in the investigation of menorrhagia in a women under 40 years?
- (3) What further course of management should be recommended for this patient?

## An 80 year old woman with intermittent severe vomiting

I S Shaw, S D Hearing, C S J Probert

Answers on p 354.

An 80 year old woman presented with a two year history of vomiting, increasingly severe epigastric discomfort after eating, and 1.5 stone (10 kg) weight loss. The vomiting episodes were intermittent, with individual episodes lasting for approximately 48 hours. During these periods she was unable to tolerate food or liquid and on occasions described small amounts of "coffee ground" haematemesis. Initial investigation included a chest radiograph (fig 1).

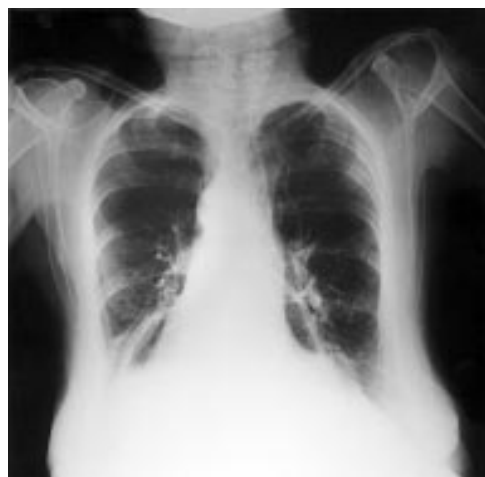

Figure 1 Chest radiograph of patient.

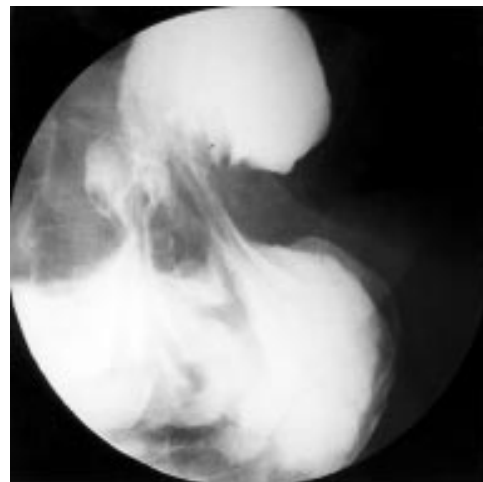

Figure 2 Further radiological investigation.

Subsequently she went on to have a further radiological investigation (fig 2).

### Questions

- (1) What does the chest radiograph show?
- (2) What investigation is shown in fig 2 and what does it demonstrate? How does this relate to the presenting complaint?
- (3) How else can this condition present?
- (4) How should this woman be managed?

**Bristol Royal  
Infirmary, Bristol, UK:  
Department of  
Gastroenterology**  
I S Shaw

**University Division of  
Medicine**  
S D Hearing  
C S J Probert

Correspondence to:  
Dr Christopher S J Probert,  
University Division of  
Medicine, Bristol Royal  
Infirmary, Bristol BS2 8HW,  
UK  
c.s.j.probert@bristol.ac.uk

Submitted 16 August 2000  
Accepted 20 September 2000

## Pleuropericardial effusion in a 50 year old woman

M Pasteur, C Laroche, M Keogan

Answers on p 355.

A 50 year old woman was referred by her general practitioner for investigation of a six month history of dry cough, intermittent night sweats, and arthralgia affecting the wrist joints. Two weeks before her appointment she had noticed exertional breathlessness, mild ankle swelling, and flitting chest pains. There was no other past medical history and she was not taking any drugs. On examination she was pyrexial ( $37.6^{\circ}\text{C}$ ) and both wrist joints were warm and painful to move (no other joints were affected). Other abnormal findings were a slightly raised jugular venous pressure, quiet heart sounds, and mild ankle oedema. Her chest was clear, abdominal examination unremarkable, and there was no rash. A chest radiograph showed cardiac enlargement (fig 1A) with clear lung fields and she was admitted for further investigations.

While an inpatient she had a spiking pyrexia up to  $38^{\circ}\text{C}$ . Full blood count showed haemoglobin concentration 118 g/l, white cell count  $7.9 \times 10^9/\text{l}$  with normal differential, and the erythrocyte sedimentation rate (ESR) was 25 mm/hour. Liver function tests were normal apart from a mildly raised alanine aminotransferase of 44 IU/l. An echocardiogram showed a large pericardial effusion which was drained with some improvement in her cough. Two weeks later worsening chest pains, recurrence of cough, and malaise led to further investigations. She now had a daily spiking fever up to  $40^{\circ}\text{C}$ , usually in the evening, which returned to normal or below normal. ESR had risen to 110 mm/hour and haemoglobin had dropped to 97 g/l. The white cell count was  $11.4 \times 10^9/\text{l}$  with a neutrophilia of  $9.8 \times 10^9/\text{l}$ . Repeat echocardiogram did not show any pericardial fluid reaccumulation but a further chest radiograph showed moderate left and right pleural effusions (fig 1B).

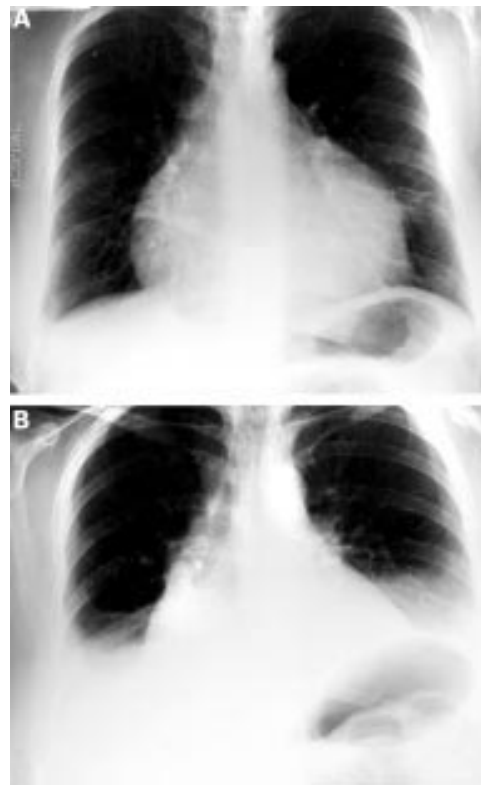


Figure 1 Chest radiographs of the patient (A) shortly after presentation showing cardiac enlargement due to pericardial effusion and (B) two weeks later showing bilateral pleural effusions.

### Questions

- (1) What are the common causes of pleuropericardial effusion?
- (2) What further investigations are necessary in this patient's case?
- (3) The patient's symptoms and radiology returned to normal after treatment with aspirin 3.6 g daily. What is the likely diagnosis?

**Chest Medical Unit,  
Papworth Hospital,  
Cambridge, UK**  
M Pasteur  
C Laroche

**Department of  
Immunology,  
Beaumont Hospital,  
Dublin, Ireland**  
M Keogan

Correspondence to:  
Dr M C Pasteur,  
Department of Respiratory  
Medicine, Leicester House,  
Norfolk and Norwich  
Hospital, Norwich NR1 3SR,  
UK  
mark@pasteurm.freereserve.  
co.uk

Submitted 25 June 1999  
Accepted 20 January 2000