

SELF ASSESSMENT QUESTIONS

Diagnostic issues in systemic lupus erythematosus

N Sofat, C Higgins

Answers on p 274.

A 24 year old woman was diagnosed with systemic lupus erythematosus (SLE) based on a few months' history of a photosensitive skin rash, predominantly on her face, arthralgia involving both hands and wrists, a positive antinuclear antibody (ANA) test and a raised antinative double stranded DNA antibody binding level. She was treated with oral hydroxychloroquine 400 mg daily and short courses of prednisolone during flare-ups.

She was reviewed in clinic for her regular follow up appointment when she was found to be hypertensive on repeated measurements of her blood pressure, an average value being 150/90 mm Hg. She was also urine dipstick positive for blood and protein.

Questions

- (1) Which three tests would you ask for next from the clinic?
 - (a) 24 hour urine collection for protein
 - (b) Measurement of erythrocyte sedimentation rate (ESR) and C reactive protein (CRP)
 - (c) Urgent urine microscopy for evidence of casts
 - (d) Measurement of DNA binding titres
 - (e) Renal tract ultrasound scan
 - (f) Measurement of serum urea, electrolytes, and creatinine
- (2) What instructions do you give to a patient in order to perform a 24 hour urine protein collection?
- (3) Can a 24 hour urine collection under/over estimate the glomerular filtration rate?

- (4) What other tests (apart from 24 hour urine creatinine clearance) are available to measure the glomerular filtration rate?

The patient had a 24 hour urinary protein collection, which showed a 24 hour protein measurement of 1.8 g. There was no evidence of cellular casts on urine microscopy. Her blood results were as below (normal values are in parentheses):

- Sodium 134 mmol/l (135–145)
- Potassium 4.5 mmol/l (3.5–5.0)
- Urea 7.0 mmol/l (2.5–6.7)
- Creatinine 173 μ mol/l (70–115)
- Haemoglobin 108 g/l (115–160)
- White cell count $4.5 \times 10^9/l$ (4.0–11.0)
- Platelets $130 \times 10^9/l$ (150–400)

IMMUNOLOGY RESULTS

- C3 0.30 g/l (0.77–1.63)
- C4 <0.10 g/l (14–42)
- ESR 42 mm/hour
- CRP 40 mg/l (0–10)
- ANA positive at 1:2560
- DNA binding 1000 IU/ml (0–30)

- (5) What is the likely cause of this clinical picture and results?

- (a) Urinary tract infection
- (b) Dehydration
- (c) Essential hypertension
- (d) SLE associated lupus nephritis
- (e) Renal amyloidosis

- (6) If this patient had persistently lowered complement levels from the time of her diagnosis, both during remission and relapses of her SLE, what other diagnosis would you have to consider?
- (7) Which investigation would you like to do next in order to obtain diagnostic and prognostic information regarding the cause of this women's renal impairment?

- (a) Intravenous urogram
- (b) Renal biopsy
- (c) Renal tract ultrasound scan
- (d) Repeat urea and electrolytes
- (e) Renal EDTA clearance

The result of the renal biopsy showed diffuse proliferative glomerulonephritis (World Health Organisation (WHO) grade IV). Figure 1 is an illustration of the changes seen.

The patient was initially treated with pulsed methylprednisolone but her renal function did not improve. She consented for treatment with monthly pulsed cyclophosphamide for six months, after which her renal function improved and she remained normotensive.

- (8) What issues would you have to consider and counsel the patient for when gaining consent from a young woman for treatment with cyclophosphamide?

Northwick Park and St Marks' Hospital,
Watford Road,
Harrow, Middlesex
HA1 3UJ, UK
N Sofat
C Higgins

Correspondence to:
Dr Higgins
c.higgins@ic.ac.uk

Submitted 2 April 2000
Accepted 11 July 2000

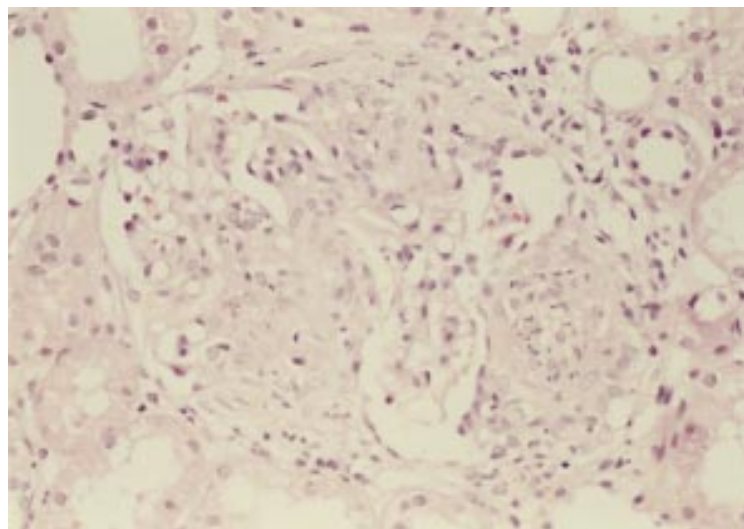


Figure 1 Light microscopy of renal biopsy showing proliferative changes throughout the glomerulus consistent with WHO class IV lupus nephritis (haematoxylin and eosin stain).

Answers on p 275.

Optic disc oedema in first degree relatives with different macrovascular risk factors (type 1 diabetes and hypertension)

Department of
Diabetes, Royal
Infirmary, Lauriston
Place, Edinburgh
EH3 9YW, UK

J M Idiculla
R S Lindsay
J D Walker
B M Frier

J M Idiculla, R S Lindsay, B W Fleck, J D Walker, B M Frier

Department of
Ophthalmology,
Princess Alexandra
Eye Pavilion, Royal
Infirmary, Edinburgh
B W Fleck

Correspondence to:
Dr Frier

Submitted 9 June 1999
Accepted 13 January 2000

Case reports

CASE 1

A 43 year old man with type 1 (insulin dependent) diabetes for 16 years presented to the ophthalmology clinic with sudden onset of painless loss of vision in the right eye. On examination, visual acuity in the right eye was reduced to counting fingers. An afferent pupillary defect was noted and fundoscopy revealed a pale oedematous disc with surface flame

haemorrhages (fig 1B). Visual acuity and examination of the left eye were normal. He had no microvascular or macrovascular complications of diabetes and had maintained good glycaemic control with glycated haemoglobin concentrations consistently below 8% (local non-diabetic range 5.0%–6.5%). He smoked 20 cigarettes per day, was normotensive, and his total plasma cholesterol was normal (4.6 mmol/l). Fluorescein angiography was consistent with oedema of the optic disc. Investigations including a computed tomography of the brain, full blood count, erythrocyte sedimentation rate, plasma biochemistry, serum vitamin B₁₂ concentration, thrombophilia screen, and an autoantibody screen were all normal, and clinical examination by a neurologist detected no additional abnormalities. No improvement in vision occurred during the following 12 months and the right optic disc revealed optic atrophy.

CASE 2

Two months after case 1 had presented with visual loss, his 73 year old mother presented to the same ophthalmology clinic complaining that she was experiencing "a curtain of blackness" in her left eye. In the left eye the visual acuity was 1/60 and less than N48 and in the right eye 6/12+2 and N6. Fundal examination revealed swelling of the left optic disc and an afferent pupillary defect. A lower left altitudinal field defect was demonstrated and investigations similar to those in case 1, did not show any abnormal findings. The patient had established hypertension treated with amlodipine and doxazosin. She was a non-smoker and her total plasma cholesterol was 6.0 mmol/l. An oral glucose tolerance test was normal. Her vision did not improve over the following eight months, but her left optic fundus showed features of optic atrophy (fig 2).

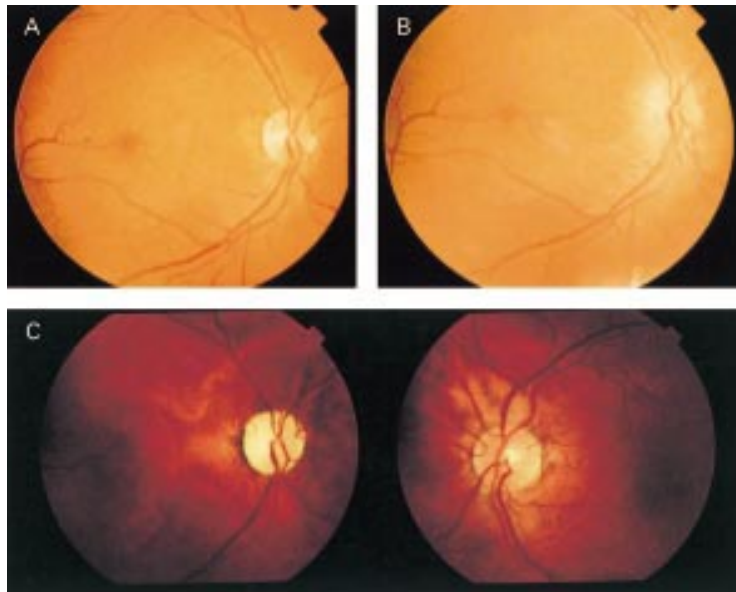


Figure 1 Case 1: (A) right optic fundus before the development of acute ischaemia; (B) acute ischaemic phase in the right optic fundus; (C) optic fundi six months after the acute episode. The pale disc on the right is suggestive of optic atrophy.

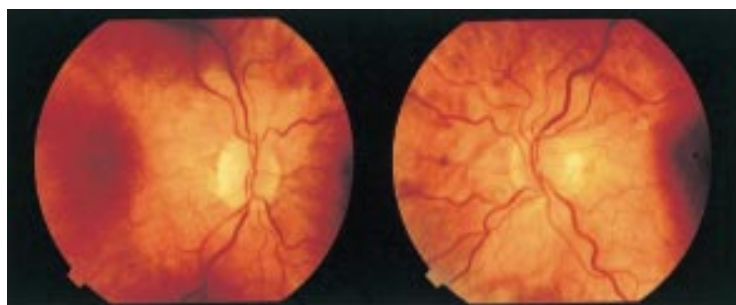


Figure 2 Case 2: optic fundi four months after the acute episode. The left disc is paler consistent with optic atrophy.

Questions

- (1) What are the diagnostic possibilities and what is the most likely diagnosis?
- (2) What are the risk factors for non-arteritic anterior ischaemic optic neuropathy?
- (3) What are the therapeutic options available for this condition?

An unusual palmoplantar pigmentation

G Sethuraman, M D'Souza, M Vijaikumar, K Karthikeyan, K Ramachandra Rao, D M Thappa

Answers on p 277.

Jawaharlal Institute of Postgraduate Medical Education and Research, Pondicherry, India:
Departments of Dermatology and Sexually Transmitted Diseases
 G Sethuraman
 M D'Souza
 M Vijaikumar
 K Karthikeyan
 D M Thappa

Division of Cytogenetics (Department of Anatomy)
 K Ramachandra Rao

Correspondence to:
 Dr Mariette D'Souza, Type V/12, Dhanvantari Nagar, JIPMER Campus, Pondicherry 605 006, India
 s_m77@hotmail.com

Submitted 14 December 1999
 Accepted 13 January 2000

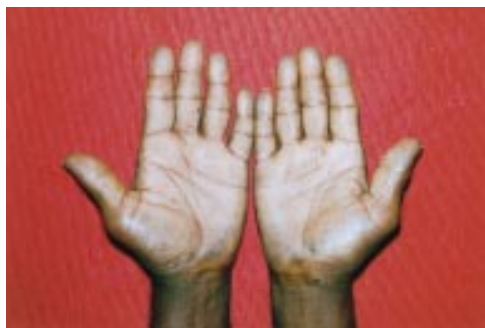

Figure 1 Palms showing progressive pigmentation.

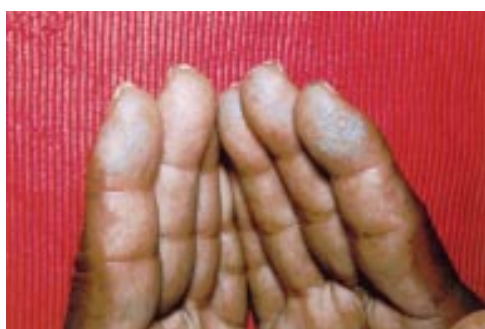

Figure 2 Fingertips showing progressive pigmentation.

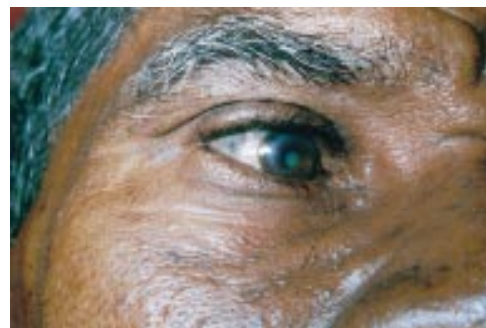

Figure 3 Discoloration of sclerae.

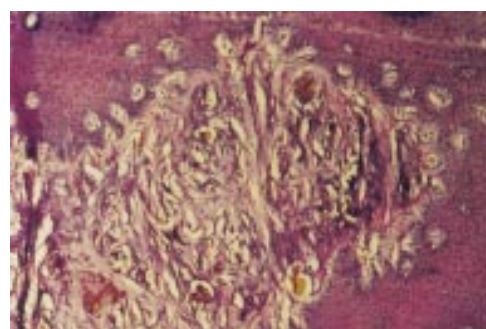


Figure 4 Histopathology of the skin lesion.

A 60 year old man had asymptomatic progressive pigmentation of the palms (fig 1), fingertips (fig 2), and soles for the last 20 years. Besides this, he had discoloration of his sclerae (fig 3). He was well but for low backache and joint pains of a few months' duration. Histopathological examination of the skin lesion was diagnostic (fig 4).

Questions

- (1) What is your diagnosis?
- (2) What are the bedside tests by which you can confirm your diagnosis?
- (3) What are the complications of this disease?

All photographs reproduced with patient's permission.

An unusual cause of tremor in an elderly man

S A W Fadilah, A A Raymond, S K Cheong

Answers on p 277.

A 70 year old man presented with a two day history of coarse tremors of the head and upper limbs. The tremor was evident at rest and it became more obvious on movement. There were no symptoms of hyperthyroidism or history of a similar problem in the past. Apart from slight low back pain, he had been in good health. His urinary and bowel habits were normal. He denied taking any drugs. He was a non-smoker and a teetotaler.

On examination, the patient appeared pale. Coarse tremors of the head and upper limbs were evident at rest. The tremor of the head

consisted of vertical head nodding. The upper limb tremor was markedly accentuated during the finger-nose test and mildly accentuated by holding the arms outstretched parallel to the floor. Neurological examination otherwise showed no abnormality. There was mild prostatic enlargement noted on digital rectal examination. Chest and abdomen examination was unremarkable.

The haemoglobin concentration was 86 g/l with normal red cell indices, white cell count $2.3 \times 10^9/l$, and platelet count $88 \times 10^9/l$. Microscopic examination of the peripheral

blood did not reveal leucoerythroblastosis. The erythrocyte sedimentation rate was 102 mm in the first hour. Bone profile was recorded as calcium 2.9 mmol/l (normal range 2.2–2.6), phosphorus 1.2 mmol/l (0.8–1.4), and alkaline phosphatase 678 IU/l (40–120). The thyroid, renal, and liver profiles were within normal limits. The radiograph of the lumbar spine is shown in fig 1. Chest radiography and contrasted computed tomography of the brain

did not reveal any abnormality. An aspirate of the bone marrow is shown in fig 2.

Department of Haematology and Transplantation, MAKNA-HUKM Cancer Institute, Kuala Lumpur, Malaysia
S A W Fadilah
S K Cheong

Department of Medicine (Division of Neurology), Hospital Universiti Kebangsaan Malaysia (HUKM), Kuala Lumpur, Malaysia
A A Raymond

Correspondence to:
Dr S Fadilah, Department of Medicine, Faculty of Medicine, Universiti Kebangsaan Malaysia (UKM), Jalan Yaacob Latif, Bandar Tun Razak, 56000 Kuala Lumpur, Malaysia
sfadilah@mail.hukm.ukm.my

Submitted 20 September 1999
Accepted 20 December 1999

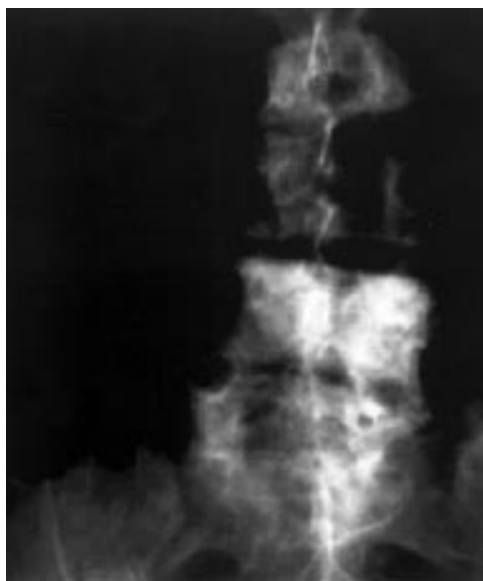


Figure 1 Radiograph of the lumbar spine showing sclerotic lesions of the lower lumbar vertebrae.

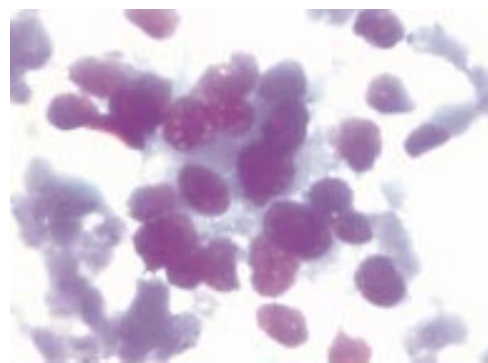


Figure 2 Aspirate of the bone marrow showing a clump of neoplastic cells infiltrating the marrow (May-Grunwald-Giemsa $\times 400$).

A 35 year man with acromegaly and neck stiffness

A S Kashyap, S Kashyap

Answers on p 279.

Armed Forces Medical College, Pune 411 040, India: Department of Medicine
A S Kashyap

Department of Hospital Administration
S Kashyap

Correspondence to:
Dr A S Kashyap

Submitted 21 May 1999
Accepted 13 January 2000

A 35 year old man was referred for acromegaly by primary physicians. He complained of mild diffuse headache and easy fatigability. Clinically he had somatic features of acromegaly and his visual acuity was reduced (6/30: left eye, 6/36 right eye) with a bitemporal superior quadrantanopia. Fundi were normal. He was normotensive and the rest of the clinical examination was normal. His basal hormone concentrations were: growth hormone (random) >25 mU/l (reference range <10), insulin like growth factor-1 level 210 nmol/l (14–45), serum alpha subunit not raised (<0.3 IU/l), prolactin 450 mU/l (60–390), luteinising hormone 8.0 U/l (2.5–9.0), follicle stimulating hormone 7.5 U/l (1.5–9.0), thyroid stimulating hormone 2.5 mU/l (0.5–4.5), free thyroxine 18 pmol/l (10–27), serum cortisol 8 am (basal) 500 nmol/l (160–565), and testosterone 20 nmol/l (10–30). Cranial contrast enhanced computed tomography demonstrated an enhancing sellar mass with suprasellar extension (fig 1). The patient was advised

to have surgery and in the interim period was put on octreotide 100 μ g subcutaneously eight

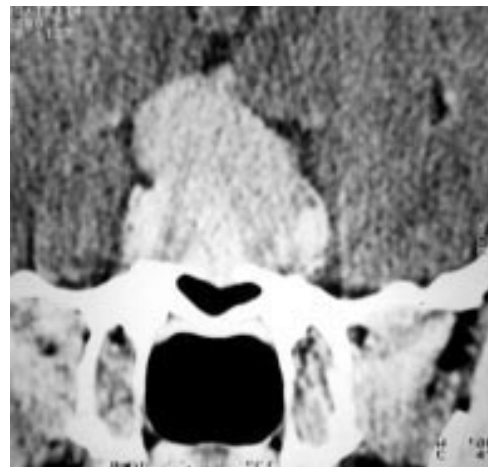


Figure 1 Computed tomogram showing an enhancing sellar mass with suprasellar extension.

hourly, with rapid relief in his headache. Three weeks later the patient was brought to the emergency room with severe diffuse headache, nausea, vomiting, diminished vision, and lethargy of five hours' duration. There was no history of fever. Clinically he was confused and irritable. He had neck stiffness, left sided complete third nerve paralysis, and bilateral papilloedema. Visual fields and acuity of vision could not be examined. Plain and contrast enhanced computed tomography showed a

high density fluid level in the sella and evidence of subarachnoid blood in the basal and suprasellar cisterns.

Questions

- (1) What is the diagnosis?
- (2) What are the two most critical alternative diagnoses?
- (3) What is the role of lumbar puncture in this patient?

Joint pains, hoarseness, and deafness

N Younis, I F Casson

Answers on p 280.

A 60 year old woman presented with a six week history of symmetrical joint pains affecting her large joints, associated with night sweats and weight loss. Recently she had noted hoarseness of her voice. She had no other relevant history apart from type 2 diabetes for 10 years. Clinical examination revealed stridor and conductive nerve deafness and the abnormality shown in figs 1 and 2. Investigations revealed a normocytic normochromic anaemia with a haemoglobin of 89 g/l and an erythrocyte

sedimentation rate of 83 mm/hour. She had normal chest radiography and negative rheumatoid factor and antinuclear factor antibodies.

Questions

- (1) What is the most likely diagnosis and the differential diagnosis?
- (2) What further investigations should be performed?
- (3) How would you treat this condition?

Department of
Medicine, Royal
Liverpool and
Broadgreen University
Hospital, Liverpool,
UK
N Younis
I F Casson

Correspondence to:
Dr N Younis, 7C link, Royal
Liverpool and Broadgreen
University Hospital, Prescot
Street, Liverpool L7 8XP,
UK
naveedy@tinyonline.co.uk

Submitted 1 March 1999
Accepted 20 January 2000

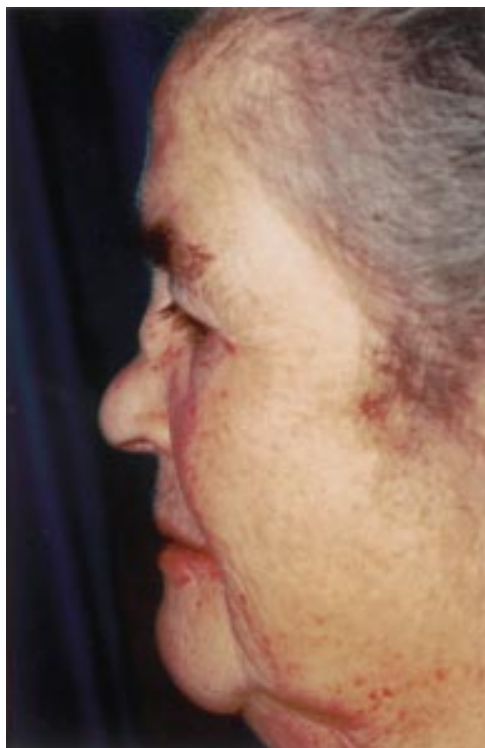

Figure 1 Lateral facial view (photograph reproduced with patient's permission).

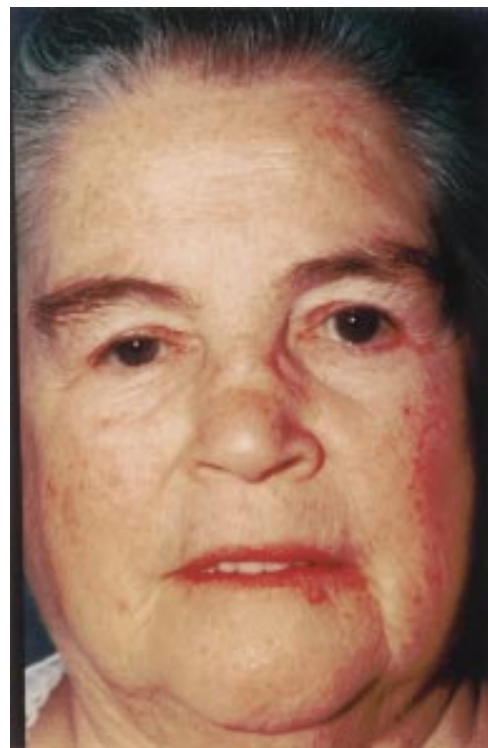

Figure 2 Frontal facial view (photograph reproduced with patient's permission).

Helicobacter heilmannii

L Williams, M J Dew, L A Murray

Answers on p 281.

A 48 year old man was referred to the open access endoscopy service by his general practitioner. He gave a 12 month history of epigastric pain and nausea and was receiving Gaviscon. He was an ex-smoker admitting to minimal alcohol intake.

The gastroscopy was normal but the histology of the biopsy specimens of the gastric antrum (figs 1 and 2) showed superficial

chronic gastritis with *Helicobacter heilmannii* but no *Helicobacter pylori* was seen.

Questions

- (1) What is *Helicobacter heilmannii*?
- (2) What does it do?
- (3) What is the clinical significance?
- (4) Does it require treatment?

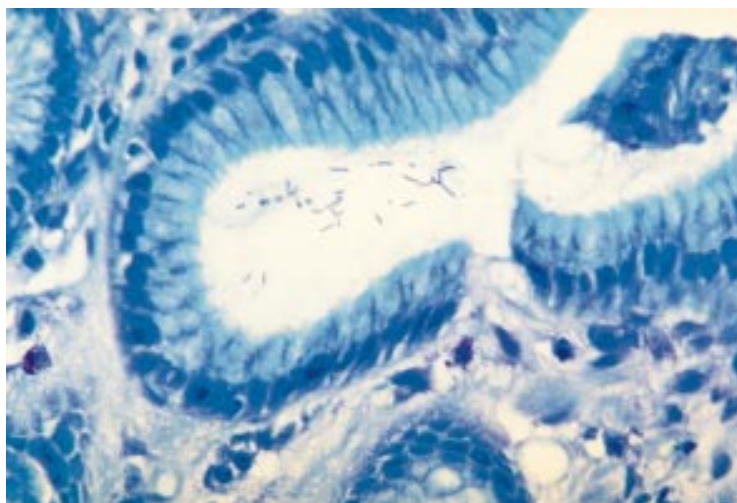


Figure 1 Gastric mucosa with *H heilmannii* on surface (Giemsa stain, oil immersion lens $\times 400$).

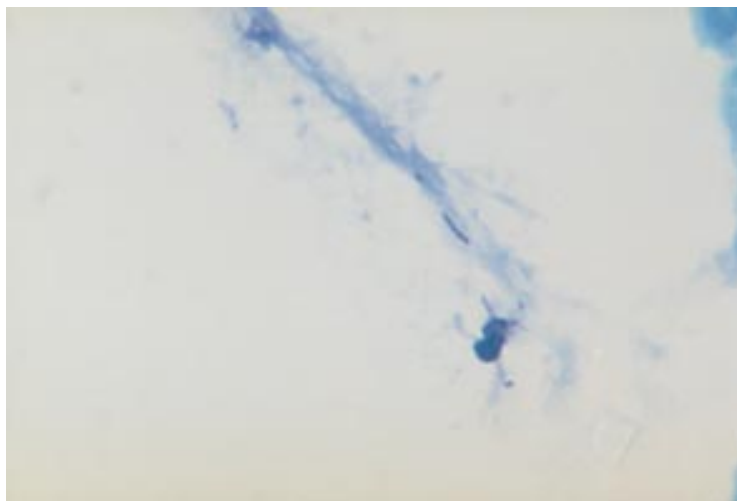


Figure 2 *H heilmannii* (Giemsa stain, oil immersion lens $\times 600$).

Prince Philip Hospital,
Bryngwynmawr,
Dagen, Llanelli
SA14 8QF, Wales, UK
L Williams
M J Dew
L A Murray

Correspondence to:
Dr Williams

Submitted 10 January 2000
Accepted 19 April 2000

Chronic pulmonary suppuration

S Banerjee, P Sundaram, J M Joshi

Answers on p 282.

A 25 year old male non-smoker presented to us with a history of cough with mucopurulent expectoration and dyspnoea on exertion since childhood. There were symptoms of frequent

infective exacerbations requiring antibiotic treatment. Empirical antituberculosis treatment had been given two years before on the basis of symptoms and chest radiographic findings in another institute. On physical examination, there was pallor but clubbing was absent. Chest examination revealed bronchial breath sounds in the right infrascapular area and bilateral coarse crackles. Haematological investigations showed anaemia with a haemoglobin concentration of 120 g/l, but other biochemical parameters were within normal limits. Sputum smear and culture examination were negative for bacteria and acid-fast bacilli. Spirometry showed a restrictive abnormality: forced vital capacity (FVC) 1.5 litres (predicted 4.05 litres), forced expiratory volume in one second (FEV_1) 1.25 litres, and FEV_1/FVC ratio of 83%; arterial blood gas analysis gave normal results. His chest radiograph (fig 1) and high resolution computed tomography (HRCT) are as shown in fig 2A and B.

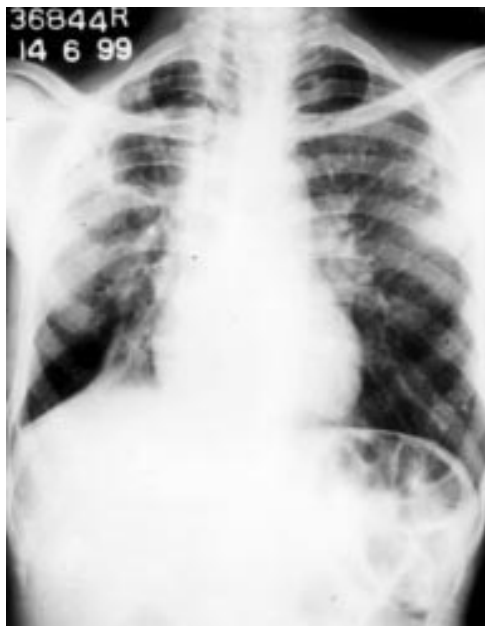

Figure 1 Chest radiograph showing right lower lobe collapse.

Questions

- (1) What are the findings on chest radiograph and HRCT?
- (2) What is the differential diagnosis and how is the diagnosis confirmed?
- (3) What is the treatment of this condition and what are the likely complications?

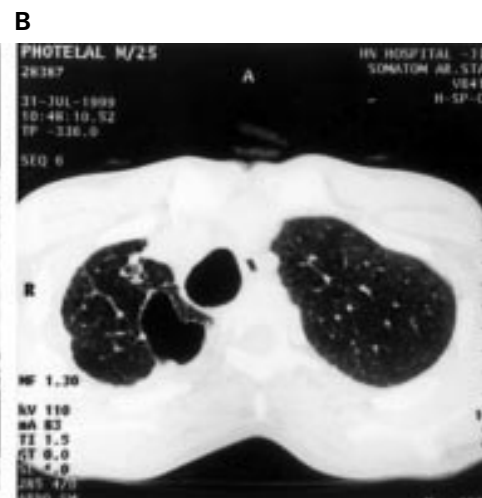
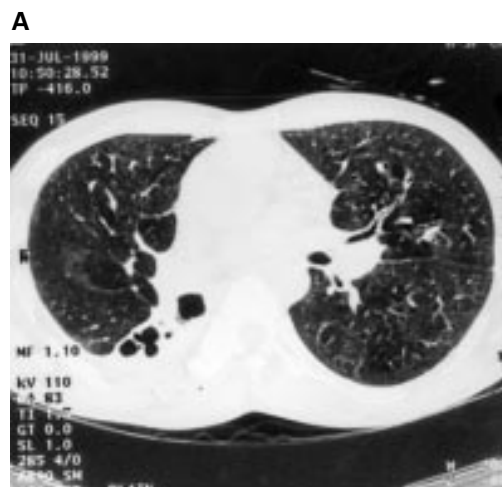


Figure 2 (A) HRCT showing right lower lobe collapse with bronchiectasis and (B) HRCT at the level of the trachea showing tracheomegaly.

Department of
Respiratory Medicine,
T N Medical College,
B Y L Nair Hospital,
Mumbai, 400 008 India
S Banerjee
P Sundaram
J M Joshi

Correspondence to:
Dr Joshi

Submitted 23 November
1999
Accepted 20 January 2000

A transient pleural effusion

M B Frenz

Answers on p 283.

A 29 year old Tanzanian man, resident in Great Britain for five years, presented complaining of persistent cough. He had been an insulin dependent diabetic for two years and was well controlled. A chest radiograph showed a moderate left pleural effusion (fig 1). He was followed up in clinic without further investigations and a repeat chest radiograph nine months later showed resolution of the effusion (fig 2). He returned five months later acutely unwell. He had lost 5 kg in the previous four weeks and had developed night sweats. Three days before

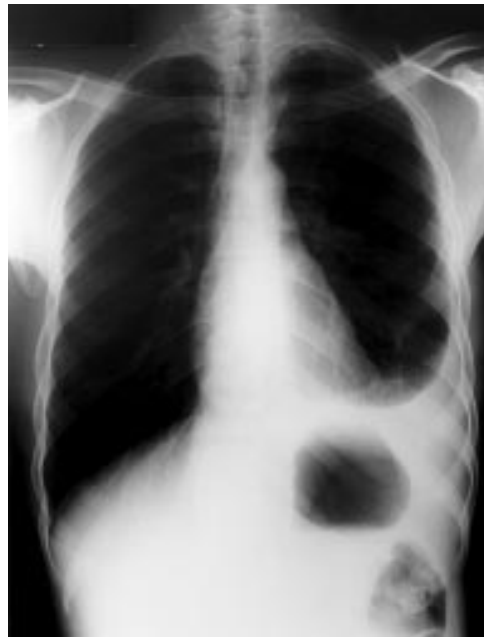

Figure 1 Chest radiograph taken at initial presentation.

admission he had developed severe headache and vomiting. On examination he was jaundiced, weak, and cachectic. His temperature was 38.7°C. Examination of the cardiovascular and respiratory systems were normal. His liver was enlarged 1 cm below the costal margin. There was no meningism, no papilloedema, and there were no focal neurological signs.

Questions

- (1) What are the possible causes of a spontaneously resolving pleural effusion?
- (2) Name one radiological and one diagnostic procedure that would help in making a diagnosis.
- (3) What is the most likely cause of his acute illness and how would you treat him?

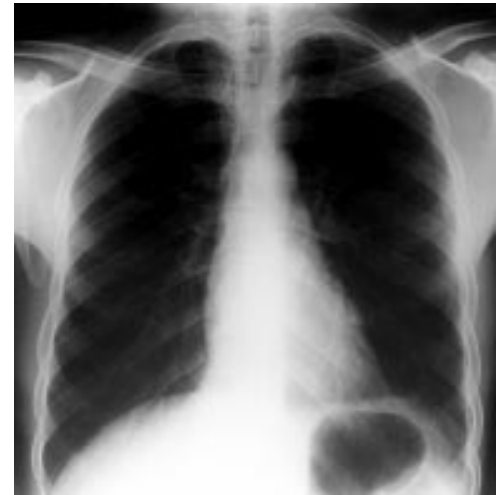

Figure 2 Chest radiograph nine months after initial presentation.

Milton Keynes General Hospital, Milton Keynes, Buckinghamshire, UK

Correspondence to:
Dr Markus B Frenz,
Wycombe Hospital, Queen
Alexandra Road, High
Wycombe, Bucks
HP11 2TT, UK
Mfrenz1107@aol.com

Submitted 21 July 1999
Accepted 20 January 2000

Answers on p 284.

A young woman with muscle weakness

N P Singh, S Anuradha, S K Agarwal

Department of Medicine, Maulana Azad Medical College and Associated Lok Nayak Hospital, New Delhi, India
N P Singh
S Anuradha
S K Agarwal

Correspondence to:
Dr N P Singh, DII/356,
Pandara Road, New Delhi
110003, India
nanu_singh@yahoo.com

Submitted 18 November 1999
Accepted 13 January 2000

A 28 year old woman presented with complaints of severe myalgias, muscle cramps and fatigue, of two weeks' duration. There was a history of pain and difficulty in rising from a squatting position and climbing up stairs. These symptoms, initially mild, had become exacerbated after the patient started cycling, which was advised by her physician because of her weight gain over the preceding year. There was no history of any muscle wasting, fasciculations, or any sensory involvement.

The patient had gained about 12 kg in weight over the last year. There was no history

of any orbital puffiness, oedema, hoarseness of voice, constipation, heat or cold intolerance, menstrual irregularities, urinary complaints, or drug intake. There were no other bone or joint related complaints, fever, alopecia, rash, photosensitivity, or Raynaud's phenomena.

Examination revealed an obese young woman (weight = 75 kg) with a pulse of 58 beats/min, regular, blood pressure 130/80 mm Hg, and pedal oedema. The chest, cardiovascular, and abdominal examinations were unremarkable. Muscle testing revealed a proximal muscle weakness (muscle power 3+/5) limited

to the pelvic girdle. There was diffuse tenderness over all the muscle groups of both the lower limbs. The deep tendon reflexes at the ankles were sluggish bilaterally. The rest of the neurological evaluation was normal.

Questions

- (1) What is the provisional diagnosis and how will you confirm it?
- (2) What are the causes of this condition?
- (3) What is the most probable aetiology in this patient and what further investigations would you order to document it?
- (4) The special laboratory investigations of the patient are summarised in the box. What is the final diagnosis?

Special laboratory investigations (normal laboratory range in parentheses)

- Thyroid stimulating hormone (TSH): 25 mU/l (0.3–7.0)
- Total triiodothyronine: 0.55 nmol/l (1.1–3.0)
- Total thyroxine: 13.5 nmol/l (51.5–167.3)
- Antimicrosomal antibody: 1:160² (positive)
(antithyroid peroxidase (TPO) antibodies: <1:10²)
- Antithyroglobulin antibody positive
- Lupus erythematosus cell, antinuclear antibody, rheumatoid factor, Venereal Disease Research Laboratory negative

SELF ASSESSMENT ANSWERS

Diagnostic issues in systemic lupus erythematosus

Q1: Which three tests would you ask for next from the clinic?

This patient had blood and protein in her urine on dipstick testing with a high systemic blood pressure. These findings should alert the clinician to the possibility of renal involvement. This is very common in SLE and may be associated with substantial morbidity and mortality. Careful monitoring of the urine for signs of lupus activity is an important part of the routine assessment of lupus patients. This includes *answer c*, that is analysis of the urine looking particularly for cellular casts. It would be important to measure the serum urea, electrolytes and creatinine, *answer f*, as well as quantification of the proteinuria with a 24 hour urine collection, *answer a*. The latter offers important information on the prognosis and the response to treatment.

Q2: What instructions do you give to a patient in order to perform a 24 hour urine protein collection?

The patient is asked to start the 24 hour urine collection on an empty bladder. So, for instance, if the patient were to first pass urine at 9 am in the morning, they would start the urine collection at this time. This first sample is discarded. The patient is then asked to empty any urine passed until 9 am the next morning into the bottle provided and then returned to the laboratory for examination. Incomplete 24 hour urine collections due to misunderstanding of instructions or forgetfulness are very common and will of course underestimate urine protein excretion. An alternative is the estimation of proteinuria by the albumin/creatinine ratio in a single early morning urine

specimen, thus avoiding the need for timed urine collection.

Q3: Can a 24 hour urine collection under/over estimate the glomerular filtration rate?

It should be noted that a 24 hour urine collection for creatinine clearance can overestimate the glomerular filtration rate (GFR). This is because creatinine is actively secreted by the renal tubules into the urine as well as being filtered by the glomerulus. Low muscle mass by reducing creatinine production will also tend to overestimate GFR by creatinine clearance.

Q4: What other tests (apart from 24 hour urine creatinine clearance) are available to measure the glomerular filtration rate?

More accurate determinations of GFR include radiolabelled chromium ⁵¹EDTA, MAG 3 renograms, and inulin clearance. Inulin clearance is an accurate determination of GFR but is never used in clinical practice nowadays as it is extremely tiresome from a practical viewpoint. A MAG 3 renogram can be used, but chromium ⁵¹EDTA is the most commonly used isotope in clinical practice.

Q5: What is the likely cause of this clinical picture and results?

The *answer is d*, SLE associated lupus nephritis. Most SLE patients who have renal involvement have deposits of immune complexes and complement in the glomerular mesangium. While such lesions may require no specific intervention, they may progress to more serious lesions. Glomerulonephritis in SLE is classified according to histological appearance using the WHO classification, which is as follows (stage and histological appearance):

- Stage I: normal
Stage II: mesangial

Stage III: focal proliferative glomerulonephritis
 Stage IV: diffuse proliferative glomerulonephritis
 Stage V: membranous glomerulonephritis
 Stage VI: diffuse sclerosis
 Other renal lesions in SLE include tubulointerstitial inflammation and lupus cystitis.

Q6: If this patient had persistently lowered complement levels from the time of her diagnosis, both during remission and relapses of her SLE, what other diagnosis would you have to consider?

Complement is an organised system of more than 20 serum proteins (synthesised predominantly in the liver) which helps to protect the host from invading organisms. While complement is important in host defence, activation of the complement system is detrimental to the host in a variety of diseases. In SLE, C3 and C4 levels are often performed clinically. Depressed C3 and C4 levels may indicate disease activity and tissue damage, for example glomerulonephritis. Patients with SLE whose complement proteins are within the normal range may fare better than those with persistent complement consumption. However, among SLE patients there is a higher than normal prevalence of null alleles for C4; serum C4 may therefore be persistently depressed when disease is inactive; in these patients C3 may be a better measure of disease activity. Inherited deficiencies of the early components of the classical complement pathway (C1, C2, C4) also interfere with the body's ability to handle immune complexes, which clinically results in an SLE-like condition.

Q7: Which investigation would you like to do next in order to obtain diagnostic and prognostic information regarding the cause of this woman's renal impairment?

A renal biopsy, *answer b*, would provide diagnostic and prognostic information. The various possible histological appearances have been discussed earlier. However, imaging of the kidneys before such a procedure is performed is important to confirm that there are two kidneys present. An ultrasound scan of the renal tract is the most commonly used imaging modality; it would also help to exclude coincidental scarring or obstruction, which are mandatory before renal biopsy.

Q8: What issues would you have to consider and counsel the patient for when gaining consent from a young woman for treatment with cyclophosphamide?

Although this patient was initially treated with pulsed corticosteroids, the additional use of cytotoxic agents has become the standard therapy for diffuse proliferative lupus nephritis. Azathioprine and cyclophosphamide are the most widely used immunosuppressive agents in this setting and their use is supported by several prospective trials. The most commonly used regimen is intravenous cyclophosphamide but it has never been proved in a prospective randomised control trial that cyclophosphamide

is definitely superior to azathioprine in this setting. A typical regimen uses monthly boluses of cyclophosphamide (at a dose of approximately 750 mg/m²) for six months or longer, followed by additional boluses every two or three months for a total of 2–3 years. A recent trial has shown that mycophenolate mofetil may be equally effective in the treatment of lupus nephritis.³

Cyclophosphamide is a cytotoxic drug which interferes with DNA synthesis by alkylating and cross linking DNA strands. Adverse effects include myelosuppression (white blood cells more than platelets), infections, and haemorrhagic cystitis. Mesna is given with pulses in order to prevent the latter complication.

Gonadal suppression and temporary or even permanent infertility occur, which is a serious issue in women of childbearing age. The risk of ovarian failure also rises with the age of the woman. Pregnancy tests should be performed before treatment is administered and the patient should be advised not to conceive during or for a few months after treatment because of the risks of teratogenicity. Egg collection before treatment can be offered, but drugs given to stimulate egg production before harvesting can also cause disease flare-ups.

Other side effects include nausea, vomiting, diarrhoea, pulmonary fibrosis, and rashes.

For further reading see Hughes¹ and Walport.²

We would like to acknowledge Dr David Davies, Consultant Pathologist at the John Radcliffe Hospital for providing the slide.

- 1 Hughes GRV. *Connective tissue diseases*. 3rd Ed. Oxford: Blackwell Scientific Publications, 1987. (Contains clinical review of all aspects of SLE.)
- 2 Walport MJ. Systemic lupus erythematosus. In: Lachmann PJ, Peters DK, Rosen FS, *et al*, eds. *Clinical aspects of immunology*. 5th Ed. Oxford: Blackwell Scientific Publications, 1993: 1161–204.
- 3 Chan TM, Li FK, Tang CS, *et al*. Efficacy of mycophenolate in patients with diffuse proliferative lupus nephritis. Hong Kong-Guangzhou Nephrology Study Group. *N Engl J Med* 2000;343:1156–62.

Optic disc oedema in first degree relatives with different macrovascular risk factors (type 1 diabetes and hypertension)

Q1: What are the diagnostic possibilities and what is the most likely diagnosis?

In case 1, the patient who presented with optic disc oedema, possibilities include disorders that cause optic disc swelling such as papillitis (demyelinating, diabetic), neuroretinitis (for example, cat scratch fever), toxoplasma infection, non-arteritic anterior ischaemic optic neuropathy (NAAION), toxic optic neuropathies, and neoplastic compression of the optic nerve. DIDMOAD (diabetes insipidus, diabetes mellitus, optic atrophy, deafness) syndrome is another condition which needs to be considered in any diabetic patient with optic atrophy. The diagnosis of NAAION was made after exclusion of other possible diagnoses. In case 2, though the patient did not present to the eye hospital until after the acute episode, the clinical picture and negative investigations

supported the same diagnosis as the first degree relative.

Q2: What are the risk factors for non-arteritic anterior ischaemic optic neuropathy?

Risk factors for NAAION include conditions predisposing to macrovascular disease (diabetes, smoking, hyperlipidaemia, and hypertension) and abnormal anatomy of the optic disc (known as “disc at risk”), which is described in detail in the discussion below.

Q3: What are the therapeutic options available for this condition?

The only effective therapeutic measure is prophylactic aspirin therapy to prevent the involvement of the second eye. However, as macrovascular risk factors have been found to be associated with this condition, it would be reasonable to treat any if they are present.

Discussion

NAAION is a frequent cause of visual loss in the adult population,¹ and is characterised by an acute loss of central visual acuity and visual field loss (usually inferior altitudinal). It is associated with swelling of the optic disc and flame shaped haemorrhages, either within the substance of the optic disc, or in the peripapillary retina. The cause is thought to be acute ischaemia of the most anterior part of the optic nerve head with occlusion of the posterior ciliary circulation. Risk factors for macrovascular disease, including diabetes mellitus, hypertension, hyperlipidaemia and smoking, are associated with NAAION,²⁻⁴ but in addition, certain anatomical features of the optic nerve head appear to be underlying predisposing factors. Cross sectional studies have observed that patients with NAAION have a smaller optic disc and a reduced cup to disc ratio,⁵ and it has also been suggested that increased branching of central retinal vessels within the disc may also predispose to NAAION.⁶ The cluster of all or some of these predisposing factors identifies a “disc at risk”. These abnormalities may provoke ischaemia secondary to overcrowding of axons as they pass through the lamina cribrosa.

Both patients had abnormal optic discs. The discs of case 1 (fig 1A, B, and C; see p 267) showed additional blood vessels and additional branches of main retinal blood vessels were also visible. In case 2, the optic discs (fig 2; see p 267) had no physiological cup in either eye. Extra branches and abnormal branching of the main retinal vessels could also be observed. Each of the patients had different macrovascular risk factors and also had features of “disc at risk”. The observation of abnormal anatomical features of the optic disc in two generations of the same family suggests that the “disc at risk” may be an inherited characteristic, which is the principal predisposing factor to NAAION. NAAION has been reported previously to occur in siblings⁷⁻⁹ and in twins,⁸ in whom it was associated with a reduced cup to disc ratio. The present cases further support the possibility that these anatomical abnormalities of

Learning points

- NAAION is a cause of visual loss associated with oedema of the optic disc.
- Macrovascular risk factors are associated with the development of this condition.
- A diagnosis of NAAION should be considered when patients present with papilloedema and visual loss.
- Increased awareness of this condition is required by doctors screening diabetic patients for eye complications of diabetes.

the optic disc may be inherited. If this is so, recognition of a “disc at risk” before the onset of NAAION may allow the introduction of prophylactic treatment to try to prevent the onset of this disease. Though NAAION has been associated with an increased prevalence and mortality from cardiovascular and cerebrovascular disease,² the only beneficial therapy is treatment with aspirin, reducing the risk of NAAION in the non-affected eye.¹⁰ There may be a case for screening family members of affected patients and treating them prophylactically with aspirin. In addition, any identifiable macrovascular risk factors should be treated.

In diabetic patients, this condition can be confused with diabetic papillitis, which is a relatively benign condition with a good prognosis. It is important to consider this condition when patients present with unilateral disc oedema and visual loss, and particularly if they have any macrovascular risk factors. Although NAAION is familiar to ophthalmologists, an awareness of this condition needs to be increased among physicians in order to avoid unnecessary investigations and diagnostic confusion. In particular, it is important that doctors or optometrists who screen diabetic patients for eye complications are aware of its existence.

Final diagnosis

Non-arteritic anterior ischaemic optic neuropathy.

- 1 Johnson LN, Arnold AC. Incidence of nonarteritic anterior ischemic optic neuropathy: population-based study in the state of Missouri and Los Angeles County, California. *J Neuro-Ophthalmol* 1994;**14**:38-44.
- 2 Hayreh SS, Joos KM, Podhajsky PA, et al. Systemic diseases associated with nonarteritic anterior ischemic optic neuropathy. *Am J Ophthalmol* 1994;**118**:766-80.
- 3 Chung SM, Gay CA, McRay JA. Nonarteritic ischemic optic neuropathy: the impact of tobacco use. *Ophthalmology* 1994;**101**:779-82.
- 4 Guiffre G. Hematological risk factors for anterior ischemic neuropathy. *J Neuro-Ophthalmol* 1990;**10**:197-203.
- 5 Beck RW, Servais GE, Hayreh SS. Anterior ischemic optic neuropathy IX. Cup-to-disc ratio and its role in pathogenesis. *Ophthalmology* 1987;**94**:1503-8.
- 6 Burde RM. Optic disc risk factors for nonarteritic anterior ischemic optic neuropathy. *Am J Ophthalmol* 1993;**116**:759-63.
- 7 Berggren L, Thorburn W, Fodstad H. Three cases of non-inflammatory ischaemic optic neuropathy occurring in the same family. *Acta Ophthalmol* 1974;**52**:589-95.
- 8 Manor RS. Nonarteritic ischemic optic neuropathy in identical female twins: improvement of visual outcome in one by optic nerve decompression. *Arch Ophthalmol* 1990;**108**:1067-8.
- 9 Deutsh D, Eting E, Avisar R, et al. Familial anterior ischemic optic neuropathy and papillophlebitis. *Am J Ophthalmol* 1990;**110**:306-8.

10 Kupersmith MJ, Frohman L, Sanderson M, *et al*. Aspirin reduces the incidence of second eye NAION: a retrospective study. *J Neuro-Ophthalmol* 1997;17:250–3.

An unusual palmoplantar pigmentation

Q1: What is your diagnosis?

The diagnosis is alkaptonuria. The patient had scleral pigmentation with an unusual palmoplantar pigmentation and joint involvement.

Q2: What are the bedside tests by which you can confirm your diagnosis?

The following are the simple bedside tests which can be useful in diagnosis:

Alkali test: addition of few drops of alkali such as sodium hydroxide or potassium hydroxide darkens the urine.

Photographic paper test: application of a drop of alkaptonuric urine over photographic paper followed by the addition of few drops of sodium hydroxide leads to a black spot on the photographic paper.

“Black” Benedict’s test: when urine is added to Benedict’s reagent, it produces a black coloured ring.

Ferric chloride test: addition of ferric chloride to the patient’s urine produces black colour.

Q3: What are the complications of this disease?

Complications are listed in box 1.

Box 1: Complications of alkaptonuria

Musculoskeletal

- Arthritis.
- Kyphosis.
- Sciatica.
- Disc calcification and collapse.
- Ochronotic arthropathy.
- Pseudogout.

Cardiovascular

- Atherosclerosis.
- Valvular stenosis.

Calculi

- Prostatic calculi.
- Pigmented renal calculi.

Others

- Deafness.

Discussion

Alkaptonuria is the first human disease shown to be inherited as an autosomal recessive trait and is due to the absence of the enzyme homogentisic acid oxidase (HGAO) in the liver and kidneys.¹ Affected homozygotes occur with a frequency of around one in 200 000.² HGAO helps in the degradation of phenylalanine and tyrosine. Homogentisic acid (HGA) is an intermediate of this pathway and blockade in conversion of HGA to maleyl acetoacetic acid results in accumulation of excessive amounts of HGA in the body. This in return is deposited in various connective tissues (ochronosis) and subsequently undergoes oxidation and polymerisation.³

Alkaptonuria is asymptomatic in childhood and the only sign present in some instances is

the dark staining of nappies (diapers). However, the later external manifestations include greyish blue discoloration of the sclera and the cartilage of the external ear. The cutaneous manifestation in the form of fine speckled blue black discoloration occurs mainly in the sun exposed areas while greenish blue pigmentation occurs in regions of high sweat gland density. The most disturbing and disabling manifestation of alkaptonuria is the insidious gradually progressive ochronotic arthropathy, which generally begins in the third and fourth decade in males and about 10 years later in females. Pigmentation of the heart valves, aorta, genitourinary tract, laryngeal, tracheal, and bronchial cartilages has also been described.^{3,4}

The diagnosis is usually made from the triad of degenerative arthritis, ochronotic pigmentation, and urine that turns black upon alkalinitation.² Histopathological examination of the skin lesion showing homogenised thickened ochronotic pigment in the upper dermal collagen further confirms the diagnosis of alkaptonuria.³

Treatment is mostly symptomatic; ascorbic acid may be helpful.⁵

The unique feature of this case is the palmoplantar pigmentation, which is exceedingly rare.

Final diagnosis

Alkaptonuria.

- 1 Fernandez-Canon JM, Granadino B, Beltran-Valero de Bernabe D, *et al*. The molecular basis of alkaptonuria. *Nat Genet* 1996;14:19–24.
- 2 Elsas LJ, Longo N, Rosenberg LE. Inherited disorders of aminoacid metabolism and storage. In: Fauci AS, Braunwald E, Isselbacher KJ, *et al*, eds. *Harrison’s principles of internal medicine*. 14th Ed. New York: McGraw-Hill, 1998: 2201.
- 3 Albers SE, Brozena SJ, Glass LF, *et al*. Alkaptonuria and ochronosis: case report and review. *J Am Acad Dermatol* 1992;27:609–14.
- 4 Micali G, Di Stefano AG, Nasca MR, *et al*. A 46-year-old man with a 4-year history of diffuse brownish black pigmentation. Endogenous ochronosis (alkaptonuria). *Arch Dermatol* 1998;134:100–1.
- 5 Pradeep JK, Kehinde FO, Daar AS. Symptomatic response to ascorbic acid. *Br J Urol* 1996;77:319–20.

An unusual cause of tremor in an elderly man

Q1: What is the probable diagnosis?

The lumbar spine radiograph shows sclerotic lesions involving the lower lumbar vertebrae. The aspirate shows that the bone marrow is densely populated by clumps of neoplastic cells. The normal haemopoietic cells are almost totally replaced by tumour cells. Neoplastic cells are usually larger than normal haemopoietic cells other than the megakaryocytes, and they are pleomorphic with regards to size, shape, and nuclear characteristic. They are commonly cohesive and therefore occur as tight clumps.^{1,2} It is usually not possible to predict the tissue of origin from the cytological features of the neoplastic cells in smears of bone marrow aspirates. A provisional diagnosis of metastatic prostatic carcinoma was made based on the presence of an enlarged prostate

on clinical examination, osteosclerotic lesions, and neoplastic cells in the bone marrow.

Q2: What other investigations should be done to confirm the diagnosis?

The metastatic tumour cells in the marrow biopsy specimen were positive for prostate specific antigen using immunohistochemistry technique that employed monoclonal antibodies. Computed tomography of the abdomen and pelvis showed an irregular thick walled prostate and enlarged lymph nodes in the para-aortic and pelvic regions. The patient did not consent to a transurethral prostatic biopsy. The serum prostate specific antigen (PSA) level was markedly raised at 120 µg/l. PSA has generally replaced acid phosphatase for the diagnosis and monitoring of prostatic carcinoma as it has greater sensitivity (especially for early invasive carcinoma) and specificity. Marked elevation is indicative of carcinoma, but concentrations are also increased in prostatitis, prostatic ischaemia or infarction, benign prostatic hypertrophy, and acute renal failure. Normal concentrations do not exclude prostatic carcinoma.

Q3: What are the possible causes of the tremor in this patient?

The principal differential diagnoses of a tremor in an elderly man include Parkinson's disease, essential tremor, lesions in the midbrain, cerebellar lesions, endocrine-metabolic diseases such as thyrotoxicosis and hypoglycaemia, and drugs (such as β-agonists, dopamine agonists, alcohol withdrawal, and tricyclic antidepressants). Like all neurological diseases, the single most important step in the diagnostic process is the identification of the site of the lesion. This is almost always possible through a detailed history and thorough physical examination. The physician must be able to characterise the tremor in terms of its site, approximate frequency, amplitude and amplification or reduction in three different positions (rest, posturing of the arms, and during finger-nose testing). Of these features, the latter is the most useful. A tremor, which is present in all three positions, points to a lesion in the superior cerebellar peduncle in the midbrain, near the red nucleus (thus the term "rubral" tremor). Rubral tremors are present at rest, and are typically enhanced by posturing of the arms and more so, by goal directed movements. Parkinsonian tremors, however, abate with movement. Given the presence of titubation, essential tremor and a cerebellar lesion are also possible diagnoses.³ There were, however, no signs of cerebellar dysfunction, and essential tremors do not usually present acutely. The next step in the diagnostic process is to ascertain the nature of the lesion. Given his age and the acute onset of tremors, a midbrain stroke has to be considered first. Computed tomography of the brain did not reveal an infarct or haemorrhage in the midbrain, but the detection of the former is better on magnetic resonance imaging. Given the diagnosis of prostatic cancer, a metastatic midbrain tumour is a possibility, but the history was too rapid, and

Learning points

- Carcinoma of the prostate is a common cause of bone marrow infiltration leading to pancytopenia in an elderly man.
- The absence of symptoms of prostatism does not exclude diseases of the prostate.
- Bone marrow examination is a simple and useful diagnostic tool in the diagnosis of non-haematological malignancies infiltrating the bone marrow.
- The most important step in the diagnosis of tremor is characterisation of the tremor in three different positions.
- Tremor may be the first presentation of paraneoplastic syndrome.

the brain computed tomography essentially excluded this. The most likely diagnosis is a paraneoplastic syndrome. The fact that the patient's tremors abated after radiotherapy and hormonal treatment and not after medication (clonazepam and later, primidone) is strong evidence for this.³

Discussion

We have demonstrated that this patient had disseminated prostatic cancer. The resolution of the patient's tremor after cancer treatment strongly supports the diagnosis of paraneoplastic syndrome. Small cell lung and ovarian cancers have the highest frequency of paraneoplastic syndromes, although theoretically, any cancer can cause paraneoplastic syndromes.⁴ The onset of neurological paraneoplastic syndromes is usually acute or subacute. Although tremor alone has never been described as being a paraneoplastic syndrome, tremor as part of subacute cerebellar degeneration and brain stem encephalitis has.^{4,5} These syndromes, however, typically occur with small cell lung cancer, and tremor is not a major feature. The initial symptoms in these syndromes are gait ataxia, dysarthria, diplopia, vertigo, and oscillopsia.⁴ The pathogenesis of these syndromes is poorly understood, but may be related to circulating anti-Yo (cerebellar degeneration) and anti-Hu (brain stem encephalitis) autoantibodies.^{4,5} The most likely site of the lesion in the present case is the superior cerebellar peduncle, presumably due to autoantibodies directed to the midbrain.

Final diagnosis

Disseminated prostatic carcinoma with a paraneoplastic neurological syndrome.

- 1 Singh G, Krause JR, Breitfeld V. Bone marrow examination for metastatic tumour. *Cancer* 1977;40:2317–21.
- 2 Tritz DB, Doll DC, Ringerberg S, et al. Bone marrow involvement in small cell lung cancer. *Cancer* 1989;63:763–6.
- 3 Lang AE. Movement disorder symptomatology. In: Bradley WG, Daroff RB, Fenichel GM, et al, eds. *Neurology in clinical practice: principles of diagnosis and management*. Boston: Butterworth-Heinemann, 1996: 299–320.
- 4 Posner JB. Paraneoplastic syndromes. In: Bradley WG, Daroff RB, Fenichel GM, et al, eds. *Neurology in clinical practice: principles of diagnosis and management*. Boston: Butterworth-Heinemann, 1996: 1165–72.
- 5 Dalnau JO, Posner JB. Paraneoplastic syndromes affecting the nervous system. *Semin Oncol* 1997;24:318–28.

A 35 year man with acromegaly and neck stiffness

Q1: What is the diagnosis?

The diagnosis is pituitary apoplexy. This is abrupt destruction of pituitary tissue resulting from infarction or haemorrhage into the pituitary, usually into an undiagnosed tumour.¹ Common predisposing factors are listed in box 1.

Clinically pituitary apoplexy presentation may vary from asymptomatic “silent” pituitary apoplexy to catastrophic endocrine emergency with blindness, coma, and haemodynamic instability. Clinical features are outlined in box 2.

Numerous endocrinopathies both transient and permanent, may result from pituitary apoplexy. Partial or complete hypofunctioning of the pituitary appears to be the rule (see box 3).

Q2: What are the two most critical alternative diagnoses?

Two most critical alternative diagnoses in this patient are aneurysmal SAH and bacterial meningitis. Pituitary apoplexy in its most classic presentation may mimic SAH. Both present with sudden onset of severe headache, impaired consciousness, and meningeal signs. Similarly both may have sentinel headache, although the interval between the onset of headache and development of mental status changes tends to be shorter in SAH. Bilateral third cranial nerve paresis favours pituitary apoplexy; unilateral deficits may be seen in both.

Differentiating between pituitary apoplexy and bacterial meningitis may likewise be difficult because meningeal signs, altered mental status, fever, and headache are features of both. Ophthalmological findings or hemiparesis, if present, favour the diagnosis of pituitary apoplexy.

Box 1: Pituitary apoplexy—predisposing causes²

- Haemorrhagic infarction of a pituitary tumour.
- After obstetric haemorrhage.
- Diabetes mellitus and diabetic ketoacidosis.
- Radiation therapy.
- Anticoagulant therapy.
- Bleeding disorders.
- Head trauma.
- Raised intracranial pressure.
- Drugs: bromocriptine, clomiphene, thyrotrophin releasing hormone, triple bolus test, gonadotrophin releasing hormone, luteinising hormone releasing hormone analogue (goserelin), isosorbide, chlorpromazine, oestrogens.
- Carotid angiography and pneumoencephalography.
- Mechanical ventilation.
- Cardiac surgery, lumbar laminectomy, haemodialysis.

Box 2: Pituitary apoplexy—clinical features

- Headache: retro-orbital, frontal, or diffuse.
- Visual impairment: decreased visual acuity, visual field defects (most commonly bitemporal hemianopia, optic atrophy leading to blindness).
- Ophthalmoplegia: III, IV, VI nerve paresis.
- Facial pain and loss of corneal reflex: due to ophthalmic V nerve involvement.
- Nausea, vomiting: due to meningism or raised intracranial pressure.
- Meningism: due to blood or necrotic tumour in subarachnoid space.
- Altered mentation, ranging from mild lethargy to coma.
- Hemiparesis and seizures: due to entrapment of the internal carotid artery in cavernous sinus or vasospasm due to subarachnoid haemorrhage (SAH).
- Anosmia: due to olfactory nerve compression.
- Epistaxis and cerebrospinal fluid rhinorrhoea: because of erosion of haemorrhage through sphenoid sinus into the nasal cavity.
- Proptosis and eyelid oedema: caused by cavernous sinus obliteration.
- Hypothalamic compression: disturbed sympathetic autoregulation leading to abnormalities in thermoregulation, respiration, blood pressure, and cardiac rhythm.
- Fever.

Box 3: Pituitary apoplexy—endocrinopathies³

- Hypogonadism: 100%
- Growth hormone deficiency: 88%
- Hyperprolactinaemia: 67%
- Acute adrenal insufficiency: 66%
- Hypothyroidism: 42%
- Diabetes insipidus: 3%

Mid-brain infarction (basilar artery occlusion) and cavernous sinus thrombosis, although less common, also may need exclusion.

Q3: What is the role of lumbar puncture in this patient?

Lumbar puncture is an unreliable means of differentiating pituitary apoplexy from SAH, since high red cell count and xanthochromia may sometimes be seen in pituitary apoplexy. Pleocytosis and raised cerebrospinal fluid proteins are common to both bacterial meningitis and pituitary apoplexy, and do not provide much assistance in distinguishing between them. Moreover in suspected pituitary apoplexy lumbar puncture may be dangerous, because it may precipitate uncal herniation. Computed tomography and magnetic resonance imaging are most likely to be helpful by

Box 4: Neuroimaging in pituitary apoplexy⁵

Computed tomography

- Computed tomography of the head is most useful in the acute setting (24–48 hours).
- 1.5 mm thin sections in coronal plane through pituitary fossa with intravenous contrast are highly sensitive.
- High density or inhomogeneous gland, with or without evidence of subarachnoid blood ring enhancement or a high density fluid level, may be seen.

Magnetic resonance imaging

- Acute haemorrhage (<7 days): hypointense or isointense to brain on T1 and T2 weighted images.
- Subacute stage (7–14 days) increased intensity in periphery of the haematoma (owing to haemoglobin breakdown products such as methaemoglobin), with centre remaining hypointense.
- Chronic stage (>14 days) entire haematoma appears bright on T1 and T2 images.

demonstrating a sellar mass even if evidence of acute haemorrhage is not obvious (see box 4).⁴

Follow up

The patient was managed with intravenous hydrocortisone and other supportive measures. Emergency transsphenoidal removal of a necrotic and haemorrhagic pituitary macroadenoma was done. Immunohistochemistry revealed growth hormone secreting adenoma. He made a rapid symptomatic recovery and features of meningism subsided over the next two days. Further endocrinological evaluation is planned to determine the nature and degree of hormone deficits.

Final diagnosis

Pituitary apoplexy.

- 1 Vance ML. Hypopituitarism. *N Engl J Med* 1994;330:1651–62.
- 2 Reid RL, Quigley ME, Yen SSC. Pituitary apoplexy. *Arch Neurol* 1985;42:712–19.
- 3 Veldhuis JD, Hammond JM. Endocrine function after spontaneous infarction of the human pituitary: report, review and reappraisal. *Endocr Rev* 1980;1:100–7.
- 4 Rolih CA, Ober KP. Pituitary apoplexy. *Endocrinol Metab Clin North Am* 1993;22:291–302.
- 5 Ostrov SG, Quencer RM, Hoffman JC, et al. Hemorrhage within pituitary adenomas: how often associated with pituitary apoplexy syndrome? *Am J Roentgenol* 1989;153:153–60.

Joint pains, hoarseness, and deafness

Q1: What is the most likely diagnosis and the differential diagnosis?

The most likely diagnosis is relapsing poly-chondritis. The combination of joint pains, saddle nose deformity and hoarseness of the voice, suggesting laryngeal or tracheal involvement, makes the diagnosis of relapsing poly-chondritis the most likely. The other possible

differential diagnoses are listed in box 1. The causes of saddle nose deformity are listed in box 2.

Box 1: Differential diagnoses

- Wegener's granulomatosis.
- Polyarteritis nodosa.
- Takayasu's arteritis.
- Giant cell arteritis.
- Rheumatoid arthritis.
- Rheumatic fever.
- Sarcoidosis.
- Malignancy.
- Systemic lupus erythematosus.

Box 2: Causes of saddle nose deformity

- Relapsing polychondritis.
- Wegener's granulomatosis.
- Trauma.
- Congenital syphilis.
- Intranasal cocaine use.
- Rheumatoid arthritis.
- Racial/inherited.
- Ectodermal dysplasia.
- Down's syndrome.
- Leprosy.

Q2: What further investigations should be performed?

Further investigations should include laryngoscopy and bronchoscopy to define the extent of laryngotracheal involvement. Computed tomography of the upper airway is a useful investigation¹ and to a lesser extent pulmonary function tests. Serum antineutrophil cytoplasmic antibody should be checked to exclude the possibility of Wegener's granulomatosis. Tissue diagnosis can be confirmed by a biopsy specimen in patients with auricular chondritis but is not essential.²

Q3: How would you treat this condition?

Mild episodes of auricular and nasal chondritis and seronegative arthritis usually respond to non-steroidal inflammatory drugs with or without a low dosage of corticosteroid. More serious manifestations such as airway involvement, as in this patient, require high dose prednisolone and often cytotoxic drugs are needed.

Discussion

Relapsing polychondritis is an episodic systemic disorder characterised by recurrent widespread destruction involving cartilaginous structures. Attacks tend to vary in severity and duration usually lasting for days to weeks before resolving spontaneously. Presenting symptoms are most frequently auricular chondritis (90%), polyarthritis (80%), nasal chondritis (60%), ocular involvement (50%), and respiratory tract involvement (55%).² Respiratory involvement is the most serious manifestation of relapsing polychondritis. Oedema, stenosis, and collapse and disintegration of the cartilage results in tracheobronchial chondritis

and subglottic stenosis causing collapse of the trachea and bronchi, pulmonary infections, and even asphyxia.³ Computed tomography is useful in assessing the respiratory involvement of the disease.¹ Nasal chondritis develops often and repeated attacks may cause cartilage collapse with characteristic saddle nose deformity. Such changes may appear in the absence of clinically evident inflammation.⁴ Cardiovascular manifestations include systemic and central nervous system arteritis, aortic aneurysm, and valvular insufficiency. The auricle is classically painful and the commonest site of involvement.⁴ In addition the middle ear may be involved with eustachian tube dysfunction and collapse resulting in otitis media. The auditory-vestibular apparatus may be involved, resulting in sensorineural deafness. This is thought to be due to arteritis involving the internal auditory artery and is the likely cause of deafness in this patient.⁵ Approximately 25% of cases have coexistent diseases especially autoimmune diseases, systemic sclerosis, systemic lupus erythematosus, rheumatoid arthritis, Sjögren's syndrome, thyroid disease, ulcerative colitis, and Wegener's granulomatosis.⁴ No specific laboratory test exists for relapsing polychondritis and findings are often non-specific: raised erythrocyte sedimentation rate, leukocytosis, anaemia, raised antistreptolysin-O titres, and occasionally positive rheumatoid factor or antinuclear factor.⁴ Detection of autoantibodies to type II collagen present in cartilage and sclera, and cell mediated immunity to cartilage components in patients with relapsing polychondritis, suggest an autoimmune aetiology.⁶ Histology of affected tissues shows perichondrial inflammation, with loss of basophilic staining of a cartilage matrix and areas of cartilage destruction with replacement of fibrous tissues.⁷ The natural history is unpredictable and may have an episodic, smouldering, or a fulminant course.⁴ Mortality is usually secondary from respiratory complications such as airway collapse or pneumonia, aneurysm rupture, valvular heart disease, or vasculitis. Infective complications or malignancy from immunosuppressive drugs may occur. Most severe cases require steroids or immunosuppressant drugs.

Final diagnosis

Relapsing polychondritis.

- 1 Port JL, Khan A, Barbu RR. Computed tomography of relapsing polychondritis. *Comput Med Imaging Graph* 1993;17:119-23.
- 2 Damiani JM, Leveine HL. Relapsing polychondritis—report of ten cases. *Laryngoscope* 1979;89:929-46.
- 3 Eng J, Sabanathan S. Airway complications in relapsing polychondritis. *Ann Thorac Surg* 1991;51:686-92.
- 4 Herman J. Polychondritis. In: Kelley WN, Harris ED Jr, Ruddy S, et al, eds. *Textbook of rheumatology*. 4th Ed. Philadelphia: WB Saunders, 1993: 1400-11.
- 5 Cody DTR, Sones DA. Relapsing polychondritis: audiovestibular manifestations. *Laryngoscope* 1971;81:1208.
- 6 Fiodart JM, Abe S, Martin GR, et al. Antibodies to type II collagen in relapsing polychondritis. *N Engl J Med* 1978;229:1203-7.
- 7 Verity MA, Larson WM, Madden SC. Relapsing polychondritis: report of two necropsied cases with histochemical investigations of the cartilage lesions. *Am J Pathol* 1963;42:251.

Helicobacter heilmannii

Q1: What is *Helicobacter heilmannii*?

Helicobacter heilmannii was first described in 1987 as a Gram negative urease producing tightly coiled bacillus, morphologically distinct to *Helicobacter pylori* and labelled *Gastrospillum hominis*.¹ It has been reclassified as a non-pylori *Helicobacter* spp and found to have a 90% homology in the 16s RNA nucleotide sequence to *H pylori*.² Following the description of a large series of patients by a German pathologist in 1991 the organism has been renamed *H heilmannii*.³ It is now recognised as the commonest non-pylori species in humans with an average incidence in a civilised human population of 0.3%.³ Culture of this bacillus is difficult and its method of detection varies world wide and as such its prevalence varies geographically.⁴ *H heilmannii* shows little variation but reported numbers in clinical series are small.² It bears a close genotypic profile to *Helicobacter felis*, which is usually found in the gastric mucosa of cats and dogs, and this has prompted theories of zoonotic transmission. Seventy per cent of patients with *H heilmannii* infection have contact with pets.⁵

Q2: What does it do?

H heilmannii has been shown to cause a neutrophilic inflammatory response in the gastric mucosa and in some reports mucosal atrophy, metaplasia, and dysplasia. The degree of inflammation seen is to a lesser extent than that seen with *H pylori*. There have been suggestions of a synergistic relationship with *H pylori*, although other studies show a protective effect of *H heilmannii* against *H pylori*.^{6 7}

Q3: What is the clinical significance?

Heilman in 1991 showed an association between infection and gastrointestinal disease in humans.² Further reports support an association with predominantly superficial gastritis.^{2 7} There are a few case reports of an association with peptic ulcer disease and gastric cancer.^{2 8}

Q4: Does it require treatment?

H heilmannii has been shown to spontaneously disappear together with total resolution of inflammatory change.^{2 7} However, chronicity has been described and there is evidence to suggest susceptibility to *H pylori* eradication therapy.^{2 8} Whether it is a true pathogen remains an open question.

In this case, as the man was symptomatic, it was decided to treat him with *H pylori* eradication therapy and to continue on a proton pump inhibitor. He became asymptomatic after the initial eradication treatment and is now in the process of stopping all treatment.

- 1 Dent JC, McNulty CAM, Uff JC, et al. Spiral organisms in the gastric antrum. *Lancet* 1987;ii:96.
- 2 Kusters JG, Kuipers EJ. Non-pylori helicobacter infections in humans. *Eur J Gastroenterol Hepatol* 1998;10:239-40.
- 3 Heilman KL, Borchard F. Gastritis due to spiral shaped bacteria other than *Helicobacter pylori*: clinical, histological and ultrastructural findings. *Gut* 1991;32:137-40.
- 4 Hazell SL. Isolation of *Helicobacter heilmannii* from human tissues. *Eur J Clin Microbiol Infect Dis* 1996;15:4-9.

- 5 Stolte M, Wellens E, Bethke B, *et al.* Helicobacter heilmannii (formerly Gastrospirillum hominis) gastritis; an infection transmitted by animals? *Scand J Gastroenterol* 1994;29:1061-4.
- 6 Yali Z, Yamada N, Wen M, *et al.* Gastrospirillum hominis and Helicobacter pylori infection in Thai individuals. Comparison of histopathological changes of gastric mucosa. *Pathol Int* 1998;48:507-11.
- 7 Debonnie JC, Donnay M, Mairesse J. Gastrospirillum hominis (Helicobacter heilmannii): a cause of gastritis sometimes transient, better diagnosed by touch cytology? *Am J Gastroenterol* 1995;90:411-15.
- 8 Goddard AF, Logan RPH, Atherton JC, *et al.* Healing of a duodenal ulcer after eradication of Helicobacter heilmannii. *Lancet* 1997;349:1815-16.

Chronic pulmonary suppuration

Q1: What are the findings on chest radiograph and HRCT? (see p 272)

The chest radiograph and HRCT show collapse of the right lower lobe with areas of cavitation and bronchiectasis. Areas of fibrosis due to old infection are seen in anterior and posterior segments of the left upper lobe. There is an increase in the tracheal diameter suggestive of tracheomegaly.

Q2: What is the differential diagnosis and how is the diagnosis confirmed?

The differential diagnoses to be considered in a patient with chronic pulmonary suppurative symptoms include bronchiectasis, lung abscess, and cystic fibrosis. The causes of bronchiectasis can be congenital or acquired¹ as shown in box 1.

On computed tomography the coronal diameter of the trachea measured 28 mm in our case and confirmed the diagnosis of tracheobronchomegaly. Three dimensional virtual reconstruction technique (3DVRT) (fig 3) further showed dilatation of the trachea and the right main bronchus. Bronchoscopy showed presence of excessive collapsibility of the trachea suggestive of tracheomalacia.

Q3: What is the treatment of this condition and what are the likely complications?

Treatment of tracheobronchomegaly is aimed at minimising damage resulting from stasis of secretions and infections and consists of

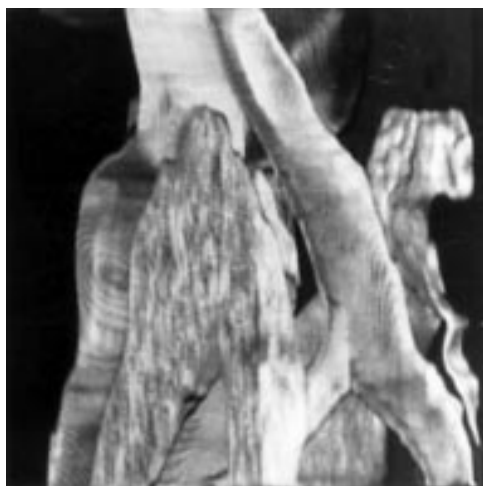

Figure 3 3DVRT showing dilatation of the trachea and right main bronchus.

Box 1: Causes of bronchiectasis

Congenital causes

- Structural defects—for example, tracheobronchomegaly, bronchomalacia, pulmonary sequestration.
- Ciliary defects—for example, Kartagener's syndrome, Young's syndrome.
- Immunodeficiency syndromes.
- Metabolic defects—for example, cystic fibrosis, α_1 -antitrypsin deficiency.

Acquired causes

- Infections in childhood.
- Secondary due to bronchial obstruction due to a tumour or foreign body or hilar glands causing bronchial obstruction.
- Associated disorders of immunity—for example, autoimmune diseases.
- Bronchopulmonary aspergillosis.

postural drainage and antibiotics. Occasionally tracheobronchomegaly may progress to extensive tracheomalacia due to softening of supporting cartilages, as in our case. In some severe cases the trachea becomes distorted and permanently narrowed resulting in diffuse tracheal stenosis and respiratory failure occurs.² Nasal continuous positive airway pressure provides optimal splinting of the airways to prevent dynamic collapse caused by tracheomalacia. Expanding wire shunts or Y stents have been used in adults with tracheomalacia with good results.²

Discussion

Tracheobronchomegaly is a distinctive, clinico-radiological condition consisting of marked dilatation of the trachea and major bronchi associated with chronic respiratory tract infection and bronchiectasis. The syndrome is rare and often begins in childhood, although it is frequently diagnosed in the fourth or fifth decade, and is thought to be due to a congenital defect of the elastic and muscle fibres of the tracheobronchial tree.^{3,4} A familial form with a possible autosomal recessive inheritance has been reported.⁵ Acquired forms of tracheobronchomegaly may occur as a complication of diffuse pulmonary fibrosis, due to mechanical ventilation in preterm infants or in congenital immunoglobulin deficiency.^{3,6} However, the degree of tracheal dilatation seen with diffuse pulmonary fibrosis is usually mild,⁶ and diverticula formation seen in the congenital form is not seen in the acquired form of tracheobronchomegaly.

Clinical symptoms range from asymptomatic to symptoms indistinguishable from those caused by chronic bronchitis or bronchiectasis. Stridor or respiratory failure may suggest associated tracheomalacia or tracheal stenosis. The diagnosis of tracheobronchomegaly may be missed unless specifically looked for. Hence the routine measurement of tracheal diameter on chest radiographs and computed tomograms in cases of chronic pulmonary suppuration is

Learning points

- Tracheobronchomegaly is a rare cause of chronic pulmonary suppuration.
- Tracheobronchomegaly can be of congenital or acquired aetiology.
- Computed tomography measurement of coronal diameter of trachea greater than 18.2 + 3SD (1SD=1.2 mm), in males, 15.2 + 3SD (1SD= 1.4 mm) in females is diagnostic of tracheobronchomegaly.
- Tracheomalacia with respiratory failure is a life threatening complication.
- Treatment consists of postural drainage, antibiotics, and nasal continuous positive airway pressure or tracheal splints for associated tracheomalacia.

worthwhile. Tracheobronchomegaly is defined by an increase in transverse diameter of the trachea and mainstem bronchi of 3SDs or greater. The mean (SD) tracheal diameter on computed tomography is 18.2 (1.2) mm in males and 15.2 (1.4) mm in females.⁷ The diagnosis of tracheobronchomegaly can also be confirmed by bronchography, computed tomography, virtual bronchoscopy, and magnetic resonance imaging. Demonstration of excessive collapsibility of the trachea on expiration by flow volume loop, fluoroscopy, and bronchoscopy confirms associated tracheomalacia.

Final diagnosis

Tracheobronchomegaly (Mounier-Kuhn syndrome) with tracheomalacia.

- 1 Seaton A, Seaton D, Leitch AG. Bronchiectasis. *Crofton and Douglas's respiratory diseases*. 4th Ed. New Delhi: Oxford University Press, 1989: 601–29.
- 2 Cullard PH, Freitag L, Reynart MS, *et al*. Respiratory failure due to tracheobronchomalacia. *Thorax* 1996;51: 224–6.
- 3 Schoor VJ, Joos G, Pauwels R. Tracheobronchomegaly—the Mounier Kuhn syndrome: report of two cases and a review of literature. *Eur Respir J* 1991;4:1303–6.
- 4 Katz I, LeVine M, Herman P. Tracheobronchomegaly (the Mounier Kuhn syndrome). *Am J Roentgenol* 1962;88:1084–94.
- 5 Johnston RF, Green RA. Tracheobronchomegaly. Report of five cases and demonstration of familial occurrence. *Am Rev Respir Dis* 1965;91:35–50.
- 6 Schraufnagel DE, Boomsma JD. Tracheobronchomegaly. *Chest* 1992;102:1307.
- 7 Dunne MG, Reiner B. CT features of tracheobronchomegaly. *J Comput Assist Tomogr* 1988;12:388–91.

A transient pleural effusion**Q1: What are the possible causes of a spontaneously resolving pleural effusion?**

The most common causes of spontaneous resolving pleural effusion are given in box 1.¹

Q2: Name one radiological and one diagnostic procedure that would help in making a diagnosis

As part of routine investigation a chest radiograph would be the simplest radiological investigation to exclude pulmonary pathology as a cause of his acute presentation. His chest radiograph showed miliary shadowing but no other abnormality (fig 1).

Box 1: Common causes of spontaneous resolving pleural effusion*Infections*

- Tuberculosis.
- Parapneumonic effusion (non-empyemic).

Connective tissue disease

- Systemic lupus erythematosus.
- Rheumatoid arthritis.

Cardiovascular

- Heart failure.
- Pulmonary infarction.

Drug induced (rare)

- Bromocriptine.
- Dantrolene sodium.

Trauma

In view of the headache with vomiting as one of the main complaints a lumbar puncture should be done after exclusion of raised intracranial pressure. Computed tomography of the brain was normal and cerebrospinal fluid analysis from a lumbar puncture showed the following:

- 55 white cells/ml with 70% monocytes.
- Glucose 1.6 mmol/l (with a blood glucose 5.7 mmol/l).
- Gram stain and Ziehl-Neelsen stain for acid-fast and alcohol-fast bacilli were negative.

Q3: What is the most likely cause of his acute illness and how would you treat him?

The two above mentioned investigations and the clinical course during his acute illness support the diagnosis of miliary tuberculosis with meningeal involvement. He was treated with

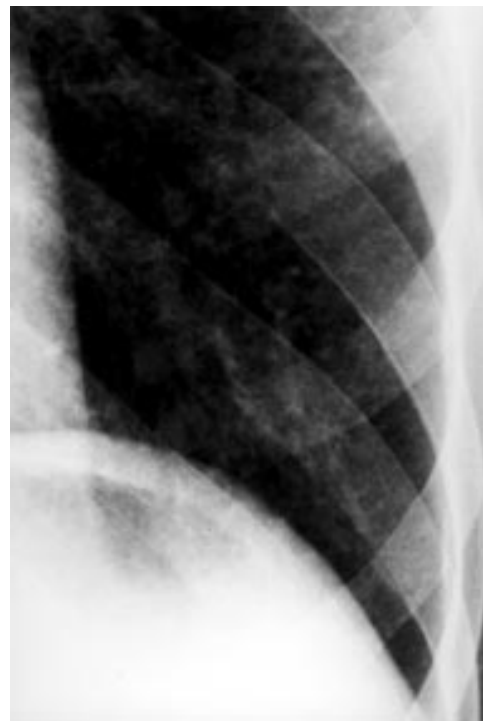

Figure 1 Close-up of chest radiograph taken during the acute presentation showing the area above the left diaphragm.

isoniazid, rifampicin, ethambutol, and pyrazinamide and improved slowly over the next month. His cerebrospinal fluid grew *Mycobacterium tuberculosis* five weeks after the lumbar puncture, fully sensitive to all four antituberculosis drugs prescribed. A repeat chest radiograph after four months was normal and he returned to work as a meat factory worker.

Discussion

Although no further investigations were undertaken during the initial presentation with a pleural effusion, tuberculosis was the most likely cause. Pleural effusion can be a manifestation of primary and post-primary tuberculosis. Primary tuberculous effusion occurs most frequently in young adults.² The effusion is usually unilateral and of moderate size. The diagnosis is best made by pleural biopsy specimens, which show pleural granulomata and positive cultures in 60%–80% of patients with proved tuberculosis and can be improved by using multiple pleural biopsy specimens.³ Enhanced culture yield can be achieved by using bedside inoculation of pleural fluid.⁴ Routine analysis of pleural fluid for glucose, protein, and acid-fast organisms are of little help in making a diagnosis. The value of adenosine deaminase levels in pleural aspirate is controversial. The prognosis of patients with tuberculous pleural effusion depends on the treatment chosen. Simple bed rest commonly results in complete absorption of the effusion but the incidence of subsequent pulmonary or extrapulmonary tuberculosis is high. This is a particular problem in patients with immunosuppression. Treatment with standard antituberculosis drugs is indicated in all cases and reduces the subsequent development of pulmonary or extrapulmonary tuberculosis.⁵ In view of the increasing incidence of tuberculosis in Great Britain all attempts should be made to diagnose and treat patients with tuberculous pleural effusion.

Final diagnosis

Spontaneously resolving tuberculous pleural effusion with subsequent miliary tuberculosis.

I thank Dr J I G Strang for constructive comments.

- 1 Fraser RG, Paré JAP, Paré PD, *et al.* Pleural effusion. *Diagnosis of diseases of the chest*. 3rd Ed. Philadelphia: WB Saunders, 1991: 2713–39.
- 2 Valdes L, Alvarez D, Valle JM, *et al.* The etiology of pleural effusions in an area with high incidence of tuberculosis. *Chest* 1996;**109**:158–62.
- 3 Mungall IP, Cowen PN, Cooke NT, *et al.* Multiple pleural biopsy with the Abrams needle. *Thorax* 1980;**35**:600–2.
- 4 Maartens G, Bateman ED. Tuberculous pleural effusions: increased culture yield with bedside inoculation of pleural fluid and poor diagnostic value of adenosine deaminase. *Thorax* 1991;**46**:96–9.
- 5 Pines A. The results of chemotherapy in the treatment of tuberculous pleural effusions. *BMJ* 1957;**ii**:863–8.

A young woman with muscle weakness

Q1: What is the provisional diagnosis and how will you confirm it?

The characteristic features of muscle pain, a predominant proximal muscle weakness, sluggish ankle jerks, and absence of sensory

Box 1: Laboratory investigations (normal laboratory range in parentheses)

- Serum cholesterol: 6.0 mmol/l (<5.2)
- Serum creatinine: 88.4 µmol/l (53.0–88.4)
- Aspartate aminotransferase: 88 IU/l (<30)
- Alanine aminotransferase: 70 IU/l (<30)
- LDH: 2500 IU/l (0–150)
- Creatine kinase (total): 1795 IU/l (0–100)
- EMG: reduced amplitude of muscle unit potentials
- Muscle biopsy: normal

involvement suggests a primary muscle involvement, that is, a myopathy.

To confirm the diagnosis of a myopathy, biochemical tests such as estimation of serum transaminases, lactic acid dehydrogenase (LDH), aldolase, and creatine kinase are very useful. Of these, the analysis of creatine kinase levels is the most sensitive indicator and measure of muscle damage. Electrodiagnostic tests especially an electromyogram (EMG) are of great value in the diagnosis of muscle disorders. A muscle biopsy can be of great diagnostic value in certain muscle storage disorders, denervative disorders, mitochondrial myopathies, polymyositis, and in some muscle dystrophies.

The laboratory investigations of this patient summarised in box 1 reveal a markedly raised creatine kinase and LDH levels and an EMG pattern all confirming the diagnosis of a myopathy.

Q2: What are the causes of this condition?

Muscle disorders are classified syndromically into acute or subacute, chronic, and episodic depending upon the onset and progress (see box 2).

Pain and tenderness associated with muscle disorders are characteristic of a few specific disorders listed in box 3.

Box 2: classification of muscle diseases

Acute/subacute onset

- Idiopathic polymyositis/dermatomyositis.
- Viral polymyositis.
- Botulism.
- Organophosphorus poisoning.

Chronic onset

- Muscle dystrophies.
- Chronic polymyositis.
- Endocrine myopathies.
- Mitochondrial and other congenital myopathies.
- Storage disorders.

Episodic

- Periodic paralysis.
- Myasthenia gravis.
- Exercise intolerance.

Box 3: Muscle disorders with pain/tenderness

- Connective tissue disorders: lupus erythematosus, polymyositis, polyarteritis nodosa, Sjögren's syndrome, mixed connective tissue disease.
- Localised multifocal fibrositis.
- Trichinosis.
- Myopathy of myoglobinuria and McArdle's syndrome.
- Viral polymyositis.
- Hypothyroidism.

Q3: What is the most probable aetiology in this patient and what further investigations would you order to document it?

In this young woman with myopathy, a history of weight gain, and bradycardia on examination, an endocrine myopathy, especially hypothyroidism, must be excluded. Also, connective tissue disorders such as polymyositis and lupus erythematosus should be ruled out with appropriate investigations.

Q4: The special laboratory investigations of the patient are summarised on p 274. What is the final diagnosis?

Raised TSH along with a low triiodothyronine confirm the diagnosis of hypothyroidism. The presence of anti-TPO antibodies provides conclusive evidence of an autoimmune thyroid disease with resultant hypothyroidism.

The patient was given thyroxine replenishment and there was marked symptomatic improvement and the creatine kinase, LDH, and TSH levels returned to normal.

Discussion

Hypothyroidism is associated with a wide range of muscle disturbances varying from myalgias, to a true myopathy to rhabdomyolysis.^{1,2} Two classic syndromes of hypothyroid muscle disorders have been described: the Kocher-Debré-Sémélaigne syndrome (cretinism associated with myopathy) and Hoffmann's syndrome (myxoedema in childhood or adult life associated with muscle hypertrophy). The muscle disorders usually occur in the setting of an established chronic hypothyroid state, though rarely, they may occur in acute hypothyroidism as well.³

Myopathy as the sole presenting feature of hypothyroidism, without the other typical signs

Box 4: Learning points

- Though unusual, myopathy may be the presenting feature of hypothyroidism.
- All patients with a myopathy of obscure origin should be investigated to exclude disorders like hypothyroidism.

and symptoms of hypothyroidism, as seen in this patient, is however unusual. Most such cases have been found to be of autoimmune origin.⁴

Impaired energy metabolism that limits force generation, a reduction in the myosin ATPase activity reflected by the slow contraction and relaxation of the reflexes, and an impaired calcium uptake by the sarcoplasmic reticulum are the proposed pathogenetic mechanisms of muscle weakness in hypothyroidism.⁵

The spectrum of structural changes in the skeletal muscles in hypothyroid myopathy is a continuum. The changes in muscle biopsy correlate with the severity of hypothyroidism and consist of increasing type 2 fibre atrophy and central nuclear counts on light microscopy, and excessive glycogen accumulation and increased numbers of mitochondria on electron microscopy. The changes on muscle biopsy also depend on the amount of tissue available for assessment.⁶

Substitutive therapy with thyroxine is used in the treatment of hypothyroid myopathy. Marked improvement in symptoms and laboratory parameters occurs on attainment of an euthyroid state. The present patient was unusual in that she presented with only features of a primary muscle disorder without pointers to an underlying hypothyroid state. The learning points from this case are summarised in box 4.

Final diagnosis

Autoimmune thyroid disease, hypothyroidism, and hypothyroid myopathy.

- 1 Lochmuller H, Reimers CD, Fischer P, *et al.* Exercise-induced myalgia in hypothyroidism. *Clin Invest* 1993;71:999-1001.
- 2 Sekine N, Yamamoto M, Michikawa K, *et al.* Rhabdomyolysis and acute renal failure in a patient with hypothyroidism. *Intern Med* 1993;32:269-71.
- 3 Kung AW, Ma JT, Yu YL, *et al.* Myopathy in acute hypothyroidism. *Postgrad Med J* 1987;63:661-3.
- 4 Rodolico C, Toscano A, Benvenega S, *et al.* Myopathy as the persistently isolated symptomatology of primary autoimmune hypothyroidism. *Thyroid* 1998;8:1033-8.
- 5 Ruff RL, Weissmann J. Endocrine myopathies. *Neurol Clin* 1988;6:575-92.
- 6 McKeran RO, Slavin G, Ward P, *et al.* Hypothyroid myopathy: a clinical and pathological study. *J Pathol* 1980;132:35-54.