

SELF ASSESSMENT QUESTIONS

From confusion to coma: a catastrophic deterioration

K Ashkan, F Johnston

Answers on p 56.

A previously well 45 year old woman presented to the local casualty department with a one day history of generalised headache, neck stiffness, and blurred vision. On examination she had a temperature of 38°C, a pulse of 80 beats/min, and a blood pressure of 130/80 mm Hg. Neurologically, she had spontaneous eye opening and was able to obey commands, although she had confused speech (Glasgow coma scale (GCS), 14). Pupils were equal and reactive with no cranial or peripheral neurological deficits. Blood tests showed a raised white cell count of $20.9 \times 10^9/l$ with a neutrophilia ($19.2 \times 10^9/l$). Computed tomography (CT) of the brain was performed (fig 1), on the basis of which the patient was referred to the regional neurosurgical unit. While awaiting urgent transfer, however, her clinical condition suddenly deteriorated. There was no eye opening or verbal response, although she flexed to painful stimuli (GCS 5). She was intubated and

ventilated before transfer. On arrival at the neurosurgical intensive care unit, she was found to have bilaterally fixed and dilated pupils, with no corneal or gag reflexes. There was, however, abnormal flexion of the left upper limb. She was given mannitol and urgent repeat CT was carried out (fig 2). An operation was then performed, but postoperatively she failed to show any clinical improvement and died the next day.

Questions

- (1) What does figure 1 show and what is the differential diagnosis?
- (2) How does figure 2 relate to the change in the patient's clinical condition?
- (3) Discuss the management of this condition.

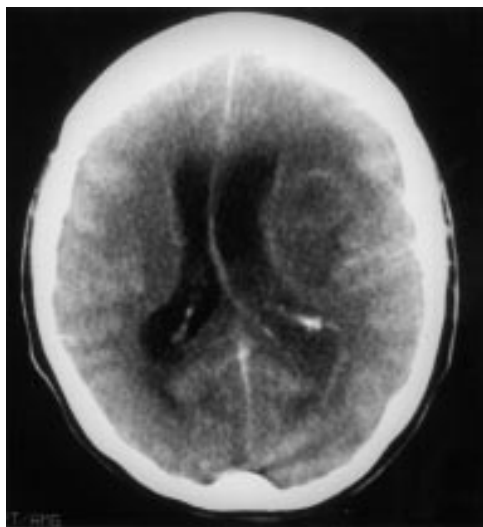


Figure 1 Computed tomography of the brain at the initial presentation.

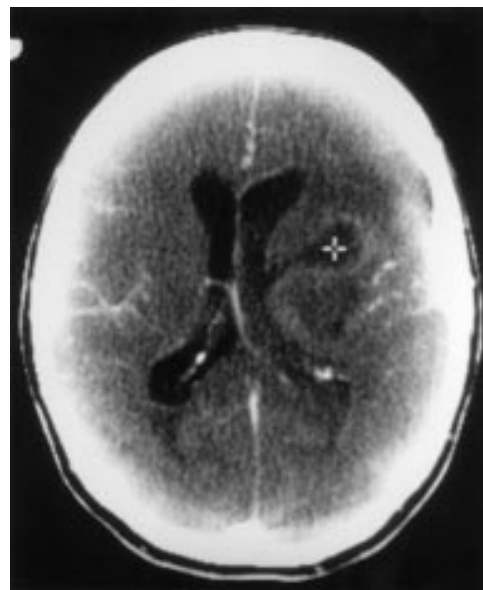


Figure 2 Computed tomography of the brain following the sudden deterioration.

Department of
Neurosurgery,
Atkinson Morley's
Hospital, Copse Hill,
Wimbledon, London
SW20 0NE, UK
K Ashkan
F Johnston

Correspondence to:
Mr Keyoumars Ashkan,
Department of
Neurosurgery, Hurstwood
Park Neurological Centre,
Princess Royal Hospital,
Haywards Heath, West
Sussex RH16 4EX, UK

Submitted 7 October 1999
Accepted 20 December 1999

Cyanosis in late teens

S G Williams, D J Wright, U M Sivananthan

Answers on p 56.

Institute for Cardiovascular Research, Yorkshire Heart Centre, Jubilee Building, Leeds General Infirmary, Leeds LS1 3EX, UK
S G Williams
D J Wright
U M Sivananthan

Correspondence to:
Dr Williams
simongwilliams@hotmail.com

Submitted 5 November 1999
Accepted 31 January 2000

An 18 year old youth presented with a three year history of decreasing exercise tolerance and cyanosis. Physical examination revealed clubbing and cyanosis, with an estimated oxygen saturation of 76% (on air). There were no other abnormalities on cardiovascular or respiratory examination. Arterial blood gas estimation revealed a P_{O_2} of 5.85 kPa breathing air, increasing only to 6.8 kPa after 10 minutes on 100% oxygen. Haemoglobin was 22 g/dl. ECG, chest x ray, and conventional echocardiography were normal.

A transoesophageal echocardiogram is shown in fig 1.

Questions

- (1) What is the most likely cause of the cyanosis?
- (2) What does the transoesophageal echocardiogram show?
- (3) What treatment options are available for this patient?

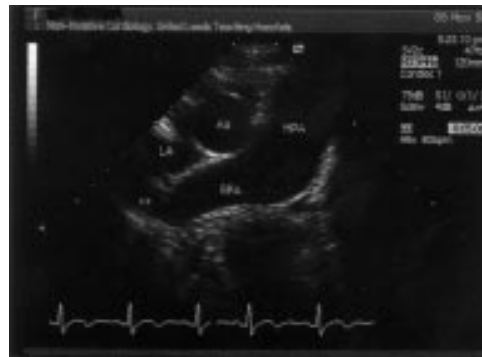

Figure 1 Transoesophageal echocardiogram. Ao, aorta; LA, left atrium; MPA, main pulmonary artery; RPA, right pulmonary artery.

Recent onset of bleeding and gross coagulopathy

R E Hough, M Makris

Answers on p 57.

Department of Haematology, Royal Hallamshire Hospital, Glossop Road, Sheffield S10 2JF, UK
R E Hough
M Makris

Correspondence to:
Dr Makris
m.makris@sheffield.ac.uk

Submitted 28 October 1999
Accepted 22 December 1999

A 58 year old unemployed man was admitted as an emergency with a two week history of gum bleeding and a one day history of gross haematuria. Other than osteoporosis and low back pain his past medical history was unremarkable. He had had previous dental extractions and major surgery without any excessive bleeding. He did not have a family history of a bleeding disorder. His diet was normal and contained vegetables and fruit. His weight was stable, his appetite was good, and he had no bowel symptoms. Regular drug ingestion was confined to co-codamol, Distalgesic, and diazepam. His alcohol intake was less than 10 units/week. Clinical examination was unremarkable and he had no purpura or echymoses, no hepatosplenomegaly, and no signs of chronic liver disease.

INVESTIGATIONS

His blood test results on admission were as follows:

Full blood count—haemoglobin 14.7 g/dl, white cell count $12.5 \times 10^9/l$, platelet count $222 \times 10^9/l$.

Clinical chemistry—creatinine 113 $\mu\text{mol/l}$, glucose 5.0 mmol/l, adjusted calcium 2.35 mmol/l, aspartate transaminase 17 U/l, alanine transaminase 18 U/l, bilirubin 5 $\mu\text{mol/l}$, γ glutamyl transferase 45 U/l, albumin 39 g/l.

Coagulation tests:

- Prothrombin time 230 s (normal range 9.5–11.5 s).
- International normalised ratio (INR) 25.5.
- Prothrombin time + 50% normal plasma 9.5 s.
- Activated partial thromboplastin time (APTT) 116 s (normal 27–36).
- APTT + 50% normal plasma 49.3 s.
- Thrombin time 18.6 s (normal 18–23).
- Fibrinogen 7.7 g/dl (normal 1.7–3.3).

Questions

- (1) What is the differential diagnosis?
- (2) What is the most likely diagnosis and how would you prove it?
- (3) How would you treat this patient?

A young man with seizures, abusive behaviour, and drowsiness

A G Unnikrishnan, S Rajaratnam

Answers on p 58.

A 20 year old man was brought to hospital with progressive drowsiness and vomiting for three days. Two weeks before admission his relatives noted that he was becoming agitated, violent, and abusive. He had previously fractured his left humerus owing to a fall during a seizure. He had been on phenytoin and phenobarbitone for seizure control for the past two months. There was no history of substance abuse or alcohol intake, neither was there a history of previous neck surgery.

On examination he was dehydrated and he had a tachycardia, a low blood pressure (90/70 mm Hg), and low central venous pressure (+4 cm). He was found to be talking irrelevantly and not obeying commands. He had generalised rigidity. There was no papilloedema. Systemic examination revealed no other abnormality.

Haematological investigations were normal. Serum biochemical investigation results were as follows (mmol/l unless stated): sodium 130, potassium 3.6, bicarbonate 13, chloride 105, magnesium 0.53, calcium 1.025 (corrected calcium 1.36), phosphorus 1.81, albumin 23 g/l, urea nitrogen 38.1, creatinine 318 μ mol/l, and intact parathormone (PTH) 2.1 pmol/l (normal 1.3 to 7.6 pmol/l). Ultrasound of the abdomen showed normal sized kidneys with no

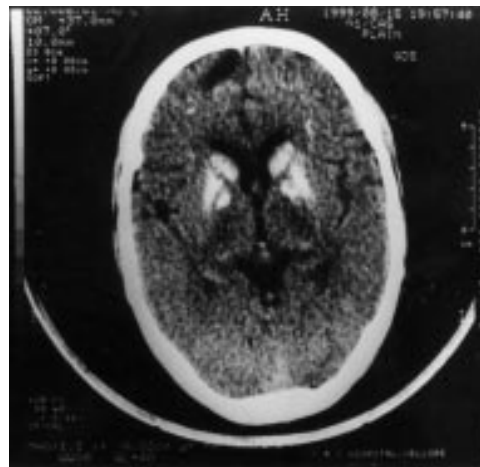


Figure 1 Computed tomography of the brain.

parenchymal lesions. Computed tomography of the brain is shown in fig 1.

Questions

- (1) What is the diagnosis?
- (2) What factors could have worsened the hypocalcaemia in this patient?
- (3) What is the differential diagnosis on the computed tomograph of the brain?

Department of
Endocrinology, CMC
Hospital, Vellore—632
004, Tamil Nadu, India
A G Unnikrishnan
S Rajaratnam

Correspondence to:
Dr Rajaratnam
simonraj@hotmail.com

Submitted 26 October 1999
Accepted 22 December 1999

A case of reversible amnesia

J Stone, I W Campbell, G D Moran, C J Mumford

Answers on p 59.

Department of Clinical
Neurosciences,
Western General
Hospital, Edinburgh
EH4 2XU, UK
J Stone
G D Moran
C J Mumford

Department of
Medicine, Victoria
Hospital, Kirkcaldy
and Department of
Medical Sciences,
University of
St Andrews, Fife, UK
I W Campbell

Correspondence to:
Dr Stone

Submitted 19 November 1999
Accepted 10 January 2000

A 43 year old, normally healthy woman was admitted to a general medical ward after collapsing at home. Over the preceding two weeks, her husband had noticed that she had seemed distracted, unusually depressed, and "not herself." He had found his wife unresponsive and writhing on the floor. She was initially drowsy after the attack but became alert within 30 minutes. On admission, she was amnesic for the episode, disoriented in time, place, and person, apyrexial, and clinically euthyroid, with no meningism or focal neurological signs. Computed tomography of the head was normal. CSF protein was 0.74 g/l (normal range 0.35–0.45 g/l), with normal glucose and no cells. Serum biochemistry and full blood count were within normal limits, apart from her thyroid stimulating hormone (TSH) which was raised at 7.14 mU/l (normal 0.5–3.9 mU/l). Her serum free T4 was normal at 15 pmol/l (normal 10–19 pmol/l). She received 10

days of intravenous acyclovir for a presumed generalised seizure possibly complicating viral encephalitis. Subsequently, CSF and serum viral serology and an autoantibody screen were negative.

During and after treatment she had a fluctuating level of confusion and appeared distant with a flat affect. Three weeks after the initial presentation she had another episode of collapse with writhing movements as before. Her mini-mental state examination was 19/30, with deficits in orientation and attention and total anterograde amnesia. Her neurological examination remained otherwise normal. She was still clinically euthyroid. Her TSH had increased to 25 mU/l with a normal T4 of 15 pmol/l. Her thyroid microsomal antibodies were raised at more than 1:6400. Her thyroglobulin antibodies were negative. Magnetic resonance imaging of the head was normal. Repeat CSF protein was 0.76 g/l with a normal

glucose, 4 white cells per high power field, and no oligoclonal bands. An EEG was normal even in the presence of choreiform movements of the arms.

Three days after the second collapse she was started on prednisolone 60 mg daily. Within 24 hours the patient's mental state returned to normal. She had complete retrograde amnesia for the previous four weeks but was able to

recall feeling mildly depressed and apathetic for a week before that. Nine months later she remained well on prednisolone 7.5 mg/day.

Questions

- (1) What is the most likely diagnosis?
- (2) Name four other ways in which this disease can present.
- (3) What is the likely prognosis?

A metabolic complication of pregnancy

S Shah, D Turner, O Adeyemi, S Olczak

Answers on p 60.

A 32 year old pregnant woman (gravida 3, para 1) was referred to the antenatal booking clinic at 12 weeks. She had recently been found to be hypertensive by her general practitioner, and her blood pressure was 150/100 mm Hg. Treatment was started with methyldopa. Ultrasound showed a normally grown fetus. A renal ultrasound examination was abnormal (fig1). She had symptoms of tiredness and nausea

attributed to her pregnancy. There was no history of abdominal pain, renal colic, muscle cramps, arthralgia, or polyuria and she was not taking any drugs apart from methyldopa. There was no family history of endocrine disease. Her mother suffered from hypertension, and the patient herself had been hypertensive during the last few weeks of her previous pregnancy in 1994. This resolved following delivery.

Full blood count, renal function, urate, thyroid function, serum magnesium, and urine microscopy were normal. Serum calcium was 3.47 mmol/l (normal 2.0–2.6 mmol/l), serum phosphate 0.64 mmol/l (0.8–1.2 mmol/l), and serum parathormone 15 ng/l (2–6 ng/l); 24 hour urinary catecholamine excretion was normal. Ultrasound of the parathyroids is shown in fig 2.

Questions

- (1) What are the findings on the ultrasound in figs 1 and 2?
- (2) How should this patient be managed?

Department of
Diabetes and
Endocrinology,
University Hospital,
Nottingham NG7 2UH,
UK
S Shah

Department of
Diabetes and
Endocrinology,
Pilgrim Hospital,
Boston,
Lincolnshire, UK
S Olczak

Department of
Obstetrics and
Gynaecology,
Pilgrim Hospital
O Adeyemi

Department of
Surgery,
Pilgrim Hospital
D Turner

Correspondence to:
Dr Shah
sanjayshah25@hotmail.com

Submitted 8 December 1999
Accepted 31 January 2000

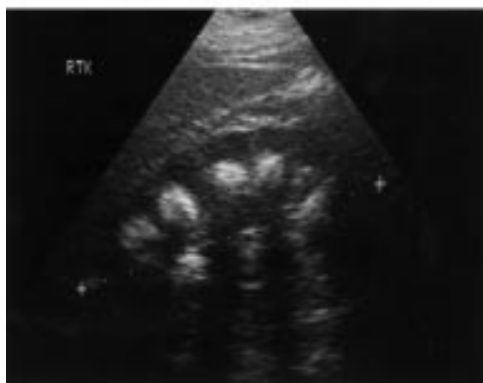
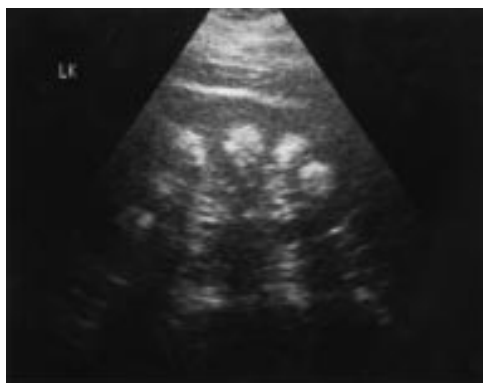
Figure 1 Renal ultrasound examination.

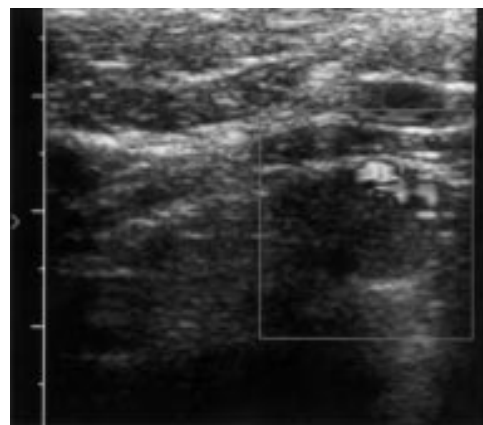


Figure 2 Parathyroid ultrasound examination.

SELF ASSESSMENT ANSWERS

From confusion to coma: a catastrophic deterioration

Q1: What does figure 1 show and what is the differential diagnosis?

Figure 1 (p 52) shows a ring enhancing lesion with surrounding oedema in the left frontal lobe. Given the clinical features of pyrexia and also the raised white cell count, the most likely diagnosis is cerebral abscess. Other conditions to consider in the differential diagnosis include primary and secondary neoplasms.

Q2: How does figure 2 relate to the change in the patient's clinical condition?

Figure 2 (p 52) shows the abscess communicating and discharging, through a tract, into the ipsilateral ventricle. Intraventricular rupture of an abscess is usually a catastrophic event leading to ventriculitis and dissemination of organisms throughout the cerebrospinal fluid pathway.¹ This event accounts for the calamitous deterioration in the patient's clinical condition.

Q3: Discuss the management of this condition.

Improvements in imaging techniques, particularly the development of contrast enhanced CT scanning and its recommended use before lumbar puncture in patients with meningism, advances in neurosurgery and especially stereotaxy, availability of more effective antibiotics, and better neurointensive care facilities have resulted in a substantial reduction in mortality from brain abscess.¹ Intraventricular rupture of a cerebral abscess, however, continues to be a devastating event, carrying mortality rates of up to 85%.²⁻⁴

Delay in diagnosis and subsequent neurosurgical referral are important risk factors for this condition. The main diagnostic problem is differentiation of a cerebral abscess from a ring enhancing tumour. Although not absolute, however, certain features may favour the former diagnosis: Abscesses tend to be sited in the vascular watershed regions, often having a thin, smooth, enhancing wall which is in contrast to the thick, irregular, diffuse enhancement seen with tumours.¹ Once suspected, all abscesses require urgent neurosurgical assessment, but perhaps the urgency is greater in those located close to the ventricular system because of the risk of intraventricular rupture.

Once ruptured, the prognosis of such patients remains poor. Both stereotactic aspiration and craniotomy and evacuation of the abscess, with variable results, have been reported.²⁻⁵ Most neurosurgeons also advocate insertion of an external ventricular drain to allow both drainage of contaminated cerebrospinal fluid and direct administration of intrathecal antibiotics.²⁻⁴ The choice of antibiotics is crucial and often entails initial treatment with broad spectrum antibiotics followed by more specific antimicrobial treatment once culture and sensitivity results from the abscess

aspirate are available. The optimum duration of antibiotic treatment is not clear but most recommend at least six weeks.²

In the case described here, the patient already had severe neurological compromise with fixed and dilated pupils by the time of arrival at the neurosurgical unit. An urgent stereotactic aspiration of the abscess was performed and an external ventricular drain was inserted to allow drainage of infected CSF. Gram stain of the aspirate from the abscess showed both Gram positive cocci and rods. The patient was started on a combination of intravenous benzylpenicillin, cefotaxime, vancomycin, and metronidazole, as well as intrathecal vancomycin. Despite this treatment, however, the patient continued to deteriorate and died shortly after. CSF culture results later showed *Streptococcus milleri* and *Actinomyces meyeri*, both sensitive to penicillin.

Conclusion

Proximity of an intracerebral abscess to the ventricular system warrants particularly urgent neurosurgical attention.

Final diagnosis

Intraventricular rupture of cerebral abscess.

- Mathisen GE, Johnson JP. Brain abscess. *Clin Infect Dis* 1997;25:763-81.
- Zeidman SM, Geisler FH, Olivi A. Intraventricular rupture of a purulent brain abscess: case report. *Neurosurgery* 1995; 36:189-93.
- Hashizume A, Kodama Y, Hotta T, et al. A case of brain abscess of the basal ganglia which resulted in disastrous outcome due to ventricular rupture. *No Shinkei Geka* 1994;22: 383-6.
- Sato M, Oikawa T, Sasaki T, et al. Brain abscess ruptured into the lateral ventricle: the usefulness of treatment by intraventricular irrigation with antibiotics. A case report. *No Shinkei Geka* 1994;22:689-93.
- Isono M, Wakabayashi Y, Nakano T, et al. Treatment of brain abscess associated with ventricular rupture—three case reports. *Neurologia Medico-Chirurgica* 1997;37:630-6.

Cyanosis in late teens

Q1: What is the most likely cause of the cyanosis?

A form of congenital cyanotic heart disease with a right to left shunt is the most likely cause of cyanosis in this case. Pulmonary causes for the cyanosis are virtually eliminated by the normal chest x ray and non-correction of hypoxia with 100% oxygen.

Q2: What does the transoesophageal echocardiogram show?

The TOE shows an abnormal connection (indicated by the arrow) between the left atrium and dilated right pulmonary artery. The cause of this patient's cyanosis is a left atrial to right pulmonary artery fistula.

Q3: What treatment options are available for this patient?

Several treatment options are available. Surgery can be undertaken to close the fistula by

ligation or dissection, or it can be closed during cardiac catheterisation and pulmonary angiography by embolisation using a steel coil, umbrella, or detachable balloon.

Discussion

A fistula between the pulmonary artery and left atrium is a rare type of pulmonary arterio-venous malformation. It is, however, an important diagnosis to make as it can be corrected by simple surgical techniques, and the patient usually recovers to lead a normal life. The commonest causes of a pulmonary arterio-venous malformation are either that it is a congenital malformation or that it is associated with hereditary haemorrhagic telangiectasia.¹ Acquired forms are either caused by trauma or are associated with juvenile hepatic cirrhosis, portal vein thrombosis, schistosomiasis, or metastatic thyroid carcinoma. Pulmonary arterio-venous malformations usually present in early adult life with the classic triad of cyanosis, clubbing, and polycythaemia with no cardiac murmur. In severe cases they occasionally present with cyanosis and heart failure in infancy. A few patients remain completely asymptomatic—mild desaturation by pulse oximetry may be the only finding. Pulmonary symptoms include breathlessness on exertion, haemoptysis, or thoracic pain. In some patients, neurological symptoms such as headaches, fits, speech disorders, or transient ischaemic attacks may dominate the clinical picture. Transient ischaemic attacks and stroke from paradoxical emboli may occur in up to 40–50% of patients.¹ It is estimated that the annual risk of stroke in these patients is approximately 1.5%.²

Cardiac cyanosis (caused by a right to left shunt) is differentiated from pulmonary causes of cyanosis by there being no significant increase in Po_2 after inhaling 100% oxygen. Secondary polycythaemia may occur because of a compensatory increase in erythropoietin production. Other simple clues to aid the diagnosis include ECG findings of left axis deviation, left atrial enlargement, and left ventricular hypertrophy,^{3,4} and an opacity adjacent to the right border of the cardiac silhouette on chest x ray.³

To diagnose an atrial to pulmonary artery fistula, a high index of suspicion is required during echocardiography. The pulmonary artery may appear dilated and tortuous, and increased flow velocities may be seen on Doppler examination of the pulmonary veins. This is often difficult to detect, especially in smaller shunts, and this difficulty was seen in our case. TOE can be used as a supplementary investigation and has proved to be of great diagnostic value in many aspects of both paediatric and adult cardiology. Conventional transthoracic echocardiography is limited by the poor tissue penetration of high frequency transducers (5 MHz). Adequate images can be sometimes difficult to obtain even with lower frequency transducers (2.25–2.5 MHz), and structures at the back of the heart (for example, the left atrium) can often be missed. Magnetic resonance imaging and computed tomography are

Learning points

- Cardiac cyanosis (from a right to left shunt) can be differentiated from pulmonary causes of cyanosis by the fact that there is no significant increase in Po_2 with 100% oxygen.
- Pulmonary arterio-venous malformations are relatively common causes of cyanosis in adolescence.
- Pulmonary artery to atrial fistula is a rare type of pulmonary arterio-venous malformation.
- The diagnosis of these lesions is important as they are easily treatable.
- Conventional echocardiography can miss the diagnosis, and TOE may be used as a supplementary investigation.

considered supplementary investigations. TOE has an advantage over computed tomography and angiography, especially in children and adolescents, in that it involves no ionising radiation and is therefore safe for repeated use.

- 1 White RI, Lynch-Nyhan A, Terry P, *et al.* Pulmonary arteriovenous malformations: techniques and long term outcome of embolotherapy. *Radiology* 1988;**169**:663–9.
- 2 Gelfand MS, Stephen DS, Howell E, *et al.* Brain abscess: association with pulmonary arteriovenous fistula and hereditary haemorrhagic telangiectasia—report of three cases. *Am Med J* 1988;**85**:718–20.
- 3 Jimenez M, Fournier A, Chossat A. Pulmonary artery to the left atrium fistula as an unusual case of cyanosis in the newborn. *Pediatr Cardiol* 1989;**10**:216–20.
- 4 Chilvers ER. Clinical and physiological aspects of pulmonary arteriovenous malformations. *Br J Hosp Med* 1988;**196**: 188–92.

Recent onset of bleeding and gross coagulopathy

Q1: What is the differential diagnosis?

The differential diagnosis is:

- Congenital factor V or factor X deficiency.
- Acquired deficiency of factor V or factor X resulting from a specific autoantibody.
- Acquired factor X deficiency in association with systemic amyloidosis.
- Vitamin K deficiency.
- Warfarin overdose/excess.

In view of the extreme prolongation of prothrombin time and APTT, if this was factor V or factor X deficiency, it would have to have been a severe deficiency with clotting factor levels less than 2% of normal. The fact that he had had previous surgery without excessive bleeding effectively excludes congenital deficiency of these factors. Acquired deficiency caused by an autoantibody specifically against factors V or X is also excluded by the fact that there was normalisation of the clotting tests in the mixing experiments. In a previously healthy man amyloidosis would be unlikely. The high fibrinogen and normal platelet count, in the presence of such prolonged prothrombin time, makes the diagnosis of liver disease or disseminated intravascular coagulation highly unlikely.

Q2: What is the most likely diagnosis and how would you prove it?

The most likely cause would be a problem with the vitamin K dependent clotting factors, either because of vitamin K antagonism (warfarin excess) or because of vitamin K deficiency (dietary deficiency or malabsorption). Vitamin K deficiency would be extremely unlikely in view of the patient's normal diet and lack of gastrointestinal symptoms, and as he had not been taking any antibiotics. Although we normally detect the warfarin effect indirectly by its action on the coagulation system (by measuring the INR), it can also be demonstrated directly in the patient's plasma, using high performance liquid chromatography (HPLC).

Q3: How would you treat this patient?

As the bleeding is not life threatening, treatment with intravenous vitamin K is all that is required.

OUTCOME IN THIS PATIENT

Ten hours after an intravenous dose of 10 mg vitamin K, his bleeding stopped, his prothrombin time was 15.9 s and his APTT was 37.9 s. By the following day all his clotting tests were normal. Although he denied taking any warfarin, this drug was detected in his plasma using HPLC. When his regular drugs were examined, the container with a label of diazepam contained 5 mg warfarin tablets.

Discussion

When faced with significantly abnormal coagulation tests, as in this case, the clinician must first decide if the abnormality is likely to be inherited or acquired. For patients who have had haemostatic challenges in the past—such as surgery or dental extractions—without excessive bleeding, this is usually easy. In inherited deficiencies the only reliable way to make the diagnosis is by direct measurement of the relevant individual clotting factors.

The next step in a case of an acquired abnormality such as this is to see if the defect is caused by a true synthetic deficiency or by destruction of the synthesised clotting factor by a specific autoantibody against it. Factor VIII autoantibodies causing acquired haemophilia A are the ones most commonly encountered in clinical practice, but autoantibodies to all the clotting factors have been reported. These two possibilities can be differentiated by performing mixing tests.¹ Patient's plasma is mixed with normal plasma that contains all the clotting factors in normal amounts. If an antibody is present, it will destroy the added factor and the clotting tests will remain prolonged. In a true synthetic deficiency the addition of the factor in plasma will correct the clotting tests.

When both the PT and APTT are abnormal, the problem is either a single factor deficiency in the common coagulation cascade pathway, or it is caused by defects in both the intrinsic and the extrinsic pathways; these are mostly a result of oral anticoagulant therapy. Although all the coagulation factors can be assayed individually, a more practical step is to give a single

Learning points

- A good history will differentiate between inherited and acquired coagulation abnormalities.
- Mixing experiments will differentiate between a true deficiency and the presence of an inhibitor.
- Warfarin can be demonstrated in plasma directly using high performance liquid chromatography. This is useful in detecting warfarin in patients who deny taking the drug, or more often where patients who are meant to be on warfarin present with normal clotting and claim to be taking their tablets.
- In patients with very high INR, fresh frozen plasma is not required. Intravenous vitamin K will correct the coagulopathy within 6–8 hours.

dose of vitamin K, as this would correct any anticoagulant related problem.

This was an unusual case in that the patient inadvertently received warfarin. Clinically the situation most commonly encountered when patients have a similar coagulopathy is either a deliberate overdose with warfarin or a drug interaction in patients who are already taking warfarin. In all such situations it is tempting to use fresh frozen plasma to replace the clotting factors; 1 litre of plasma will, however, only raise the individual factor levels by 10%.² A much more effective way is to give intravenous vitamin K, which will bring the INR into the therapeutic range in almost all cases within six to eight hours. The dose of vitamin K will depend on whether anticoagulation needs to be continued, as for example in patients with metal prosthetic heart valves, when a dose of 2–3 mg should be given and repeated if necessary. For patients in whom anticoagulation will not be continued, a dose of 10 mg should be given.

1 Hay CRM, Colvin BT, Ludlam CA, *et al.* Recommendations for the treatment of factor VIII inhibitors: from the UK Haemophilia Centre Directors' Organisation Inhibitor Working Party. *Blood Coagul Fibrinolysis* 1996;7:134–8.

2 Makris M, Greaves M, Phillips WS, *et al.* Emergency oral anticoagulant reversal: the relative efficacy of infusions of fresh frozen plasma and clotting factor concentrate on correction of the coagulopathy. *Thromb Haemost* 1997;77:477–80.

A young man with seizures, abusive behaviour, and drowsiness

Q1: What is the diagnosis?

The diagnosis is idiopathic hypoparathyroidism with basal ganglia calcification. The serum PTH level is inappropriately low for the degree of hypocalcaemia. Hypocalcaemia could have been worsened by other factors (as mentioned below).

There was associated renal failure, probably from prerenal causes, as the patient was clinically dehydrated and hypotensive, with a low central venous pressure and a high urea to creatinine ratio. Renal ultrasound was normal.

Chronic renal failure with secondary hyperparathyroidism can be a cause of basal ganglia

calcification,¹ but there would be high circulating parathormone in that case.

Basal ganglia calcification is known to be associated with calcification of the cortex and cerebellum.² In such cases the patient can present with neuropsychiatric manifestations.³

Q2: What factors could have worsened the hypocalcaemia in this patient?

Other factors that could have contributed to the hypocalcaemia include hypomagnesaemia, renal failure, and the use of anticonvulsant drugs. Hypomagnesaemia produces hypocalcaemia by reducing parathormone secretion and also by interfering with parathormone action.⁴ Hypomagnesaemia in our patient was probably caused by a combination of an inadequate intake and acidosis from the accompanying renal failure. Systemic acidosis is known to aggravate magnesium loss in the urine. High dose calcium replacement can lead to calciuria and renal magnesium wasting; hence the serum magnesium in hypoparathyroid patients on treatment needs to be monitored closely.

Phenytoin and phenobarbitone can interfere with vitamin D metabolism.⁵ These drugs induce hepatic enzymes that convert vitamin D and 25-hydroxyvitamin D into their inactive metabolites. In addition they impair calcium absorption from the gut and also affect the resorption of calcium from bone.

Low albumin may reduce the total serum calcium but it does not affect the ionised calcium levels and hence does not contribute to symptomatic hypocalcaemia.

Q3: What is the differential diagnosis on the computed tomograph of the brain?

The various causes of basal ganglia calcification are listed in box 1. The most important treatable cause is hypoparathyroidism. This is characterised by hypocalcaemia, hyperphosphataemia, and a low serum parathormone. Idiopathic hypoparathyroidism can occur as an isolated condition or it may be part of a polyglandular endocrinopathy (candidiasis, autoimmune hypoadrenalism, and thyroid disease). Pseudohypoparathyroidism is caused by target organ resistance to parathormone. These patients have characteristic clinical features (such as a short fourth metacarpal bone) and high circulating parathormone levels.

Idiopathic basal ganglia calcification can occur as a normal variant in elderly people. Other causes include Fahr syndrome (idiopathic cerebrovascular ferrocalsinosis) and Cockayne syndrome (associated with progeria). Basal ganglia calcification can also result from exposure to lead and carbon monoxide.

PROGRESS OF OUR PATIENT

The patient was started on an intravenous calcium infusion. He was also given parenteral magnesium sulphate. His sensorium improved dramatically and he was started on oral calcium and vitamin D supplements. His renal function improved with adequate hydration, and his serum creatinine and urea levels normalised. This confirmed our suspicion that there was underlying prerenal failure. A small dose of

Box 1: Causes of basal ganglia calcification

- Idiopathic basal ganglia calcification
- Hypoparathyroidism
 - Idiopathic (autoimmune)
 - Congenital
 - Post-thyroidectomy
- Pseudohypoparathyroidism
- Secondary hyperparathyroidism (in renal disease)
- Congenital infections (for example, toxoplasmosis)
- Mitochondrial cytopathies
- Fahr syndrome
- Cockayne syndrome
- Toxins
 - Carbon monoxide
 - Lead poisoning

Learning points

- Basal ganglia calcification may present with neuropsychiatric manifestations.
- Calcific foci in other intracranial sites like the cerebellum and cerebral cortex are often associated features.
- Magnesium deficiency can worsen hypocalcaemia.
- Frequent estimation of serum magnesium is necessary in patients on treatment for hypoparathyroidism.
- If these patients also require long term anticonvulsant treatment, they will need close monitoring of their calcium status.

levodopa with carbidopa was sufficient to control the extrapyramidal symptoms. He was asymptomatic and normocalcaemic on discharge.

Final diagnosis

Idiopathic hypoparathyroidism with basal ganglia calcification

- 1 Sutton D, Kendall B, Stevens J. Intracranial lesions. In: Sutton D, ed. *Textbook of radiology and imaging*, 6th ed. New York: Churchill Livingstone, 1998:1619–60.
- 2 Goel A, Bhatnagar MK, Vashishta A, et al. Hypoparathyroidism with extensive intracranial calcification: a case report. *Postgrad Med J* 1994;70:913–15.
- 3 Rosenberg DR, Neylan TC, El-Alwar M, et al. Neuropsychiatric symptoms associated with idiopathic calcification of the basal ganglia. *J Nerv Ment Dis* 1991;179:48–9.
- 4 Becker KL. *Principles and practice of endocrinology and metabolism*. Philadelphia: JB Lippincott, 1995:559–622.
- 5 Hahn TJ. Drug induced disorders of vitamin D and mineral metabolism. *Endocrinol Metab Clin North Am* 1980;9:107–29.

A case of reversible amnesia

Q1: What is the most likely diagnosis?

The combination of delirium, intermittent neurological symptoms, high CSF protein, normal MRI, positive antithyroid antibodies, and reversibility of symptoms with steroids is highly suggestive of Hashimoto's encephalopathy. The differential diagnosis of delirium with a normal MRI includes systemic infection, viral or other infective causes of encephalitis, meta-

bolic disturbance (including hypothyroidism and hyperthyroidism), drug intoxication or withdrawal, or non-convulsive status epilepticus (or postictal or interictal confusion). Rarely, autoimmune disorders such as systemic lupus erythematosus or primary central nervous system vasculitis, and primary CNS tumours such as intravascular lymphoma, may present with a normal MRI.

Q2: Name four other ways in which this disease can present.

The manifestations of Hashimoto's encephalopathy are protean, encompassing virtually any neurological symptom. In a recent survey of reported cases,¹ the frequency of symptoms was as follows: epileptic seizures 63%, reduced consciousness 54%, dementia 52%, psychosis 48%, personality change 39%, myoclonus 33%, ataxia 28%, pyramidal signs 28%, stroke-like episodes 26%, hallucinations 19%, extrapyramidal movement disorder 7%, dysarthria 7%.

Q3: What is the likely prognosis?

This has not been definitively studied. Many cases either respond dramatically to steroids or resolve spontaneously. Untreated, the condition can develop into a severe dementia with neurological features. A recent report¹ describes seven cases that were initially diagnosed as Creutzfeldt-Jakob disease but subsequently improved or resolved after corticosteroid treatment.

Discussion

Brain *et al* first observed the association between encephalopathy and autoimmune thyroid disease in 1966.² After a report of two cases,³ and the first case series,⁴ the condition was increasingly recognised in the last decade.¹ The mean age of onset is 41 years (range 14 to 78), with a female to male preponderance of 5.6:1. The hallmarks of the condition are:

- An encephalopathy presenting as delirium or dementia, usually with neurological signs or seizures as listed above.
- Raised serum titres of thyroid microsomal or thyroglobulin antibody, usually in clinically euthyroid patients, but hypothyroid and hyperthyroid cases are reported.
- Usually steroid responsive, often dramatically so.

Depression and anxiety are common early symptoms, but psychosis and personality change can also be presenting features. Brain imaging is usually normal although MRI can show high signal lesions on T2 weighted images in the subcortical white matter.⁵ Cerebrospinal fluid protein is raised in 65% of cases and 15% have a CSF pleocytosis (maximum 169 leucocytes/mm³). Thyroid autoantibodies must be raised to make the diagnosis, although it must be remembered that these are raised in 3–4% of the population. Some investigators also suggest ultrasonography of the thyroid to detect a hypoechoic pattern.⁵ Clearly, with such a wide variety of presentations and no definitive tests the diagnosis must be made with caution, perhaps only after a careful trial of steroids. Spontaneous remissions and other causes of steroid respon-

Learning points

- Hashimoto's encephalopathy is an increasingly recognised cause of a wide variety of potentially serious neurological symptoms that usually respond dramatically to steroids.
- Patients are mostly clinically euthyroid in the presence of high titres of serum thyroid autoantibody.
- MRI of the head is usually normal but CSF protein is often raised. There is sometimes a CSF pleocytosis
- Caution must be exercised in keeping a low threshold for the diagnosis but also in not overdiagnosing the condition
- Always check serum thyroid autoantibodies in patients with undiagnosed delirium.

sive encephalopathy should be taken into account.

The pathogenesis is unknown. Most investigators¹⁻³ assume the presence of a cross reacting antigen in the central nervous system, perhaps producing an immune complex mediated vasculitis. Corticosteroids are the treatment of choice. Prednisolone doses of over 60 mg are usually used, although intravenous methylprednisolone and immunosuppressants such as azathioprine and methotrexate have also been employed successfully.

Hashimoto's encephalopathy is not yet widely known, and may be an underdiagnosed cause of acute confusion in the general medical ward. Given its protean manifestations and reversibility with treatment, a low threshold of suspicion is important. Thyroid autoantibodies should always be checked in cases of confusion where the diagnosis is not clear.

Final diagnosis

Hashimoto's encephalopathy

- 1 Seipelt M, Zerr I, Nau R, *et al*. Hashimoto's encephalitis as a differential diagnosis of Creutzfeldt-Jakob disease. *J Neurol Neurosurg Psychiatry* 1999;66:172-6.
- 2 Brain L, Jellinek EH, Ball K. Hashimoto's disease and encephalopathy. *Lancet* 1966;ii:512-14.
- 3 Thrush DC, Boddie HG. Episodic encephalopathy associated with thyroid disorders. *J Neurol Neurosurg Psychiatry* 1974;37:696-700.
- 4 Shaw PJ, Walls TJ, Newman PK, *et al*. Hashimoto's encephalopathy: a steroid-responsive disorder associated with high anti-thyroid antibody titers; report of 5 cases. *Neurology* 1991;41:228-33.
- 5 Bohnen NI, Parnell KJ, Harper CM. Reversible MRI findings in a patient with Hashimoto's encephalopathy. *Neurology* 1997;49:246-7.

A metabolic complication of pregnancy

Q1: What are the findings on the ultrasound in figs 1 and 2?

The ultrasound image of the kidneys (fig 1; p 55) shows marked bilateral renal medullary calcification (nephrocalcinosis). The ultrasound image of the parathyroids (p 55) shows a parathyroid adenoma with the Doppler signal produced by the blood flow to the adenoma.

Q2: How should this patient be managed?

This patient should have a parathyroidectomy during the second trimester.

OUTCOME IN THIS CASE

The patient's blood pressure remained well controlled on methyl dopa and at 20 weeks' gestation she had the parathyroid adenoma removed under general anaesthesia. The diagnosis was confirmed on histology. Her serum calcium fell to 2.34 mmol/l postoperatively and has since remained normal. She gave birth to a normal baby girl at term. Following surgery she remained normotensive, even after the methyl dopa was discontinued.

Discussion

Hyperparathyroidism during pregnancy is uncommon, with just over 100 cases reported since the first description by Hunter in 1931. The incidence is not known; however, in all women of child bearing age the annual incidence of new cases is said to be about 8/100 000 population.¹ This condition results in a 20–30% incidence of fetal or neonatal death and an incidence of complications during pregnancy exceeding 50% if untreated.² Physiological adjustment during pregnancy maintains calcium homeostasis despite increased requirements (approximately 30 g) for fetal skeletal development. Intact parathormone levels remain largely unchanged or diminish during pregnancy.³ Total serum calcium decreases, reflecting a fall in serum albumin. A consistent increase in maternal vitamin D3 levels with advancing gestation ensures that the fetal requirements for calcium are met through increased intestinal absorption of calcium.⁴ The clinical presentation of hyperparathyroidism during pregnancy is similar to that found in the general population, and many patients are asymptomatic. Untreated primary hyperparathyroidism increases the risk of fetal loss, neonatal morbidity (in particular tetany),

Box 1: Causes of nephrocalcinosis

- Medullary sponge kidney
- Primary hyperparathyroidism
- Hypercalciuria
- Hypervitaminosis D
- Sarcoidosis
- Fabry's disease
- Wilson's disease

Learning points**Hyperparathyroidism in pregnancy**

- Clinical presentation during pregnancy is similar to that found in the general population and it is sometimes diagnosed retrospectively following the birth of the baby.
- If untreated, it results in a substantial increase in morbidity and mortality in the newborn infant.
- Surgery during second trimester is the treatment of choice.

and mortality. None of the medical treatments presently available is safe in pregnancy. There have been anecdotal reports of the successful use of oral phosphate.⁵ Current recommendations for the treatment of hyperparathyroidism during pregnancy advocate surgery during the second trimester.⁶ Our patient underwent surgery without any adverse effect at 20 weeks. It is prudent to avoid surgery during the first trimester until the completion of organogenesis, and in the third trimester, when there is an increased risk of spontaneous labour. There is an association of hypertension with hyperparathyroidism, the cause of which is unknown. This patient's hypertension was cured following surgery. Nephrocalcinosis is known to result from primary hyperparathyroidism and it remains to be seen if it will resolve in this patient.

In conclusion, when hyperparathyroidism is suspected in pregnancy, efforts should be made to make an early definitive diagnosis so that surgery can be planned for the second trimester. In patients with parathyroid adenoma, surgery at this stage is usually associated with successful maternal and fetal outcomes.

1 Heath H, Hodgson SF, Kennedy MA. Primary hyperparathyroidism: incidence, morbidity, and potential economic impact in a community. *N Engl J Med* 1980;302:189–93.

2 Ludwig GD. Hyperparathyroidism in relation to pregnancy. *N Engl J Med* 1962;267:637–43.

3 Davis OK, Hawkins DS, Rubin LP, et al. Serum parathormone (PTH) in pregnant women determined by an immunoradiometric assay for intact PTH. *Clin Endocrinol Metab* 1988;67:850–2.

4 Reddy GS, Norman AW, Willis DM, et al. Regulation of vit D metabolism in normal human pregnancy. *Clin Endocrinol Metab* 1983;56:363.

5 Montoro MN, Collea JV, Mestman J. Management of hyperparathyroidism in pregnancy with oral phosphate therapy. *Obstet Gynecol* 1980;55:431–4.

6 NIH Consensus Development Conference Statement. *Diagnosis and management of asymptomatic primary hyperparathyroidism*. Bethesda, MD: National Institutes of Health; October 29–31, 1990.