

## SELF ASSESSMENT QUESTIONS

## A case of digital vasculitis

M A M Abbas, C S Arun, A N Gorsuch, E B Henderson

*Answers on p 723.***Conquest Hospital, St Leonards-on-Sea, East Sussex, UK**M A M Abbas  
C S Arun  
A N Gorsuch  
E B HendersonCorrespondence to:  
Dr M A M Abbas, Radiology  
Department, Royal Victoria  
Infirmary, Queen Victoria  
Road, Newcastle upon Tyne  
NE1 4LP, UKSubmitted 1 June 1999  
Accepted 18 August 1999

A 49 year old woman presented in June 1998 with left sided pleuritic chest pain, fever, night sweats, flitting arthralgia, and loss of appetite of three weeks' duration. She also complained of episodic numbness of her fingertips and later her toes and oral ulceration.

She was known to have had asthma for the past 24 years and to have had four episodes of arthralgia involving large joints in the last year.

On general examination, she was pyrexial ( $37.5^{\circ}\text{C}$ ) with evidence of digital vasculitis affecting the left index and middle finger nails (see figs 1 and 2). She had oral ulceration. There was no rash or any evidence of inflammatory arthritis. Examination of the peripheral nervous system revealed reduced power of her right plantar flexion and inversion of right foot. There was diminished sensation over the sole of the right foot and sensory loss affecting all fingertips.

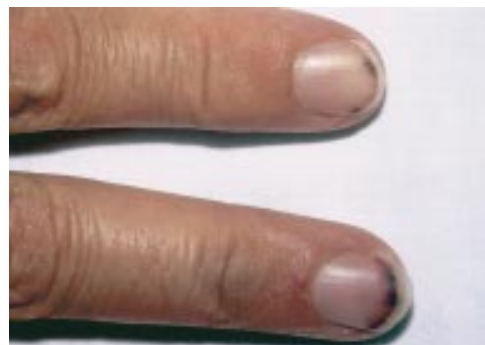

Figure 2 Vasculitic lesions affecting the left index and middle fingers.

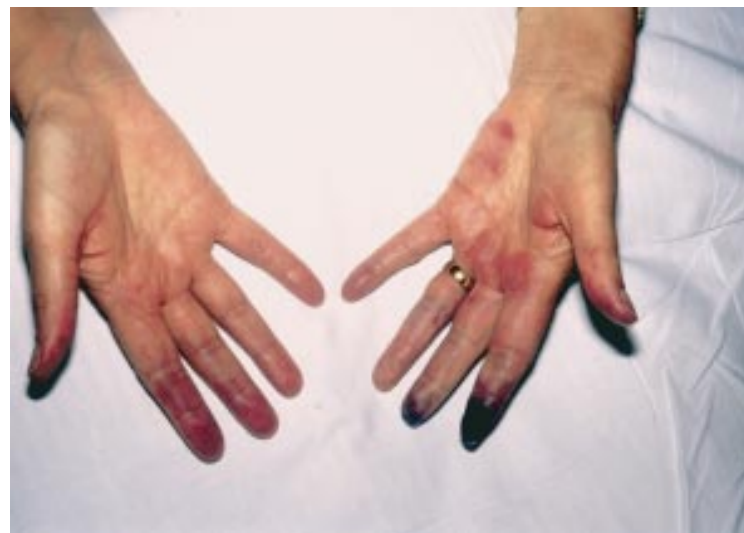

Figure 1 Digital vasculitic lesions.

Investigations on admission gave the following results: white cell count  $21.3 \times 10^9/\text{l}$ , eosinophils  $5.4 \times 10^9/\text{l}$ , neutrophils  $13.1 \times 10^9/\text{l}$ , haemoglobin  $128 \times \text{g/l}$ , platelets  $200 \times 10^9/\text{l}$ , serum C reactive protein  $145 \text{ mg/l}$ , and erythrocyte sedimentation rate  $74 \text{ mm/hour}$ . Her biochemical profile was normal, except for a moderately raised alkaline phosphatase of  $176 \text{ IU/l}$  and creatinine kinase of  $202 \text{ IU/l}$  with normal creatinine kinase myocardial bound isoenzyme.

Chest radiography showed diffuse patchy consolidation of both lungs. Spiral computed tomography of her chest showed a little patchy consolidation of upper lobes suggestive of vasculitis. An echocardiogram was normal.

Urinalysis revealed microhaematuria and proteinuria. A renal biopsy and angiogram were normal. Her latex, antineutrophil cytoplasmic antibodies, antinuclear antibodies, anticardiolipin antibody titres, and hepatitis B surface antigen were all negative. A ceretec scan was normal.

**Questions**

- (1) What is the most probable diagnosis?
- (2) What is the treatment?

## Abdominal wall thickening in a middle aged man

M Bhushan, R H Macdonald, M H Irving, C E M Griffiths

Answers on p 723.

**Hope Hospital,  
Salford, UK:  
Department of  
Dermatology**  
M Bhushan  
R H Macdonald  
C E M Griffiths

**Department of  
Surgery**  
M H Irving

Correspondence to:  
Dr M Bhushan,  
Dermatology Centre,  
University School of  
Medicine, Hope Hospital,  
Eccles Old Road, Salford  
M6 8HD, UK

Submitted 10 May 1999  
Accepted 18 August 1999

A 44 year old man presented to the surgical team with a three week history of a sensation of increasing tightness of the lower abdominal wall. There had been no obvious precipitating factors, clinical prodrome, or associated systemic symptoms. He had been previously well and took no regular medication of note. Initial inspection of the skin was unremarkable but palpation revealed a firm, non-tender induration of the skin ( $11 \times 4.5$  cm) around the umbilicus. The rest of the skin was unaffected. General examination was normal. A peripheral blood eosinophilia of  $1.5 \times 10^9/l$  (normal  $0.2-0.4 \times 10^9/l$ ) was noted. All other laboratory investigations including erythrocyte sedimentation rate, blood film, renal and hepatic function, and immunology screen were normal. Computed tomography and magnetic resonance scans of the abdomen were also reported as normal. An open biopsy, down to and including rectus sheath, was performed under general anaesthesia. Histology of the biopsy is shown in fig 1.

### Questions

- (1) What is the diagnosis?
- (2) What is the pathogenesis of this condition?

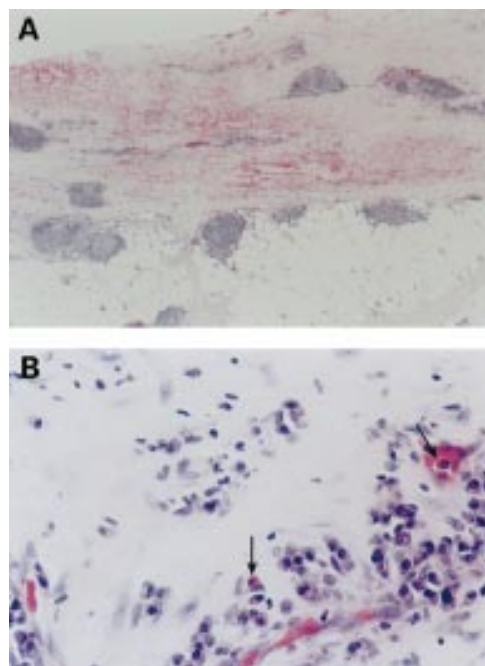


Figure 1 Histology of the skin biopsy (haematoxylin and eosin (A) magnification  $\times 25$  and (B) magnification  $\times 400$ ).

## A 71 year old man with a facial lesion

M Saab

Answers on p 724.

**Department of  
Accident and  
Emergency Medicine,  
Bury General  
Hospital, Walmersley  
Road, Bury BL9 6PG,  
UK**  
M Saab

Correspondence to:  
Dr Saab

Submitted 27 July 1999  
Accepted 8 October 1999

A 71 year old man (fig 1) was brought into the accident and emergency department by his two daughters. He had had a lesion on the left side of his face for five years and has refused to see a doctor. The lesion had become progressive over the past year and he was finally persuaded to seek medical attention.

### Questions

- (1) What is the diagnosis?
- (2) Discuss treatment for this condition

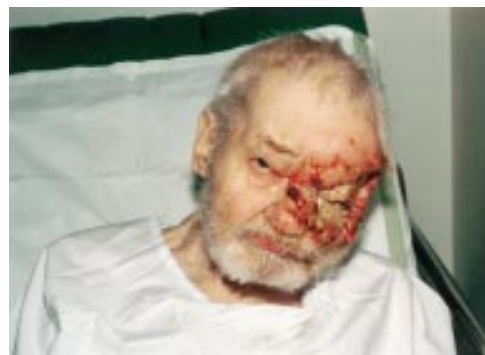

Figure 1 Facial lesion (reproduced with the patient's permission).

## The pale and limping child

S A W Fadilah, S K Cheong, S Shahdan

Answers on p 725.

**Faculty of Medicine,  
Universiti Kebangsaan  
Malaysia (UKM),  
Kuala Lumpur,  
Malaysia: Division of  
Haematology**  
S A W Fadilah  
S K Cheong

**Division of  
Rheumatology**  
S Shahdan

Correspondence to:  
Dr S Fadilah S Abdul Wahid,  
Department of Medicine,  
Hospital Universiti  
Kebangsaan Malaysia  
(HUKM), Jalan Yacob Latiff,  
Bandar Tun Razak, 56000  
Cheras, Kuala Lumpur,  
Malaysia  
(sfadilah@mail.hukm.ukm.my)

Submitted 23 April 1999  
Accepted 6 September 1999

A 13 year old girl presented with a two month history of recurrent episodes of arthritis of the metacarpophalangeal, wrist, knee, ankle, and metatarsophalangeal joints. The arthritis seemed to follow a migratory and symmetric pattern. The arthritis lasted for a week, resolved spontaneously, only to recur a few days later in another joint. Apart from having intermittent low grade fever, she was well. There was no history of sore throat, diarrhoea, or rash. On examination she was pyrexial (temperature 37.6°C). There was pallor, hepatomegaly (liver span measuring 17 cm), and moderate splenomegaly. The left and right first metacarpophalangeal joints were swollen and tender while there were residual swellings of the ankles. Initial investigations revealed a haemoglobin of 89 g/l, leucocyte count of  $7.3 \times 10^9/l$  with normal differential count and platelet count of  $82 \times 10^9/l$ . Erythrocyte sedimentation rate was 125 mm/hour. Levels of complement and immunoglobulins were normal. Rheumatoid factor, HLA B27, antinuclear, anti-double stranded DNA, and antistreptolysin O antibodies were negative. Culture results were unremarkable. The patient received non-steroidal anti-inflammatory drugs and two units of red cells. Two weeks later she returned with worsening of the arthritis and generalised lymphadenopathy. The platelet count dropped to  $16 \times 10^9/l$ . Peripheral blood and bone marrow smears are shown in fig 1A and B respectively.

### Questions

(1) What are the differential diagnoses of the arthritis?

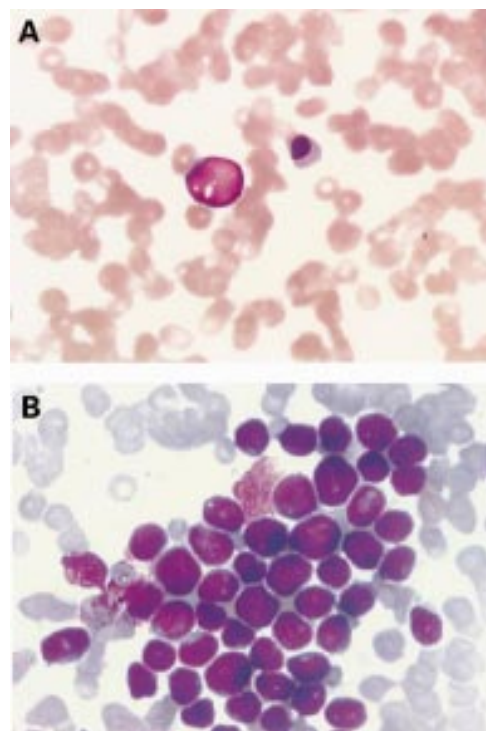


Figure 1 Smears of the peripheral blood (A) and bone marrow aspirate (B).

(2) What do the peripheral blood and bone marrow smears show?

## Rigidity, hyperthermia, and altered mental status

José María Calvo-Romero, María del Carmen Bonilla-Gracia, Juan Lucio Ramos-Salado, Pedro Bureo-Dacal

Answers on p 726.

**Internal Medicine  
Service, Infanta  
Cristina University  
Hospital, Badajoz,  
Spain**  
J M Calvo-Romero  
M del C Bonilla-Gracia  
J L Ramos-Salado  
P Bureo-Dacal

Correspondence to:  
José María Calvo Romero,  
Héroes de Cascorro 9, 31A,  
06004 Badajoz, Spain

Submitted 9 August 1999  
Accepted 27 October 1999

A 55 year old white woman presented with a two day history of severe rigidity, hyperthermia, altered mental status, and autonomic dysfunction. She had been treated for paranoid-type schizophrenia with zuclopentixol for two years. Thirteen weeks before, zuclopentixol had been discontinued and she started treatment with olanzapine (10 mg/day). Two weeks before, olanzapine was stopped because of worsening of her schizophrenic symptoms and she started taking zuclopentixol again (30 mg/day). She did not use any other medications or drugs. The clinical picture happened in winter. On admission, the oral temperature was 40.3°C, blood pressure 110/70 mm Hg, pulse rate 125 beats/min, and respiratory rate was

30/min. There was prominent diaphoresis. The neurological examination was difficult to complete because of the patient's uncooperativeness. She did not follow commands or answer questions. His face was symmetric, and she had severe rigidity in neck, arms, and legs. Deep tendon reflexes were symmetric and the results of the Babinski test were equivocal. Extraocular movements and fundi were normal.

### Questions

- (1) What is your differential diagnosis for this case and what investigations would you perform?
- (2) What is the treatment for this case?

## A rare cause of recurrent melaena in an elderly women

B Spencer, A Akpan, D King

Answers on p 727.

A 77 year old woman with a medical history of peptic ulcer disease and irritable bowel syndrome presented with an *Escherichia coli* septicaemia secondary to a urinary tract infection, which was treated successfully with intravenous cephalosporins. During her recovery she had an episode of melaena during which her haemoglobin dropped to 67 g/l from within the normal range. She was transfused, and was haemodynamically stable. Gastroscopy revealed atrophic gastritis, colonoscopy was normal to the splenic flexure, and a barium enema revealed diverticular disease. She had no further bleeding and was discharged. Four months later she was admitted with a further bleed, she was haemodynamically stable but her haemoglobin had dropped 30 g/l to 88 g/l. At this stage a diagnosis of angiodysplasia was considered but as she was no longer actively bleeding mesenteric angiography was not undertaken. She was transfused and discharged. Three months later she had a third episode of melaena, at this point further gastrointestinal imaging was performed.

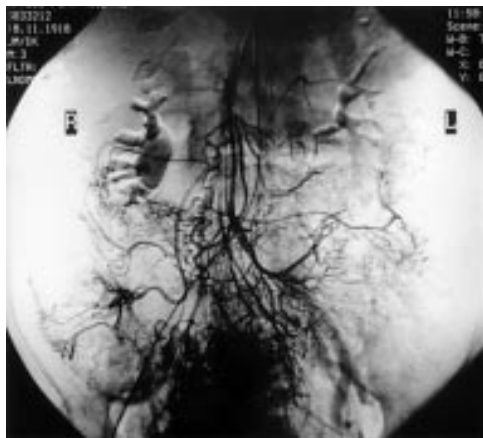

Figure 1 Mesenteric arteriogram.

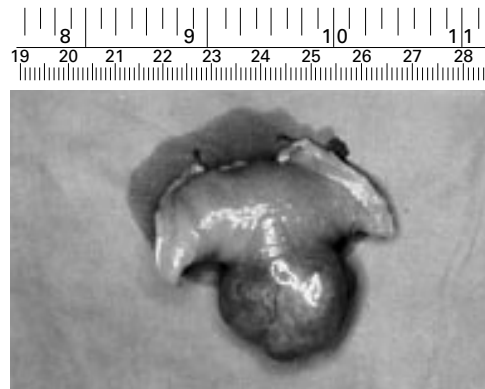

Figure 2 Laparotomy specimen.

At laparotomy there was a small  $4 \times 2$  cm polypoid lesion on the serosal surface of the mid-small bowel. Subsequent histological examination revealed a tumour with a low mitotic rate, composed of both smooth muscle spindles and pancreatic glandular elements; this was consistent with a benign small bowel myoepithelial hamartoma. The patient has remained well and has had no further bleeds.

### Questions

- (1) What is meant by the term “obscure gastrointestinal haemorrhage” and how would you investigate it?
- (2) What is shown in fig 1?
- (3) Figure 2 shows a laparotomy specimen consisting of a  $4 \times 2$  cm polypoid lesion on the serosal surface of the mid-small bowel. Histologically this is a myoepithelial hamartoma. What are hamartomas?

Department of  
Medicine for the  
Elderly, Wirral  
Hospital NHS Trust,  
Arrowe Park, Wirral,  
UK

B Spencer  
A Akpan  
D King

Correspondence to:  
Dr B Spencer, Countess of  
Chester Hospital, Countess  
of Chester Health Park,  
Liverpool Road, Chester  
CH2 1UL, UK

Submitted 26 August 1999  
Accepted 27 October 1999

## Abdominal lump in an infertile man

Answers on p 728.

B M Biswal, M Madhavan, S R Anas

**School of Medical Sciences, Universiti Sains Malaysia, Kelantan, Malaysia:**  
**Division of Radiotherapy**  
 B M Biswal

**Division of Pathology**  
 M Madhavan

**Division of Surgery**  
 S R Anas

Correspondence to:  
 Dr B M Biswal, Department of Nuclear Medicine Radiotherapy and Oncology, School of Medical Sciences, Universiti Sains Malaysia, 16150 Kubang Kerian, Kelantan, Malaysia (b\_biswal@hotmail.com)

Submitted 5 July 1999  
 Accepted 27 October 1999

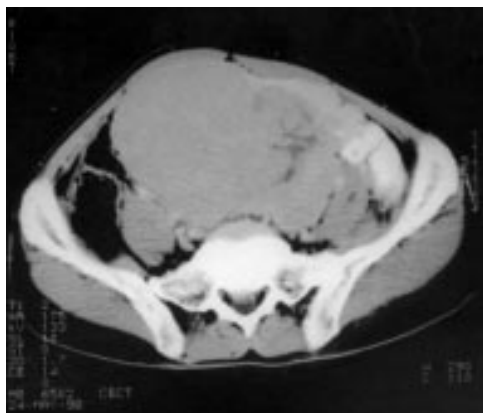

Figure 1 Contrast enhanced computed tomogram at the level of lower abdomen showing a bulky enhanced mass.

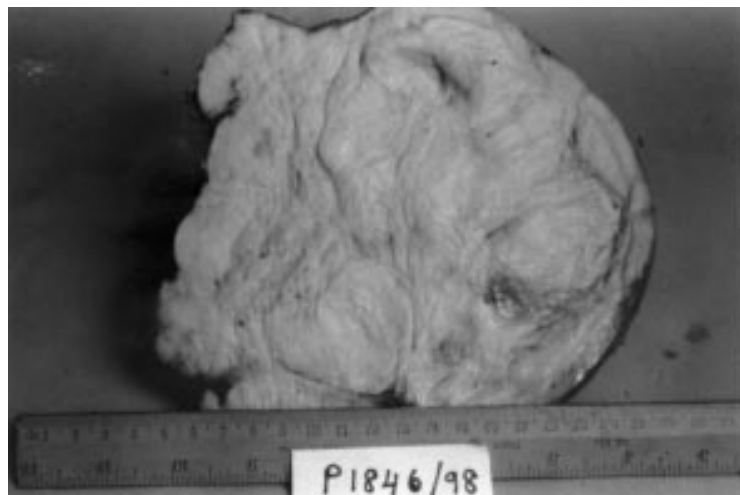

Figure 2 Cut section of the tumour is solid, homogenous and grey-white in colour.

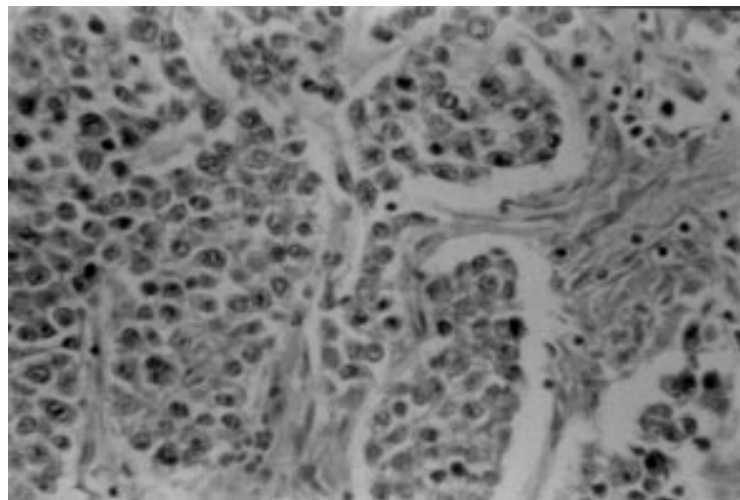


Figure 3 Lobules of monotonous tumour cells with clear cytoplasm and centrally located vesicular nucleus (haematoxylin and eosin, magnification  $\times 400$ ).

A 44 year sexually active man presented with pain in his abdomen, dysuria, haematuria, constipation, and a lump in the suprapubic area of over four months' duration. Further exploration into his medical history revealed that he had been married for 20 years but had no children and had been diagnosed as having primary infertility. Examination showed a man of average build, with a mass in the lower abdomen. The intra-abdominal mass measured  $12 \times 12$  cm and spanned from the umbilicus to pubis vertically and from left flank to across the midline horizontally. The consistency of the lump was firm to hard, non-tender, and fixed to underlying structures. Distension of the large bowel was evident above the mass. There was no testicle in the left scrotum and a small right testicle in the groin.

With a presumptive diagnosis of pelvic malignancy, complicated with intestinal obstruction, radiography of the abdomen was undertaken and this showed evidence of subacute intestinal obstruction. Gastrograffin enema x rays revealed a soft tissue mass adherent to the rectosigmoid junction suggestive of carcinoma of the urinary bladder. Subsequent contrast enhanced computed tomography of the abdomen and pelvis revealed an isodense soft tissue mass with areas of hypodensity arising from pelvis measuring  $12 \times 12 \times 12$  cm with minimal peripheral enhancement (fig 1). There was no definite cleavage between tumour and the bladder wall. Serum  $\alpha$ -fetoprotein and  $\beta$ -human chorionic gonadotrophin concentrations were within normal limits.

An explorative laparotomy was performed which revealed a large cystic tumour arising from retroperitoneal space of the pelvis pushing the sigmoid colon up and right. The above tumour was measuring  $10 \times 16$  cm in size with distended venous markings overlying. The tumour weighed 1.68 kg. Cut section of the mass showed a grey-white lobular mass with little areas of necrosis (fig 2). There were multiple lymph nodes in the mesentery and paraortic area. Microscopic examination showed uniform looking cells arranged in nests with intervening delicate fibrovascular stroma. The tumour cells were large and have clear cytoplasm. Periodic acid schiff stain for glycogen was strongly positive. The nuclei were centrally located, vesicular, and hyperchromatic, showing numerous mitotic figures (21 per 10 high power field) (fig 3). The sampled tissue from sigmoid colon, bladder, mesenteric and paraortic lymph nodes showed tumour infiltration.

### Questions

- (1) What is the probable diagnosis of this condition?
- (2) Which is the best treatment in this situation?
- (3) What is the chance of second cancer in the opposite testis?

## A vanishing pituitary mass

Answers on p 729.

N Norman Chan

A 26 year old music composer presented with sudden onset of frontal headache followed by an episode of witnessed tonic-clonic convulsion which lasted 10 minutes. He had bitten his tongue and was confused for 20 minutes. There was no visual disturbances. He was previously in good health without a history of epilepsy or other illnesses. There was no family history of epilepsy. His alcohol intake had been 5–10 units per week for the past eight years.

The patient had a normal BM of 6.8 when checked by the ambulance crew. On arrival in the accident and emergency department, physical examination was unremarkable. The patient became more alert and his Glasgow coma scale score was 15/15. His vital signs were normal with a blood pressure of 150/84 mm

Hg. There was no focal neurology or signs of meningism. Fundoscopy was normal and visual field was full on direct confrontation. Blood tests including blood glucose (5.0 mmol/l), electrolytes, liver function, and full blood count were all normal. A magnetic resonance imaging (MRI) scan of the skull was performed (fig 1, left). He did not receive any treatment and a repeat MRI scan was performed seven months later (fig 1, right).

### Questions

- (1) Describe the initial abnormality shown by the MRI scan (fig 1, left).
- (2) What does the follow up MRI scan show (fig 1, right)?
- (3) What is the most likely diagnosis?

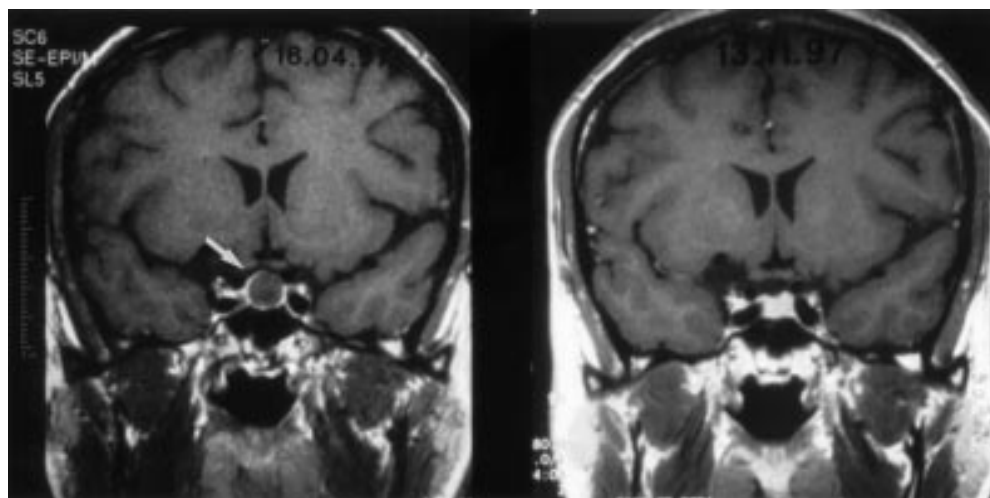


Figure 1 MRI scan on admission (left) and after seven months (right).

Department of  
Endocrinology,  
Imperial College  
School of Medicine,  
Charing Cross  
Hospital, London, UK

Correspondence to:  
Dr N N Chan, 81  
Sherbrooke Road, Fulham,  
London SW6 7QL, UK  
(NNKA Chan@aol.com)

Submitted 5 August 1999  
Accepted 29 October 1999

## Shortness of breath and diffuse chest pain

Answers on p 731.

S Singh, A A Lone, B A Khan, A K Khan, M M Wani

**Department of Accident and Emergency, Sher-i-Kashmir Institute of Medical Sciences, Soura, Srinagar, India**

S Singh  
A A Lone  
B A Khan  
A K Khan  
M M Wani

Correspondence to:  
Dr Surjit Singh, Nishat Medicate Sonwar, B B Cantit, Srinagar 190 004, J&K State, India

Submitted 27 April 1999  
Accepted 8 October 1999

A 60 year old man presented to the emergency medicine department of Sher-i-Kashmir Institute of Medical Sciences, Srinagar with a one day history of shortness of breath and diffuse chest pain aggravated by breathing. He had no history of trauma, fever, altered sensorium, syncope, cough, haemoptysis, weakness, or oliguria. He had a three month history of generalised aches and pains and easy fatigability for which he had received non-steroidal anti-inflammatory drugs and was not evaluated.

Clinical examination revealed moderate pallor, tachycardia, tachypnoea, a depressed anterior chest wall with sharp indentations around the mid-clavicular line on both sides, paradoxical motion of the anterior chest wall, and diffuse bone tenderness. There was no cyanosis, oedema, lymphadenopathy, or organomegaly, and cardiovascular and neurological variables were normal.

Preliminary investigations revealed a haemoglobin concentration of 80 g/l, a normocytic normochromic peripheral smear, total leucocytic count  $5.5 \times 10^9/l$ , and platelet count  $200 \times 10^9/l$ . Erythrocyte sedimentation rate was 65 mm/hour (Wintrobe's), serum urea nitrogen 26.5 mmol/l, creatinine 194.5  $\mu\text{mol/l}$ , calcium

2.9 mmol/l with a normal blood glucose, electrolytes (sodium, potassium), liver profile, alkaline phosphatase, and routine urine examination. Chest radiography revealed double fractures in the 4th, 5th, 6th, and 7th ribs and osteoporosis. Arterial blood gas analysis showed a pH of 7.45, carbon dioxide tension 4.67 kPa, oxygen tension 9.33 kPa, and bicarbonate 19 mmol/l with a saturation of 90%. Further evaluation of the patient revealed presence of Bence Jones protein in the urine (Kappa), presence of M band (quality not determined) on serum and urine electrophoresis, and serum immunoglobulin concentrations of IgG 36 g/l (normal 8–15 g/l), IgA 1.3 g/l (0.9–3.2 g/l), and IgM 0.8 g/l (0.45–1.5 g/l). A skeletal survey revealed multiple lytic lesions in the skull, diffuse osteoporosis, and compression fracture at T4, T5, L4, and L5 vertebrae. Bone marrow examination revealed 35% plasmacytosis.

### Questions

- (1) What is the diagnosis?
- (2) What is the primary disease?
- (3) What are the causes of flail chest?
- (4) What are the treatment options?

Answers on p 731.

## An elderly man with muscle cramps

**Royal Liverpool and Broadgreen University Hospital, Prescott Street, Liverpool L7 8XP, UK**

N Younis  
I F Casson

Correspondence to:  
Dr Younis  
(naveedy@tinyonline.co.uk)

Submitted 1 June 1999  
Accepted 8 October 1999

N Younis, I F Casson

A 60 year old man presented to the emergency department with slurring of speech and generalised weakness associated with cramps affecting his hands. He had no medical illnesses apart from a left sided cataract removed a year ago. A 12 lead electrocardiogram was performed.

### Questions

- (1) What is the abnormality on the 12 lead electrocardiogram (fig 1)?
- (2) What are the possible causes of the abnormality of the electrocardiogram?
- (3) What is the likely diagnosis?

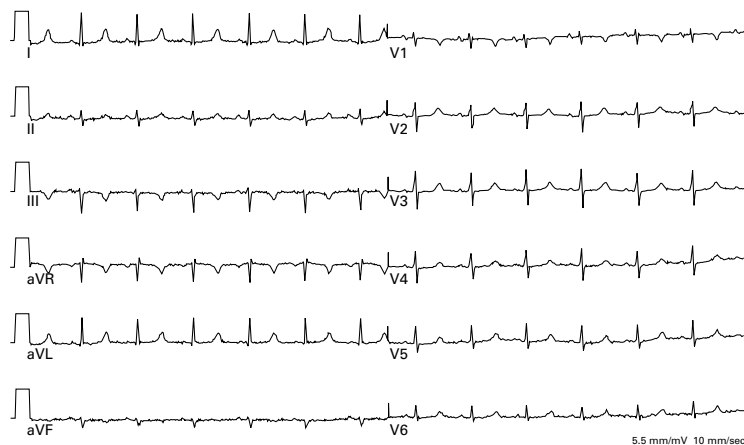


Figure 1 Electrocardiogram.

## Left kidney mass in a 45 year old woman

Answers on p 733.

G Brancatelli, M Galia, G Sparacia, S Cusmà, R Lagalla

Department of  
Radiology "P  
Cignolini", University  
of Palermo, Via Del  
Vespro 127, I-90127,  
Palermo, Italy  
G Brancatelli  
M Galia  
G Sparacia  
S Cusmà  
R Lagalla

Correspondence to:  
Dr M Galia, Via Monte San  
Calogero 5, I-90146,  
Palermo, Italy  
gbranca@yahoo.com

Submitted 5 August 1999

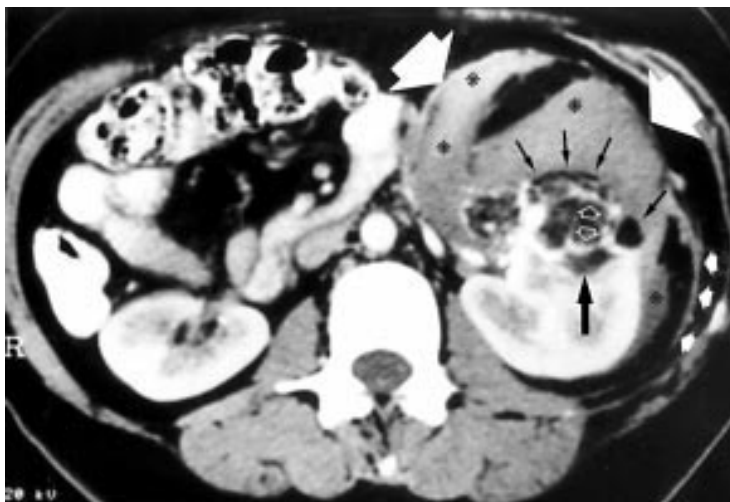


Figure 1 Abdominal contrast enhanced computed tomogram.

A 45 year old woman presented with left sided flank pain, anaemia, and severe hypotension. On clinical examination, a subcutaneous mass was palpated in the left flank and hypocondrium.

Renal urography showed the presence of a large mass with dislocation and compression of left kidney pelvis. Abdominal ultrasound re-

vealed a highly reflective lesion in the left kidney. Abdominal contrast enhanced computed tomography was performed (fig 1).

### Questions

- (1) What is the most likely diagnosis?
- (2) What is the treatment?



## SELF ASSESSMENT ANSWERS

### A case of digital vasculitis

#### Q1: What is the most probable diagnosis?

The diagnosis is Churg-Strauss syndrome on the basis of digital vasculitis, Raynaud's phenomenon, mild peripheral neuropathy, mononeuritis multiplex, marked eosinophilia, and a past history of asthma.

#### Q2: What is the treatment?

The treatment is steroids. Patients with poor prognostic features, such as myocardial and gastrointestinal involvement, can be treated with combined steroids and cyclophosphamide.

### Discussion

Churg-Strauss syndrome (CSS) is a granulomatous vasculitis affecting multiple organ systems. It may resemble polyarteritis nodosa except for the high degree of lung involvement, vasculitis of mainly small sized vessels, extravascular granuloma formation, eosinophilic tissue infiltration, peripheral eosinophilia, and a strong association with severe asthma.<sup>1</sup>

The American College of Rheumatology has proposed six criteria for the diagnosis of CSS. Four of the six criteria are necessary for a diagnosis with 85% sensitivity and 99.7% specificity. These criteria include a history of asthma, the presence of eosinophilia  $>1500/\text{mm}^3$ , paranasal sinusitis, pulmonary infiltrates seen on radiography, histological proof of vasculitis, and mononeuritis multiplex.<sup>2</sup>

Asthma is the most frequently observed presentation but may precede the development of systemic vasculitis by up to 30 years.<sup>3</sup> Mononeuritis multiplex is the second commonest manifestation. Other common features are fever, malaise, weight loss, fleeting pulmonary infiltrates, arthralgia, and gastrointestinal involvement. Cardiac involvement is seen in one third of patients, with myocardial and endocardial involvement being common. Skin lesions are seen in 70% of cases, usually in the form of purpura, cutaneous and subcutaneous nodules. Glomerular involvement is rare. Gastrointestinal tract involvement is due to mesenteric vasculitis and usually presents with abdominal pain.<sup>3,4</sup>

Although CSS may be readily diagnosed on clinical grounds, histological confirmation should always be sought. The classical picture consists of necrotising vasculitis, eosinophilic tissue infiltration, and extravascular granulomas, but it is only found in a minority of patients and is not pathognomonic of CSS.<sup>5</sup>

Antineutrophil cytoplasmic antibodies, especially antilysozyme, are positive in 60%–75% of patients with CSS.<sup>5</sup>

The prognosis is poor with 25% five year survival if untreated. Treatment with steroids dramatically increases the chance of survival. Patients with poor prognostic features, such as myocardial and gastrointestinal involvement,

should be treated with combined steroids and cyclophosphamide.

Our patient had four out of the six American College of Rheumatology criteria, namely asthma, eosinophilia, pulmonary infiltrates, and mononeuritis multiplex. Her cardiac involvement warranted the use of cyclophosphamide in addition to methylprednisolone.

### Final diagnosis

Churg-Strauss syndrome.

- 1 Churg J, Strauss L. Allergic granulomatosis, allergic angiitis and polyarteritis nodosa. *Am J Pathol* 1951;27:277–301.
- 2 Masi AT, Hunder GG, Lie JT, et al. The American College of Rheumatology 1990 criteria for the classification of Churg-Strauss syndrome (allergic granulomatosis and angiitis). *Arthritis Rheum* 1990;33:1094–100.
- 3 Chumbley LC, Cohen P, Gayraud M, et al. Churg-Strauss syndrome. Clinical study and long term follow-up of 96 patients. *Medicine* 1999;78:26–37.
- 4 Lanham JG, Elkon KB, Pusey CD, et al. Systemic vasculitis with asthma and eosinophilia: a clinical approach to the Churg-Strauss syndrome. *Medicine* 1984;63:65–81.
- 5 Reid AJC, Harrison BDW, Watts RA, et al. Churg-Strauss syndrome in a district hospital. *Q J Med* 1998;91:219–29.

### Abdominal wall thickening in a middle aged man

#### Q1: What is the diagnosis?

The biopsy (see p 716) shows marked thickening of the fascia throughout the subcutaneous compartment associated with a chronic inflammatory infiltrate consisting of lymphocytes and plasma cells. Lymphoid follicle formation is also seen. Scattered eosinophils (arrowed) are noted on higher magnification. There is no vasculitis, panniculitis, or fat necrosis. In view of the tissue eosinophilia and initially raised eosinophil count, the diagnosis is eosinophilic fasciitis. A year after his operation the patient is being managed conservatively. There has been spontaneous resolution of his signs (the affected area now measures  $6.5 \times 2$  cm). His eosinophil count returned to normal within three months of his operation and has remained so since this time.

#### Q2: What is the pathogenesis of this condition?

Eosinophilic fasciitis is considered to be an immunologically mediated disease. A key point in the history is that approximately half of the patients will describe strenuous physical exertion before development of clinical signs and symptoms. It is hypothesised that such exertion might damage muscle, rendering it antigenic and causing an immune response. Such a response is reflected by the dense chronic inflammatory infiltrate, which may include eosinophils in the early stages of the condition, seen within the fascial compartment. These tissue eosinophils are considered to play a central part in the formation of the fascial fibrosis which is the hallmark of this condition.<sup>1</sup>

## Discussion

Eosinophilic fasciitis presents in the third to fifth decade of life with stiffness, swelling, and non-pitting oedema of the skin. Primary involvement of the fascia causes retraction of the subcutaneous tissue which is most evident between muscle groups (the “groove sign”) and along the course of veins (“sunken veins”). In an extensive review by Moore and Zuckner,<sup>2</sup> the upper limbs were involved in 89% of cases, with characteristic sparing of the hands differentiating it from systemic sclerosis. To our knowledge, only one previous case where the findings have been confined to the abdomen, and where the extremities have not also been involved, has been reported in the literature.<sup>3</sup>

A peripheral blood eosinophilia is seen in over 90% of cases, often with values greater than  $1 \times 10^9/l$ , but there is no clear correlation between clinical activity of disease and the total count. Occasionally, raised erythrocyte sedimentation rate, raised antinuclear antibodies, and hypergammaglobulinaemia are also seen but these are considered of less diagnostic value compared with the findings on an incisional full thickness biopsy involving skin, fat, and fascia in continuity.<sup>4</sup>

In view of the fact that eosinophilic fasciitis is considered to be an immunologically mediated disease, the treatment of choice in progressive disease, particularly if there are associated contractures, is prednisolone (40–60 mg daily). Other protocols described in the literature include methotrexate, hydroxychloroquine, cyclosporin, and cimetidine. Evaluation of therapy remains difficult however, as patients often show spontaneous remission over two to five years.<sup>5</sup> Follow up of these patients is necessary as haematological malignancies in association with eosinophilic fasciitis have been reported and are associated with a poorer prognosis.

Clinically, our patient presented with a short history of an infiltrative process affecting the connective tissues of the lower abdominal wall. A possible diagnosis was scleroderma, either localised or with visceral involvement. In addition, a neoplastic process, either a primary lesion such as fibrosarcoma or liposarcoma or secondary spread due to invasion by a scirrhous intra-abdominal malignancy necessitated exclusion by exploratory surgery. An image directed needle biopsy could not be performed in view of the negative radiological results. An open surgical procedure was decided upon as it would provide an adequately sized biopsy for intraoperative histological examination. It also gave the surgeon an opportunity to treat any microscopically confirmed tumour at the same time by wide local resection. The final diagnosis of eosinophilic fasciitis is associated with a more favourable prognosis compared with soft tissue tumours and systemic sclerosis. Eosinophilic fasciitis not only responds favourably to systemic therapies, such as corticosteroids, but also may spontaneously resolve, as illustrated by our case.

## Learning points

- The association of thickening of the skin and a peripheral blood eosinophilia should raise the possibility of eosinophilic fasciitis
- A deep biopsy down to and including fascia is required to establish the diagnosis
- Eosinophilic fasciitis can affect sites other than the limbs
- Long term prognosis of this condition is often favourable

## Final diagnosis

Eosinophilic fasciitis.

- 1 Birkland TP, Cheavens MD, Pincus SH. Human eosinophils stimulate DNA synthesis and matrix production in dermal fibroblasts. *Arch Derm Res* 1994;286:312–8.
- 2 Moore TL, Zuckner J. Eosinophilic fasciitis. *Semin Arthritis Rheum* 1980;9:228–35.
- 3 Fleishmajer R, Jacotot AB, Shore S, et al. Scleroderma, eosinophilia and diffuse fasciitis. *Arch Dermatol* 1978;114:1320–5.
- 4 Rodnan GP, di Bartolomeo, Medsger TA, et al. Eosinophilic fasciitis: report of seven cases of a newly recognised scleroderma-like syndrome. *Arthritis Rheum* 1975;18:422–3.
- 5 Lakanpal S, Ginsburg WW, Michet CJ, et al. Eosinophilic fasciitis: clinical spectrum and therapeutic response in 52 cases. *Semin Arthritis Rheum* 1988;17:221–31.

## A 71 year old man with a facial lesion

### Q1: What is the diagnosis?

The diagnosis is basal cell carcinoma; this is the most common form of skin cancer. Basal cell carcinoma is the commonest malignancy in white people with incidence rates of 300/100 000 reported in the USA.<sup>1</sup> Rates are increasing at over 10% per year leading to a lifetime risk of 30%. Although mortality is low, the disease is responsible for considerable morbidity and places a substantial burden on the health service provision in the UK. It is induced by chronic sun exposure. The incidence is rising, especially in younger age groups and although they do not metastasise, they are a major source of morbidity due to local invasion and tissue destruction. Grossly neglected lesions may invade underlying cartilage and bone. The criteria for aggressiveness appear to be<sup>2</sup>: (1) initial diameter greater than 1 cm, (2) more than two recurrences despite all tentative conclusions of adequate treatment and (3) extension to any extracutaneous structure.

There are four types: nodular, cystic, morpoeic, and superficial. All present as slowly enlarging, glistening, yellow or white lesions which often appear translucent with fine telangiectasia coursing across the surface. The morpoeic type can resemble a scar.

### Q2: Discuss treatment for this condition

Any suspicious lesion should be referred to a dermatology department for biopsy and appropriate treatment planning.<sup>3</sup> Lesions situated on important anatomical areas (for example, medial and lateral canthi, nose, and ears) are especially important to pick up as they can

cause extensive tissue destruction with profound cosmetic disability if neglected.

### Final diagnosis

Basal cell carcinoma.

- 1 Lear JT, Smith AG. Basal cell carcinoma. *Postgrad Med J* 1997;73:538–42.
- 2 Vico P, Fourez T, Nemeč E, *et al.* Aggressive basal cell carcinoma of head and neck areas. *Eur J Surg Oncol* 1995;21:490–7.
- 3 Rowe DE. Comparison of treatment modalities for basal cell carcinoma. *Clin Dermatol* 1995;13:617–20.

### The pale and limping child

#### Q1: What are the differential diagnoses of the arthritis?

Migratory arthritis among children typically is described in acute rheumatic fever. Generally multiple joints are involved in an asymmetric pattern and the arthritis often subsides within a few days only to reappear in other joints over the next few days or weeks. If single joints are involved for more than a few days or weeks, other possible causes of arthritis, such as the systemic form of juvenile chronic arthritis (JCA), systemic lupus erythematosus, and septic arthritis should be considered. In our patient, even though the site and the migratory nature of the joint involvement are typical of rheumatic fever, the relatively prolonged joint symptoms are unusual for rheumatic fever. Moreover, the marked anaemia, negative anti-streptolysin O antibodies and absence of carditis, chorea, or subcutaneous nodules make this diagnosis less likely. The patient's fever, generalised lymphadenopathy, hepatosplenomegaly, and anaemia are consistent for systemic onset JCA (Still's disease) or acute leukaemia. On the contrary, in systemic JCA there is characteristically thrombocytosis and leucocytosis with a neutrophilic predominance and thus the initial thrombocytopenia would be against this diagnosis. In our patient, the normal white cell count, thrombocytopenia and a poor response to conventional antirheumatic treatment have cast considerable doubt upon the diagnosis of Still's disease. Arthritis is a known manifestation of acute leukaemia but has rarely been described with a migratory pattern.

#### Q2: What do the peripheral blood and bone marrow smears show?

Microscopic examination of the peripheral blood smears (fig 1A, see p 717) shows prominent leucoerythroblastosis with presence of 30% lymphoblasts and severe thrombocytopenia. The bone marrow (fig 1B, see p 717) is heavily infiltrated by lymphoblasts constituting 95% of nucleated cells and immunophenotyping study confirmed the diagnosis of precursor B cell acute lymphoblastic leukaemia.

#### Follow up

The patient received induction treatment with vincristine, daunorubicin, L-asparaginase, and prednisolone that resulted in complete haematological remission. The joint symptom settled rapidly after initiation of antileukaemic therapy and did not recur.

#### Learning points

- Children with a diverse group of malignancies including leukaemia, may first present to the paediatric rheumatologist
- Although uncommon, arthritis may be the first symptom of leukaemia in children
- Acute leukaemia remains an important differential diagnosis in children presenting with musculoskeletal pain and/or arthritis as delayed diagnosis and treatment could have a deleterious impact on prognosis.
- Acute leukaemia is a great mimic of many diseases
- Bone marrow study should be considered in all patients with unexplained anaemia and thrombocytopenia even in the absence of blasts in the peripheral blood

#### Discussion

Although this is an interesting and previously recognised association of arthritis and leukaemia, most children with leukaemia do not present in this way, and conversely most children with a referral diagnosis of JCA probably have this diagnosis or a related connective tissue or vasculitic disorder, or possibly chronic fatigue syndrome, rather than leukaemia. Nevertheless, the multifarious presentations of malignant disorders in children should always be borne in mind, and in this case the initial thrombocytopenia is a key finding. Hence, leukaemia and other childhood malignancies remain important differential diagnoses in children presenting with musculoskeletal pain and/or arthritis. When it is the sole clinical finding, the diagnosis of JCA may be made initially and hence delay diagnosis of the underlying malignancy. In one study, three of 30 children (10%) referred for JCA had leukaemia (two had acute lymphoblastic leukaemia and one acute myeloblastic leukaemia),<sup>1</sup> although this would not be as common in most series. All three patients had slight anaemia, normal to slightly reduced platelet count, mild neutropenia, and absence of blasts in the peripheral blood. In another study, nine (11.6%) of the 77 children studied in an orthopaedic clinic presented with the chief complaint of a limp and no history of trauma and were subsequently diagnosed with leukaemia.<sup>2</sup> Raised erythrocyte sedimentation rate, anaemia, neutropenia, lymphocytosis, and thrombocytopenia were frequent manifestations among the patients. In general, initial articular and extra-articular symptoms are not helpful in differentiating leukaemic arthropathy from JCA. However, distinctive features suggesting a paraneoplastic arthritis were prominent thrombocytopenia, absence of neutrophilia, early significant osteopenia, and lytic bone lesions. The exact mechanism of development of arthritis in acute leukaemia is unknown. Leukaemic cells

have been detected in the synovial fluid and histologic examination revealed proliferation into the synovium. Interleukin-1 $\beta$  secreted in great amounts by leukaemic B cells appears to be the major cytokine that mediates joint destruction in leukaemic arthritis. Human T cell leukaemia virus type 1, initially found as a causative agent for adult T cell leukaemia, has been lately proposed as a causative virus for several autoimmune disorders. The relationship between arthritis and this virus was clearly proved by epidemiological study. The transactivating gene of this virus, tax, is responsible for proliferation of synovial cells.<sup>3</sup>

Although arthritis is a known manifestation of haematological malignancies but migratory polyarthritis is unusual. Apart from this patient there have been only two reported cases of migratory polyarthritis subsequent to T cell lymphoma<sup>4</sup> and myelofibrosis.<sup>5</sup>

### Final diagnosis

Precursor B cell acute lymphoblastic leukaemia.

- 1 Jung A, Nielsen SM. Arthritis as first symptom of leukaemia in children. *Ugeskr Laeger* 1998;160:2889–90.
- 2 Tuten HR, Gabos PG, Kumar SJ, et al. The limping child: a manifestation of acute leukaemia. *J Pediatr Orthop* 1998;18:625–9.
- 3 Hasunuma T, Sumida T, Nishioka K. Human T cell leukaemia virus type-1 and rheumatoid arthritis. *Int Rev Immunol* 1998;17:291–307.
- 4 Brouwer RE, Kluin-Nelemans JC, Niezen RA, et al. A 26-year-old woman with fever, migratory polyarthritis, and pericarditis subsequent to a T cell-lymphoma. *Ann Hematol* 1997;75:71–7.
- 5 Agus B, Weintraub HS. Myelofibrosis associated with migratory polyarthritis and serositis. *J Rheumatol* 1986;13:476–7.

### Rigidity, hyperthermia, and altered mental status

#### Q1: What is your differential diagnosis for this case and what investigations would you perform?

This patient presented with the criteria for diagnosis of neuroleptic malignant syndrome (NMS).<sup>1,2</sup> She had hyperthermia, severe extrapyramidal effects, and autonomic dysfunction. Medical conditions such as bacterial meningitis, encephalitis, pneumonia, thyroid storm, or heat stroke may cause a similar syndrome. The coincidental occurrence of these medical conditions with extrapyramidal neuroleptic induced parkinsonism could lead to an erroneous diagnosis of NMS with disastrous consequences.<sup>1,2</sup> Furthermore, other drugs may cause similar syndromes, such as anticholinergic syndrome, serotonin syndrome, and cocaine overdose.<sup>1,2</sup>

Rhabdomyolysis is a characteristic laboratory finding in NMS due to prolonged muscle contraction, but a raised blood creatine kinase also occurs in other disorders.

The serum level of creatine kinase was 7547 U/l, creatine kinase MB fraction 127 U/l, lactate dehydrogenase 863 U/l, and the aspartate aminotransferase was 267 U/l. Other blood chemical values were normal. A complete blood count revealed a leucocyte count of  $12.3 \times 10^9/l$ , with 64% neutrophils. An electrocar-

diogram demonstrated sinus tachycardia. Radiographs of the chest and computed tomography study of the brain showed normal findings. The plasma free thyroxine and thyrotrophin were also normal. A urine toxicology screen for anticholinergic, serotonin, and opioid drugs was negative. A lumbar puncture yielded a normal cerebrospinal fluid with negative culture. Blood and urine cultures were negative.

#### Q2: What is the therapy for this case?

On admission, zuclopentixol was discontinued and the patient was treated with rehydration, antipyretics, artificial cooling, measures to maintain the blood pressure, and bromocriptine by nasogastric tube (30 mg/day). Two days after, the patient was afebrile and the rigidity and the autonomic dysfunction had disappeared, and the mental status was normal. Six days after admission, the serum level of creatine kinase, lactate dehydrogenase, and aspartate aminotransferase normalised.

Dantrolene and dopaminergic therapy with agents such as L-dopa, bromocriptine, or amantadine by nasogastric tube are thought to speed up the recovery of NMS.<sup>1,2</sup> However, whether the duration of NMS is shortened or not by these drugs has not been established because no prospective randomised controlled trial has been carried out. About a third of patients will develop another NMS, and this is particularly likely if neuroleptic therapy is reinstated within two weeks of the resolution of the acute episode.<sup>1,2</sup>

### Discussion

Our patient had discontinued treatment with olanzapine two weeks before and then started zuclopentixol again. The NMS in this patient was probably caused by the retreatment with zuclopentixol. The role of olanzapine withdrawal is uncertain. Clozapine and olanzapine are members of the thienobenzodiazepine class of serotonin-dopamine antagonists which have potent 5-HT<sub>2</sub> and weaker dopamine (D<sub>1</sub> and D<sub>2</sub>) receptor binding properties. Although these new antipsychotic agents have much fewer extrapyramidal symptoms, there is still the possibility of NMS.<sup>3,4</sup> About 90% of patients experience NMS within 10 days of starting an antipsychotic.<sup>1</sup> This syndrome has occurred during the withdrawal of such dopamine agonists as carbidopa, levodopa, amantadine, and bromocriptine and seldom during the withdrawal of neuroleptics.<sup>5</sup> A case of catatonia and NMS after abrupt clozapine withdrawal has been published.<sup>6</sup> NMS after neuroleptic discontinuation may be attributed to an imbalance in the dopaminergic system. Drug induced parkinsonism and NMS could represent two ends of a spectrum, with intermediate or partial forms of extrapyramidal reactions. Sudden and profound central dopaminergic blockade is the most favoured hypothesis for the pathogenesis of NMS.<sup>1,2</sup>

The mortality rate in NMS appears to be dropping to about 10%–20% from around 40%.<sup>7</sup> Most patients with NMS should be transferred to an intensive care unit.<sup>1,2</sup> Our

**Learning points**

- Criteria for diagnosis of neuroleptic malignant syndrome (NMS) are hyperthermia in the absence of another known cause, severe extrapyramidal effects, rhabdomyolysis, and autonomic dysfunction
- Thyroid storm, heat stroke, anticholinergic syndrome, serotonin syndrome, and cocaine overdosage may cause similar syndromes
- NMS has occurred during the withdrawal of such dopamine agonists as carbidopa, levodopa, amantadine, and bromocriptine and seldom during the withdrawal of neuroleptics

patient's clinical status did not allow her to be monitored in this environment.

**Final diagnosis**

Neuroleptic malignant syndrome probably caused by retreatment with zuclopentixol.

- 1 Caroff SN, Mann SC. Neuroleptic malignant syndrome. *Med Clin North Am* 1993;77:185–202.
- 2 Balzan MV. The neuroleptic malignant syndrome: a logical approach to the patient with temperature and rigidity. *Postgrad Med J* 1998;74:72–6.
- 3 Casey DE. Side effects profiles of new antipsychotic agents. *J Clin Psychiatry* 1996;57(suppl 11):40–5.
- 4 Filice GA, McDougall BC, Ercan-Fang N, et al. Neuroleptic malignant syndrome associated with olanzapine. *Ann Pharmacother* 1998;32:1158–9.
- 5 Amore M, Zazzeri N. Neuroleptic malignant syndrome after neuroleptic discontinuation. *Prog Neuropsychopharmacol Biol Psychiatry* 1995;19:1323–34.
- 6 Lee JW, Robertson S. Clozapine withdrawal catatonia and neuroleptic malignant syndrome: a case report. *Ann Clin Psychiatry* 1997;9:165–9.
- 7 Bristow MF, Kohen D. How malignant is the neuroleptic malignant syndrome. *BMJ* 1993;307:1223–4.

**A rare cause of recurrent melena in an elderly women****Q1: What is meant by the term “obscure gastrointestinal haemorrhage” and how would you investigate it?**

In 5% of cases of gastrointestinal bleeding the cause cannot be identified by standard investigations; these would usually include a gastroscopy, colonoscopy and barium enema, and small bowel series. These unidentifiable bleeds are often referred to as obscure gastrointestinal bleeds.<sup>1</sup>

Small intestinal contrast radiology is abnormal in 60%–70% of small bowel tumours and diagnostic in 30%–40% of cases. Enteroclysis or intubated small bowel studies show more lesions than conventional barium follow through, probably because the more dilute barium solution allows smaller filling defects to be recognised.<sup>2</sup> These should be performed before angiography, which itself may be diagnostic even in the absence of acute bleed by the presence of a tumour blush.

Small bowel enteroscopy is a new technique with increasing importance in potentially diagnosing and treating small bowel lesions. There are two types: push and sonde enteroscopy.<sup>3</sup> Push enteroscopy entails peroral insertion of a

long endoscope, and it allows for thorough examination of the distal duodenum and proximal jejunum. Sonde enteroscopy involves placement of a long, small calibre endoscope into the proximal small bowel: subsequent peristalsis carries the endoscope to the distal small intestine.<sup>4</sup> Abdominal computed tomography is of little value in the primary diagnosis of small intestinal lesions as fluid and gas obscure the gut wall and obscure masses. It may, however, be a suitable investigation in the frail elderly intolerant of colonoscopy and barium enema in whom a significant malignant gut lesion needs to be excluded.<sup>5 6</sup>

**Q2: What is shown in fig 1 (see p 718)?**

Mesenteric arteriography shows the vascular flush of a tumour overlying the sacrum. This was considered to be a vascular lesion in the small bowel. Note the absence of leakage of contrast into the gut lumen typical of angiodyplasia.

**Q3: Figure 2 (see p 718) shows a laparotomy specimen consisting of a 4 × 2 cm polypoid lesion on the serosal surface of the mid-small bowel. Histologically this is a myoepithelial hamartoma. What are hamartomas?**

Hamartomas are one of the three major groups of developmental tumours; the other two groups are teratomas and embryomas. Hamartomas are tumour-like but primarily non-neoplastic malformations occurring during embryological development. They comprise a abnormal mixture of tissue, which is normal to the site of occurrence. Their capacity for growth normally parallels that of the host.<sup>7</sup> In this case the small bowel myoepithelial hamartoma was composed of dilated glandular elements lined by cuboidal epithelium and surrounded by muscle; some are of pancreatic origin. They may cause intestinal obstruction by intussusception or bleeding. As they are non-malignant lesions resection is curative.

**Discussion**

There are many causes of melaena and guided by the history and initial imaging investigations a diagnosis can be reached in the vast majority of cases. However in about 5% of cases of gastrointestinal bleeding the cause cannot be identified by standard investigations, which would usually include gastroscopy, colonoscopy and barium enema, and small bowel series. These unidentifiable bleeds are often referred to as obscure gastrointestinal bleeds. Obscure gastrointestinal bleeding is important for geriatricians as the two main causes—small bowel tumours and arteriovenous malformations—are more common in the elderly.<sup>8 9</sup> The number of cases of truly unidentifiable haemorrhage becomes ever smaller as new imaging techniques evolve.

The main causes of bleeding from sites within the small intestine are tumours; however these are uncommon. In addition they present a diagnostic challenge, with up to 75% of cases presenting as an emergency. In those patients who present non-acutely imaging proves to be

helpful in only half of the cases.<sup>10</sup> Malignancies of the small bowel have a combined incidence of 9.9 per million. The four most common histological types are malignant carcinoid, adenocarcinoma, lymphomas, and sarcomas.<sup>11</sup> Lymphomas often cause marked destruction to the intestinal wall so acute presentation with perforation or bleed is not uncommon. Adenocarcinomas are generally annular and constricting in nature and therefore obstruction and occult blood loss are not infrequent. Leiomyosarcomas, which arise from the muscle of the small bowel, represent 10% of malignant small bowel neoplasms<sup>12</sup> and are histologically often very difficult to distinguish from the benign leiomyoma. The benign tumours of the upper gastrointestinal tract, including the small intestine, are most frequently leiomyomas, adenomatous polyps, lipomas, or schwannomas, which are often incidental or present as haemorrhage or invagination.<sup>13</sup> A small bowel myoepithelial hamartoma is a rare cause of melanaemia in the elderly. We have found no other cases described in the literature. The only other reference to a myoepithelial hamartoma of the small bowel was a case of intussusception in a 2 year old.<sup>14</sup>

### Final diagnosis

#### Myoepithelial hamartoma.

The authors would like to thank Dr J Maggenis, Consultant Radiologist, and Mr J S Elkington, Consultant Surgeon, Wirral Hospital NHS Trust, for figures 1 and 2 respectively.

- Mujica VR, Barkin JS. Occult gastrointestinal bleeding: general overview and approach. *Gastrointest Endosc Clin N Am* 1996;6:833-45.
- Maglente DDT, Hall R, Miller RE, et al. Detection of surgical lesions of the small bowel by enteroclysis. *Am J Surg* 1984;197:226-9.
- Wayne JD. Enteroscopy. *Gastrointest Endosc* 1997;46:247-56.
- Landi B, Tkoub M, Gaudric M, et al. Diagnostic yield of push type enteroscopy in relation to indication. *Gut* 1998;42:421-5.
- Thompson WM, Halversen RA. Computed tomographic staging of gastrointestinal malignancies part II, the small bowel, colon and rectum. *Invest Radiol* 1987;22:96-105.
- Domjan J, Blaquiére R, Odurny A. Is minimal preparation computed tomography comparable with barium enema in elderly patients with colonic symptoms. *British Geriatrics Society Communications* 1998;27:27 (suppl 2).
- McGee, Issacson, Wright. *Oxford textbook of pathology*. Vol 1. Oxford: Oxford University Press, 1992.
- Boley SJ, Sammartano R, Adamas A, et al. On the nature and etiology vascular ectasias of the colon: degenerative lesions of aging. *Gastroenterology* 1977;72:650-60.
- Lewis BS, Kornblath A, Wayne JD. Small bowel tumours; yield of enteroscopy. *Gut* 1991;32:763-5.
- Baillie CT, Williams A. Small bowel tumours: a diagnostic challenge. *J R Coll Surg Edinb* 1994;39:8-12.
- Chow JS, Chen CC, Ahsan H, et al. A population-based study of the incidence of malignant small bowel tumours: SEER, 1973-1990. *Int J Epidemiol* 1996;25:722-8.
- Misiewicz JJ, Pounder RE, Venables CW. *Diseases of the gut and pancreas*. 2nd Ed. Blackwell Scientific Publications, 1994.
- Mendes da Costa P. Benign tumours of the upper gastrointestinal tract (stomach, duodenum, small bowel): a review of 178 surgical cases. Belgian multicentric study. *Acta Chir Belg* 1993;93:39-42.
- Gonzalez J, Marco A, Andujar M, et al. Myoepithelial hamartoma of the ileum: a rare cause of intestinal intussusception in children. *Eur J Pediatr Surg* 1995;5:303-4.

### Abdominal lump in an infertile man

#### Q1: What is the probable diagnosis of this condition?

The diagnosis was malignant transformation of the cryptorchid testis. A mass in the abdomen in a sexually active man with a cryptorchid tes-

tis strongly points towards the diagnosis of malignancy in the abnormal testis. The characteristic features of malignancy are a homogeneous tumour with grey-white colour on cut section and vascular markings over the tumour. The histological features of monotonous tumour cells in lobules with clear cytoplasm and a centrally located nucleus clinches the diagnosis of seminoma; this is the commonest histology in a cryptorchid testis. Moreover the associated computed tomogram evidence of lymphadenopathy supports the above diagnosis.

#### Q2: Which is the best treatment in this situation?

In case of locally advanced seminoma with surgical spill, associated mesenteric lymphadenopathy and visceral infiltration, the best initial treatment is combination chemotherapy. The preferred combination chemotherapy regimens are bleomycin, etoposide, and cis-platin (BEP) or cis-platin, vinblastine, and bleomycin. In case of residual disease after a full course of chemotherapy, the above area is supplemented with localised radiotherapy.

#### Q3: What is the chance of second cancer in the opposite testis?

The chance of developing malignancy on the opposite testis is extremely high among adults. Even after reposition of the cryptorchid testis, there is very minimal decrease in the incidence of a second malignancy. The usual incidence of developing malignancy in the opposite testis is around 20%. Hence where stringent follow up is a problem some surgeons prefer to advocate prophylactic orchietomy of the normal looking testis. The testis histologically demonstrates the features of hypoplastic or atrophic seminiferous tubules, thus supports infertility in cryptorchidism.

#### Further management

Due to the risk of second malignancy in the opposite testis, an elective orchietomy was done and on pathological evaluation found to have features of hypoplastic seminiferous tubules. He was then treated with the standard BEP chemotherapy regimen (that is, bleomycin 30 units intravenously on days 1, 8, and 15; etoposide 120 mg/m<sup>2</sup> on days 1-3, and cis-platin 100 mg/m<sup>2</sup> (total) as an intravenous infusion over three days. After three courses of the BEP regimen, the patient developed deterioration of creatinine clearance for which his chemotherapy was changed to the vincristine, actinomycin-D, and cyclophosphamide (VAC) regimen. Three more courses of the VAC (vincristine 1.4 mg/m<sup>2</sup> on days 1 and 8, actinomycin-D 500 µg on days 1-5, and cyclophosphamide 500 mg/m<sup>2</sup> on day 1 repeated every four weeks) regimen were given. The patient tolerated the above regimen well and was found to have clinical and radiological evidence of resolution of the disease nine months after treatment.

**Learning points**

- Cryptorchid testis is an aetiological factor for testicular tumour especially if it is abdominal
- Seminoma is the commonest histology in cryptorchid related malignancy
- Sometimes an undescended testis can manifest as a massive tumour with visceral invasion of acute abdomen
- Multiagent chemotherapy is very useful in abdominal testes complicated by seminoma
- A suspicion of intra-abdominal testicular tumour should be made while investigating a case of an infertile man with an abdominal mass

**Discussion**

Cryptorchidism is a known cause of testicular tumour. Genetic and hormonal influences affect the migration of testis from the abdomen to the scrotal sac through the inguinal canal. Moreover the availability of free oestrogen in the first trimester of pregnancy also influences the migration of the testis.<sup>1</sup> A high intra-abdominal temperature has been incriminated as the cause of carcinogenesis in the testis.

The risk of developing testicular tumour in cryptorchid testis is 10–40 times higher than the normal testis. About 1%–5% of boys with undescended testes develop germ cell tumours.<sup>2</sup> The position of the undescended testis is related to the likelihood of carcinogenesis with the intra-abdominal location having the highest risk for malignancy.<sup>3</sup>

The normal testis of the cryptorchid patient carries a higher risk for malignant transformation. The cause of carcinogenesis is still an enigma. About 5%–20% of patients with a cryptorchid testis develop a testicular tumour on the opposite, normally descended, testis.<sup>4</sup> The incidence of malignancy is about 25% if the opposite testis has features of testicular atrophy.<sup>2,5</sup>

The histological transformation is a gradual process, which takes a long time to develop. Persistence of abnormal testis is associated with other structural abnormalities. There may be a decrease in the spermatogenesis, Leydig cell abnormality, and delay in the development of the Sertoli cells in the testis.<sup>6,7</sup> In our case too, there was evidence of sterility due to the testicular malfunction. Approximately all the malignancies in cryptorchid testis are seminomas.<sup>8</sup> But the spermatocytic seminoma<sup>9</sup> and teratomas<sup>10</sup> can very rarely occur in cryptorchid testis.

Painless enlargement of the testis, or abdominal mass, is the common mode of presentation in a cryptorchid testis.<sup>11</sup> But very rarely, an abdominal testicular tumour can cause acute abdomen, massive abdominal mass, pain, and haematuria because of adjacent visceral infiltration.<sup>12,13</sup> There are very few reports of malignant testicular tumour in cryptorchid testis in the pelvis, which mimicked acute appen-

ditis due to local infiltration.<sup>3</sup> This case also presented with bladder and sigmoid colon infiltration.

The management of the contralateral testis in cryptorchid patients is controversial and there are no firm guidelines for their management. Some authors suggest prophylactic orchiectomy of the uninvolved testis as the preferred option rather than stringent follow up of unreliable patients.<sup>11</sup> In our case we did an elective orchiectomy on the opposite testis in order to avoid the risk of carcinogenesis. The histopathology of the opposite testis revealed hypoplastic tubules. The management of an abdominal testis is very difficult. However we achieved complete response at nine months after treatment with combination chemotherapy.

In conclusion, the abdominal variant of cryptorchid testis is very rare and carries a high risk of malignant transformation to seminoma. Very rarely they can affect the nearby viscera presenting as acute abdomen. Early diagnosis with detection of an undescended testis and proper management can result in good long term cure.

**Final diagnosis**

Malignant transformation of the cryptorchid testis

- 1 Pottern LM, Brown LM, Hoover RN, *et al*. Testicular cancer risk among young men: role of cryptorchidism and inguinal hernia. *J Natl Cancer Inst* 1985;74:377–81.
- 2 Gilbert JB, Hamilton JB. Incidence and nature of tumor in ectopic testis. *Surg Gynecol Obstet* 1940;71:731–7.
- 3 Whitaker RH. The undescended testis—the risk of malignant degeneration. *Monogr Paediatr* 1981;12:104–8.
- 4 Batata M, Chu F, Harris B, *et al*. Testicular cancer in cryptorchids. *Cancer* 1982;49:1023–30.
- 5 Lipshultz LJ, Caminos-Torres R, Greenspan CS, *et al*. Testicular function after orchiopexy for unilaterally undescended testes. *N Engl J Med* 1976;295:15–18.
- 6 Sarma DP, Weilbaecher TG, Hatem AA. Seminoma arising in undescended testis clinically presenting as acute appendicitis. *J Surg Oncol* 1986;31:44–7.
- 7 Dow JA, Mostafi TK. Testicular tumor following orchiopexy. *South Med J* 1967;60:193–5.
- 8 Sulak MH. Testicular tumors. Classification of different histopathological types. *JAMA* 1970;213:91–3.
- 9 Schottenfeld D, Warshauer ME, Sherlock S, *et al*. The epidemiology of testicular cancer in young adults. *Am J Epidemiol* 1980;112:232–46.
- 10 Stevens MJ, Gildersleve CF, Jamerson CF, *et al*. Spermatocytic seminoma in a maldescended testis. *Br J Urol* 1993;72:657–9.
- 11 Koh KB. Beware the undescended testis and abdominal mass. *Aust N Z Surg* 1996;66:851–3.
- 12 Cheng C, Cheng PS. Cryptorchidism with a large intra-abdominal mass—a challenge. *Br J Urol* 1993;72:946–8.
- 13 Walker R, Rogers HS, Christmas TJ. Seminoma in an undescended testis presenting with frank haematuria. *Br J Urol* 1997;79:290–1.

**A vanishing pituitary mass**

**Q1: Describe the initial abnormality shown by the MRI scan (fig 1, left; see p 720).**

The initial MRI scan showed a homogenous and well circumscribed pituitary mass which measured 5 mm in diameter (arrowed). There is no suprasellar extension or compression of the optic chiasm.

**Q2: What does the follow up MRI scan show (fig 1, right; see p 720)?**

The repeat MRI scan showed complete resolution of the pituitary mass.

**Q3: What is the most likely diagnosis?**

The most likely diagnosis is a spontaneous bleed into a pituitary tumour which was probably an incidentaloma. Spontaneous pituitary infarction is supported by the clinical presentation of acute onset headache and the single episode of convulsion.

**Clinical course**

After the identification of a pituitary mass from the initial MRI scan, subsequent dynamic pituitary function test was performed and was normal. There was no evidence of deficiency in any hormonal axes. Short Synacthen test showed an adequate baseline serum cortisol of 766 nmol/l. Response to tetracosactrin 250 µg given intravenously after 30 minutes was blunted with serum cortisol raised to 839 nmol/l. The initial high baseline serum cortisol (766 nmol/l) may have been due to stress from venepuncture. Prolactin was 360 mU/l (normal range <450 mU/l). Formal visual field assessment showed no defect. An electroencephalogram was normal. The patient was treated conservatively and was advised against driving. He had no further convulsions and the follow up MRI scan showed complete resolution of the initial pituitary lesion (fig 1, right, see p 720). Repeat short Synacthen test was normal with baseline serum cortisol of 350 nmol/l, increasing to 956 nmol/l 30 minutes after 250 µg of tetracosactrin. Further dynamic pituitary function test remained normal.

**Discussion**

With the advent of imaging techniques, incidental pituitary microadenomas (adenomas <10 mm in diameter) are increasingly found in healthy individuals. The incidence of incidental pituitary tumours has been reported to be 4%–20%,<sup>1,2</sup> which is consistent with findings in necropsy studies.<sup>3</sup> Determination of endocrine function in subjects with incidental pituitary tumours is essential as both hyperpituitarism and hypopituitarism may occur.<sup>2</sup> Among pituitary incidentalomas, macroprolactinomas (adenomas >10 mm in diameter) are more likely to produce hypopituitarism<sup>4</sup> and with suprasellar extension, the optic chiasm are often compressed resulting in visual field defect (usually bitemporal hemianopia). These tumours may also invade the cavernous sinus leading to cranial nerve palsies.

Spontaneous bleeding into pituitary tumours may occur, resulting in infarction and subsequent necrosis of the pituitary gland. This often occurs in women during the peripartum period (Sheehan's syndrome).<sup>5</sup> Cases of spontaneous regression are rare but have been reported in patients after pregnancy,<sup>6</sup> with primary hypothyroidism after thyroxine treatment<sup>7</sup> and with pituitary macroprolactinoma.<sup>8</sup> Spontaneous regression of the pituitary may lead to empty sella syndrome.<sup>8</sup> It is, however, difficult to estimate the true prevalence of

**Box 1: Differential diagnosis of mass found in the sellar area**

- Aneurysms of internal carotid artery
- Craniopharyngiomas
- Meningiomas of tuberculum sellae
- Gliomas of hypothalamus and optic nerves
- Dysgerminomas
- Cysts
- Hamartomas
- Metastases
- Sarcoidosis
- Eosinophilic granulomas
- Sphenoid sinus mucocoeles

**Learning points**

- Incidental pituitary adenomas are common in asymptomatic individuals
- Endocrine evaluation of an incidental pituitary adenoma is essential as both hyperpituitarism and hypopituitarism may occur
- Spontaneous regression or haemorrhage may occur in these pituitary incidentalomas
- In the absence of visual field defect and endocrine abnormalities, these patients can be observed with follow up radiological imaging

pituitary incidentalomas as patients may be asymptomatic. Many other intracranial lesions can also present as a mass around the sellar tunic radiologically (see box 1) and should be considered. In the absence of visual field defects and hypothalamic or pituitary stalk compression, it has been suggested that a trial of medical therapy with dopamine agonist may be justified for patients with pituitary incidentalomas, although only a minority of patients (10%) will respond with reduction of tumour size.<sup>9</sup> Surgery is indicated when there are radiological signs of tumour enlargement, local invasion, optic nerve compression, or in the presence of abnormal pituitary function.

**Final diagnosis**

Spontaneous haemorrhage into an incidental pituitary adenoma.

- 1 Wolpert SM, Molitch ME, Goldman JA, *et al.* Size, shape and appearance of the normal female pituitary gland. *Am J Neuroradiol* 1984;5:263–7.
- 2 Molitch ME, Russell EJ. The pituitary "incidentaloma". *Ann Intern Med* 1990;112:925–31.
- 3 Chambers EF, Turski PA, LaMasters D, *et al.* Regions of low density in the contrast-enhanced pituitary gland: normal and pathologic processes. *Radiology* 1982;144:109–13.
- 4 Molitch ME. Incidental pituitary adenomas. *Am J Med Sci* 1993;306:262–4.
- 5 Dash RJ, Gupta V, Suri S. Sheehan's syndrome: clinical profile, pituitary hormone responses and computed sellar tomography. *Aust N Z J Med* 1993;23:26–31.
- 6 Leiba S, Schindel B, Weinstein R, *et al.* Spontaneous postpartum regression of pituitary mass with return of function. *JAMA* 1986;255:230–2.



- 7 Valenta LJ, Tamkin J, Sostrin R, *et al.* Regression of a pituitary adenoma following levothyroxine therapy of primary hypothyroidism. *Fertil Steril* 1983;40:389–92.
- 8 Robinson DB, Michaels RD. Empty sella resulting from the spontaneous resolution of a pituitary macroadenoma. *Arch Intern Med* 1992;152:1920–3.
- 9 Molitch ME. Clinical review 65. Evaluation and treatment of the patient with a pituitary incidentaloma. *J Clin Endocrinol Metab* 1995;80:3–6.

### Shortness of breath and diffuse chest pain

#### Q1: What is the diagnosis?

The diagnosis is flail chest with acute respiratory failure. As the patient has not suffered any trauma it would be considered as spontaneous.

#### Q2: What is the primary disease?

The underlying disease after considering all the parameters is multiple myeloma stage IIIB.

#### Q3: What are the causes of flail chest?

Flail chest denotes a condition in which the chest deforms markedly during quiet breathing and is produced by double fractures of three or more contiguous ribs or combined sternal and rib fractures.<sup>1</sup> Flail chest occurs in 20% of patients with blunt chest trauma and is usually sustained by falls from high places, in automobile accidents, or during cardiac resuscitation and the accompanying mortality may be as high as 30%–40%.<sup>2</sup> Flail chest may also occur with pathological fractures of the ribs with trivial trauma. However, as in the case presented here, if the diagnosis of multiple myeloma is delayed, spontaneous fractures of multiple ribs can cause flail chest and the patient can present with acute respiratory failure.

#### Q4: What are the treatment options?

The treatment options are treatment of multiple myeloma with chemotherapy and stabilisation of the chest wall. Many methods have been improvised to stabilise the chest wall. At the present time endotracheal intubation with the use of a volume respirator has largely supplanted all other methods.<sup>3</sup> This approach maintains ventilation at physiological levels and stabilises the thoracic wall in an expanded position that tends to minimise late chest wall collapse and later disability. Intermittent mandatory ventilation at a rate of 10–16/min associated with moderate levels of positive end expiratory pressure or continuous positive airway pressure is usually used. Occasionally controlled ventilation with tidal volumes from 1000–2000 ml with added dead space may be used. Serial blood gas determinations dictate both the need for respiratory assistance and the time to terminate or wean a patient from the ventilator. Usually 5–10 days is required before adequate stability of the chest wall is restored. Longer periods may be required in the elderly.

### Discussion

Multiple myeloma is a relatively indolent neoplasm in which the terminally differentiated B lymphocytes, known as plasma cells, accumulate and become the distinctive feature of

### Learning points

- Multiple myeloma should be suspected in patients with longstanding bone pain
- The clinical spectrum of multiple myeloma varies widely, ranging from the incidental discovery of a monoclonal peak on plasma protein electrophoresis to widespread skeletal involvement and incapacitating bone pain
- Diagnosis rests to a large extent on having a high index of suspicion
- Flail chest is a rare complication of myeloma

the tumour. The clinical spectrum varies widely ranging from the incidental discovery of a monoclonal peak on plasma protein electrophoresis to widespread skeletal involvement and incapacitating bone pain.<sup>4,5</sup> Bone pain is the most common symptom of multiple myeloma.<sup>1,6</sup> The bone lesions of myeloma are caused by proliferation of tumour cells and activation of osteoclasts which respond to osteoclast activation factors produced by myeloma cells. Punched out lytic lesions without associated osteoblastic changes are characteristic of myeloma. The vertebrae, skull, thoracic cage, pelvis, and proximal humeri and femurs are the usual sites of involvement.<sup>6</sup> Pathological fractures especially of the vertebrae are not uncommon and may lead to spinal cord compression. It is therefore not surprising that this neoplasm may be misdiagnosed and in many cases long periods elapse before the error is corrected. It follows that the diagnosis rests to a large extent on having a high index of suspicion and then by doing relevant investigations without delay.<sup>7</sup>

### Final diagnosis

Multiple myeloma with spontaneous flail chest and acute respiratory failure.

- 1 Todd TRJ, Shamzi F. Pathophysiology of chest wall trauma. In: Roussos C, Mackm PT, eds. *The thorax. Part B.* New York: Marcel Dekker, 1985: 979–97.
- 2 Richardson JD, Admas L, Flint LM. Selective management of flail chest and pulmonary contusion. *Ann Surg* 1980; 481–7.
- 3 Shackford SR, Virgilio RW, Peters RM. Selective use of ventilator therapy in flail chest injury. *J Thorac Cardiovasc Surg* 1981;81:194.
- 4 Alexanian R. Plasma cell neoplasms. *Curr Probl Cancer* 1978;3:1–60.
- 5 Jacobs P. Myeloma. *Dis A Month* 1990;34:317–71.
- 6 Kyle RA. Multiple myeloma: review of 869 cases. *Mayo Clin Proc* 1975;20:29–40.
- 7 Flanagan NG, Ridway JC, Jain A, *et al.* Problems of myeloma in a community. *Postgrad Med J* 1988;64:747–51.

### An elderly man with muscle cramps

#### Q1: What is the abnormality on the 12 lead electrocardiogram?

The electrocardiogram (see p 721) shows a prolonged QT interval and a prolonged QTc.

$$QT_c = \frac{QT}{\sqrt{R-R \text{ interval}}} = 0.38-0.42s$$

**Box 1: Causes of long QT**

- Hypocalcaemia
- Hypomagnesaemia
- Long QT syndromes: Jervell and Lange-Nielsen syndrome (autosomal recessive, congenital deafness, mutism, and sudden death); Romano-Ward syndrome (autosomal dominant transmission with genetic heterogeneity is commoner in females and sudden death); congenital long QT syndrome
- Anorexia nervosa
- Drugs: antiarrhythmics (quinidine, procainamide, amiodarone and sotalol); psychiatric drugs (pimozide, chlorpromazine, tricyclic antidepressants, lithium); others (cisapride, tacrolimus, terfenadine, quinine, and chloroquine)

**Box 2: Causes of hypocalcaemia**

- Primary hypoparathyroidism: idiopathic, postsurgical
- Pseudohypoparathyroidism
- Hypocalcaemia associated with malignant disease
- Hypomagnesaemia
- Toxic shock syndrome
- Acute pancreatitis
- Renal failure
- Vitamin D deficiency: dietary, malabsorption, anticonvulsant therapy, chronic liver disease, chronic renal disease, vitamin D dependent rickets

**Q2: What are the possible causes of the abnormality of the electrocardiogram?**

The various causes of a prolonged QTc are listed in box 1.

**Q3: What is the likely diagnosis?**

The diagnosis is hypocalcaemia. The combination of the electrocardiogram with prolonged QT and QTc associated with muscle cramps, weakness, and cataracts is supportive of a diagnosis of hypocalcaemia. Further investigations revealed a serum corrected calcium of 1.13 mmol/l (normal range 2.20–2.60 mmol/l) and a serum phosphate of 1.50 mmol/l (0.70–1.40 mmol/l) and normal renal function, with undetectable serum parathyroid hormone (PTH), suggesting a diagnosis of hypoparathyroidism.

**Discussion**

Hypocalcaemia can be caused by a number of conditions (box 2). The symptoms of hypocalcaemia include neuromuscular irritability, paraesthesia, muscle cramps, and seizures. The symptoms do not correlate with the absolute degree of hypocalcaemia.<sup>1</sup> Decreased total serum calcium, with a normal ionised fraction can exist with hypoproteinaemia or acidosis. These possibilities should be excluded by measuring serum albumin concentration and calculating the corrected serum calcium concentration or by directly measuring serum ionised calcium concentration. Alkalosis decreases ionised serum calcium concentration and may precipitate tetany.

Electrocardiographic manifestations of hypocalcaemia include prolongation of the QT interval particularly the QTc and T wave changes such as peaking and inversion. The QT interval returns to normal rapidly after correction of hypocalcaemia, but the T wave abnormality may be slower to regress.<sup>1</sup> A prolonged QT interval should theoretically predispose to ventricular tachycardia, but this arrhythmia is rare in association with hypocalcaemia.<sup>1</sup>

Hypocalcaemia with hyperphosphataemia and normal renal function strongly suggest a diagnosis of hypoparathyroidism. This commonly may occur after previous neck surgery suggesting postsurgical hypoparathyroidism. Idiopathic hypoparathyroidism may be associated with Addison's disease, primary hypothyroidism, type 1 diabetes, and primary hypogonadism or associated with Addison's disease, chronic mucocutaneous candidiasis as part of autoimmune polyglandular syndrome type II (Schmidt's syndrome).<sup>2</sup>

Pseudohyperparathyroidism is associated with similar biochemical features but with raised serum PTH because of target organ resistance. There are various subtypes and is characterised by short stature, round face, shortening of the metacarpals, and reduced intelligence.<sup>3</sup> Hypocalcaemia is frequently associated with hypomagnesaemia. Hypomagnesaemia may be caused by chronic alcoholism, malabsorption, prolonged parental nutrition or the use of cisplatin, aminoglycosides and diuretics.<sup>4</sup> Hypomagnesaemia may cause hypocalcaemia, both by impaired secretion of PTH from the parathyroid glands and by end organ resistance to the effects of PTH.<sup>5</sup>

Thus in patients with tetany or convulsions and low serum calcium with low serum PTH unresponsive to calcium supplements hypomagnesaemia should be considered.

**Final diagnosis**

Hypocalcaemia.

1 Aurbach GD, Marx SJ, Spiegel AM. Parathyroid hormone, calcitonin and the calciferols. In: Wilson JD, Foster DW, eds. *Williams textbook of endocrinology*. 8th Ed. Philadelphia: WB Saunders, 1992: 1397–476.

2 Ahonen P. Autoimmune polyendocrinopathy-candidosis-ectodermal dystrophy (APECED): autosomal recessive inheritance. *Clin Genet* 1985;27:535–42.

3 Albright F, Burnett C, Smith PH, et al. Pseudohypoparathyroidism—an example of “seabright-bantam” syndrome. *Endocrinology* 1942;30:922–32.

4 al-Ghamdi SM, Cameron EC, Sutton RA. Magnesium deficiency: pathophysiological and clinical overview. *Am J Kidney Dis* 1994;24:737–52.

5 Rude RK, Oldham SB, Singer FR. Functional hypoparathyroidism and parathyroid end-organ resistance in human magnesium deficiency. *Clin Endocrinol (Oxf)* 1976;5:209–24.

### Left kidney mass in a 45 year old woman

#### Q1: What is the most likely diagnosis?

Contrast enhanced computed tomography (see p 722) showed a retroperitoneal haematoma (asterisks) anterior to the left kidney, displacing ventrally the anterior layer of renal fascia (arrows). There was a space occupying lesion within the kidney (black arrows), consisting of fat and convoluted vessels (open arrows). Note the thickened posterior renal fascia (short arrows). These findings are consistent with the occurrence of a recent haemorrhage from the angiomyolipoma.

#### Q2: What is the treatment?

The present strategy for the management of angiomyolipoma is to preserve normal renal parenchyma by performing renal sparing surgery or renal arterial embolisation, in order to prevent future haemorrhaging and to preserve renal function.<sup>1</sup> An asymptomatic angiomyolipoma 4 cm or larger should be monitored at every six months with computed tomography or ultrasonography.

In this case the patient underwent left partial nephrectomy. Two years after discharge, she remains well and is followed up every six months.

#### Discussion

Angiomyolipoma is an uncommon mesenchymal hamartoma of the kidney containing variable amounts of fat, smooth muscle, and blood vessels.<sup>2</sup> The prevalence of angiomyolipoma in the general population is approximately 0.3%. It can be associated with tuberous sclerosis complex (20%), while sporadic cases of

#### Angiomyolipoma of the kidney

- Histology: hamartomas containing smooth muscle, fat, and blood vessels
- Radiological features: the presence of fat, which appears hypodense on computed tomography, is virtually diagnostic of angiomyolipoma
- Associations: tuberous sclerosis complex (20%)
- Complications: spontaneous bleed
- Treatment: large, symptomatic lesions may be resected or embolised

angiomyolipoma (80%) are typically found in middle aged women. Its main clinical manifestation is flank pain caused by spontaneous perinephric haemorrhage, which is positively correlated to the size of the neoplasms: among angiomyolipomas 4 cm or larger, 50%–60% bleed spontaneously. Angiomyolipoma is the only benign tumour of the kidney that can be diagnosed almost exclusively by means of imaging. The diagnosis relies on the detection of intratumoral fat on computed tomography, which is characteristic.<sup>3</sup>

#### Final diagnosis

Haemorrhage from an angiomyolipoma.

- 1 Moorhead JD, Fritzsche P, Hadley HL. Management of hemorrhage secondary to renal angiomyolipoma with selective arterial embolization. *J Urol* 1977;117:122–3.
- 2 Steiner MS, Goldman SM, Fishman EK, *et al.* The natural history of angiomyolipoma. *J Urol* 1993;150:1782–6.
- 3 Hélenon O, Merran S, Paraf F, *et al.* Unusual fat-containing tumors of the kidney: a diagnostic dilemma. *Radiographics* 1997;17:129–44.