

## SELF ASSESSMENT QUESTIONS

## A pulmonary mass and hyperviscosity

Answers on p 587.

J A Corless, D J Allsup, T J Deeble, J C Delaney

A 69 year old woman was referred to hospital because of a persistent dry cough and dyspnoea. She has never smoked and was taking captopril for hypertension and thyroxine for hypothyroidism. At age 20 she developed pulmonary tuberculosis which was treated with a left artificial pneumothorax. A few years later during the course of investigation into infertility she was found to have tuberculous endometriosis and salpingitis. This was treated with streptomycin injections and isoniazid.

A large mass measuring 10 cm × 9 cm was seen on chest radiography (see figs 1 and 2). Computed tomography of the thorax demonstrated a solid, partially calcified 10 cm mass situated posteriorly in the left upper lobe. In addition there was loss of volume and concentric pleural thickening in the left hemithorax, probably as a result of the previous artificial pneumothorax. No metastases were evident. At bronchoscopy irregular mucosa was noted in the left upper lobe bronchus. A biopsy

specimen of this showed abnormal lymphoid tissue. Staining of sputum for acid-alcohol fast bacilli and subsequent mycobacterial cultures were negative.

In the meantime the patient had developed marked hypertension, spontaneous bruising, and epistaxis. Fundal haemorrhages were present. Blood tests revealed a plasma viscosity of 5.3 mpa/s (normal range 1.5-1.72), haemoglobin 114 g/l, white cell count  $3.9 \times 10^9/l$ , platelets  $230 \times 10^9/l$ , globulin of 81 g/l, and an IgM monoclonal band of 42 g/l. Renal function was normal.

### Questions

- (1) What diagnosis is suggested by the raised plasma viscosity and monoclonal IgM band and how would you confirm this?
- (2) What is the likely explanation for the lung mass?
- (3) What treatment would you consider?

Arrowe Park Hospital,  
Arrowe Park Road,  
Wirral, Merseyside  
L49 9AB, UK:  
Department of  
Respiratory Medicine  
J A Corless  
J C Delaney

Department of  
Haematology  
D J Allsup  
T J Deeble

Correspondence to:  
Dr Corless, c/o Dr Delaney's  
secretary (email:  
johncorless@hotmail.com)

Submitted 5 August 1999  
Accepted 27 October 1999

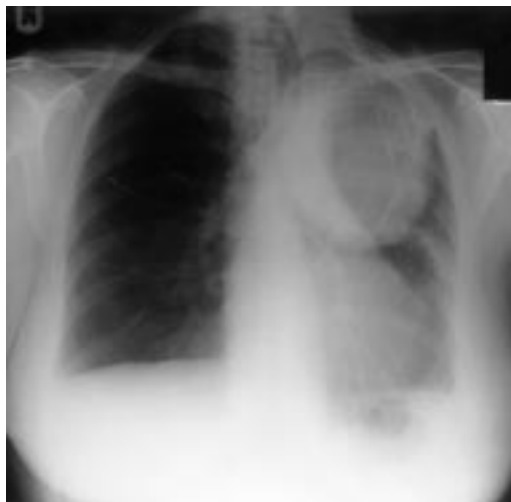

Figure 1 Chest radiograph, posteroanterior view.

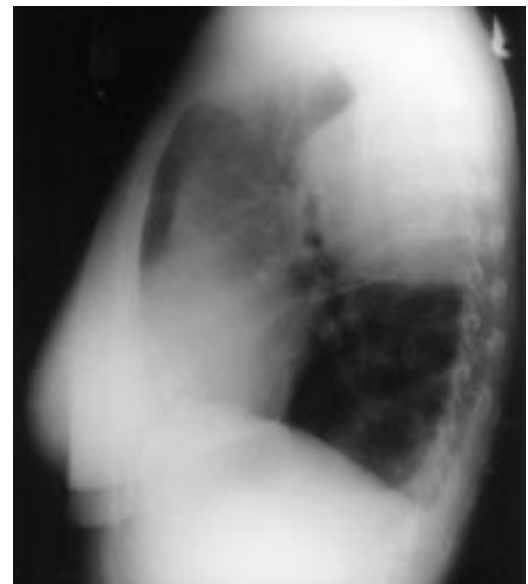


Figure 2 Chest radiograph, lateral view.

## Abdominal pain in a 22 year old woman

Answers on p 587.

Tarik Asselah, Olivier Ernst, Valérie Canva, Jean-Claude Paris

A 22 year old woman was referred because of hepatomegaly and episodes of mild abdominal pain. She had no history of alcohol abuse and she had taken no medication (no oral contraceptive pills). She had never been transfused and had no known exposure to hepatotoxic chemicals. There was no family history of liver disease. There was hepatosplenomegaly on presentation. There was no ascites and no stigma of chronic liver disease.

Laboratory data showed a white blood cell count of  $6.0 \times 10^9/l$  (normal range 4.0–10.0), red blood cell count  $4.0 \times 10^{12}/l$  (3.8–5.8), haemoglobin concentration 90 g/l (120–160), a packed cell volume 0.38 (0.38–0.42), platelet count  $220 \times 10^9/l$  (150–400), and red cell volume 28 ml/kg (<32). Spontaneous erythroid colonies developed in serum which contained only trace amounts of erythropoietin. The prothrombin level was 0.60 (0.70–1.0), serum bilirubin 17.1  $\mu\text{mol}/l$  (1.7–20.5), alkaline phosphatase activity 92 UI/l (30–100), aspartate transaminase activity was 18 UI/l (<40), and albumin 32 g/l (35–52). Antismooth muscle antibody, antinuclear antibody, and antimitochondrial antibody were not detectable. The ceruloplasmin level was normal.

Antibody to hepatitis C virus (by enzyme linked immunoabsorbent assay), hepatitis B surface antigen, and antibody to hepatitis B surface antigen were all negative. The ferritin was 10  $\mu\text{g}/l$  (36–255), total iron binding capacity 34.4  $\mu\text{mol}/l$  (44.8–80.6), serum iron 8.4  $\mu\text{mol}/l$  (16.1–28.7), and transferrin saturation 24% (30–40). The HIV antibody test was negative. Concentrations of antithrombin III, protein C, and protein S were normal. Bone marrow examination with karyotype showed no abnormality.

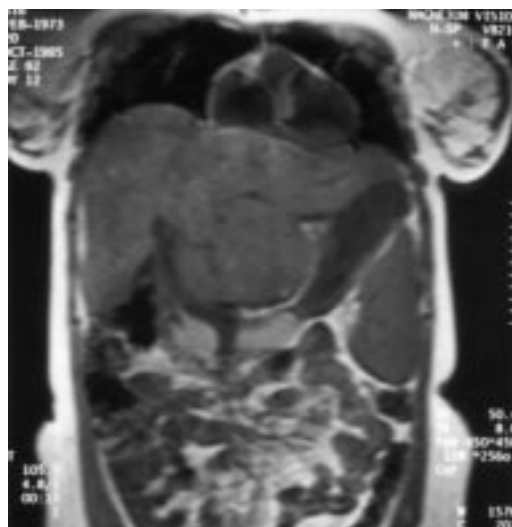


Figure 1 MRI coronal T1 weighted image showing a hypertrophic caudate lobe with compression of the inferior vena cava.

Upper endoscopy showed grade II oesophageal varices. The major hepatic veins were not seen at duplex Doppler ultrasonography in colour mode, however an enlarged subhepatic accessory vein was draining a hypertrophic caudate lobe. The same patterns were found on magnetic resonance imaging (MRI) (fig 1) and magnetic resonance angiography. The patient refused a liver biopsy. She was treated with anticoagulants. After 16 months of follow up, the patient was asymptomatic.

### Questions

- (1) What is the syndrome presented by this patient?
- (2) What is the underlying disease?

Hôpital Huriez,  
CHRU, 59037 Lille,  
France: Service  
d'Hépatologie  
T Asselah  
V Canva  
J-C Paris

Service de Radiologie  
Est  
O Ernst

Correspondence to:  
Tarik Asselah, 9 passage  
Cottin, 75018 Paris, France  
(email: tarik.asselah@  
bjn.ap.hop-paris.fr)

Submitted 20 January 1999  
Accepted 8 October 1999

## A rare cause of unilateral hearing loss

Answers on p 588.

O A Osinubi, I Lauder, R S A Thomas

A 54 year old white male first presented in 1978 to the medical department of the hospital with a six month history of shortness of breath and productive cough. His symptoms became progressively worse and necessitated two hospital admissions. He had vitiligo for 14 years and hereditary ichthyosis. He was a non-smoker and he worked in a chemical factory with lacquers and thinners.

Examination revealed both inspiratory and expiratory wheeze and a few crepitations at the right lung base. Abdominal examination showed a palpable spleen of about 8 cm and a palpable liver of about 6 cm below the costal margin. Investigation confirmed angiotensin converting enzyme of 72 IU (normal range 10–65). The chest radiograph is shown in fig 1 and the respiratory function showed a mixed obstructive and restrictive picture. Bronchoscopy revealed hyperaemic mucosa which was irregular with white “cobblestoning” and there was narrowing of both bronchi compatible with endobronchial sarcoidosis. The Kveim test was positive and lymph node biopsy confirmed sarcoidosis. He had maintenance doses of steroids varying between 5 mg and 25 mg daily for 18 years until remission of symptoms about two years before.

He was referred to the ear, nose, and throat department in November 1997 with deafness in the left ear which followed an ear infection. Examination of the ears showed a dull tympanic membrane on the left while the right side was normal. Pure tone audiometry showed mild bilateral high tone sensorineural hearing loss and an additional conductive loss in the

left ear. The tympanogram showed type B tracing in the left ear. He had a left myringotomy and grommet insertion. Examination of the postnasal space was normal on visual inspection and palpation. A random biopsy was performed and tissue from the left side of the postnasal space revealed hyperplastic lymphoid tissue in which there were some active germinal centres. There were several discrete epithelioid granuloma containing Schaumann bodies including some Langhans type multinucleated giant cells. There was no caseous necrosis or special giant cells. Special stains failed to reveal any fungi or acid fast bacilli. There was no evi-

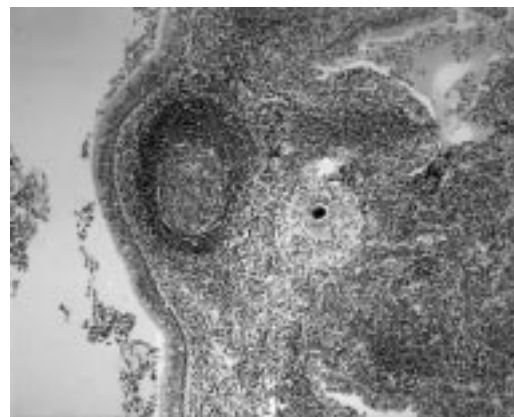


Figure 2 This low power view of the postnasal lymphoid tissue shows the epithelial surface on the far left. Deep to this is a reactive lymphoid follicle and to the right and slightly below this follicle there is non-caseating epithelioid granuloma containing a darkly staining Schaumann body (haematoxylin and eosin  $\times 40$ ).

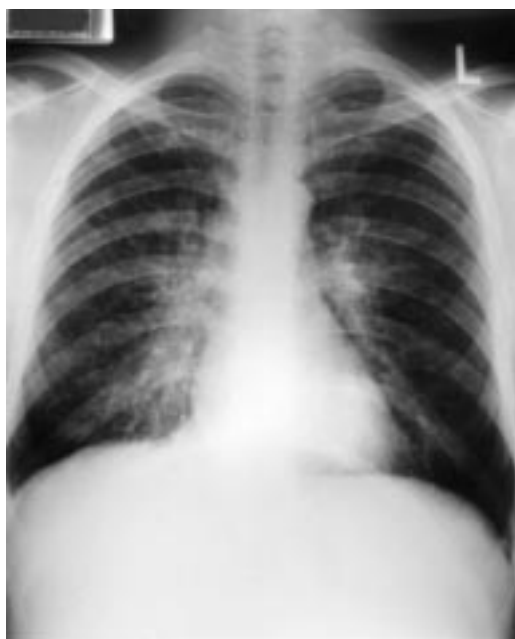

Figure 1 Chest radiograph showing bilateral hilar and widespread nodular shadows throughout both lung fields with a normal heart size.

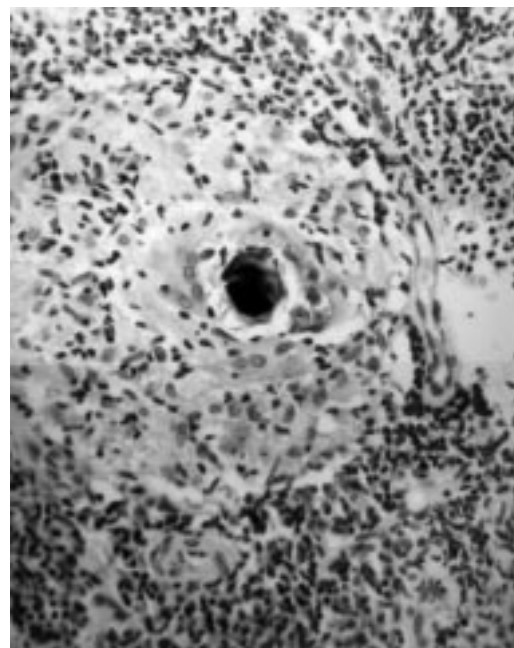


Figure 3 This medium power view shows in more detail the non-caseating granuloma and the Schaumann body. Such granulomas are typical of sarcoidosis and several such lesions were present within the biopsy (haematoxylin and eosin  $\times 160$ ).

Department of Ear  
Nose and Throat,  
Leicester Royal  
Infirmary, Leicester  
LE1 5WW, UK  
O A Osinubi  
R S A Thomas

Department of  
Pathology, University  
of Leicester, Leicester  
I Lauder

Correspondence to:  
Mr Thomas

Submitted 2 March 1999  
Accepted 22 September  
1999

dence of malignancy and the histological finding was in keeping with sarcoidosis (figs 2 and 3).

### Questions

(1) What is the differential diagnosis?

(2) What does the chest radiograph show?

(3) What is the cause of deafness in the left ear?

(4) What are the otolaryngological manifestations of sarcoidosis?

## A difficult psychiatric patient

Answers on p 590.

Max J Henderson

A 74 year old man was admitted to a psychiatric ward at the request of his community psychiatric nurse. He arrived unaccompanied by either his nurse or his family. The history in the community psychiatric nurse's letter was that the patient's family had been concerned for the past week as he had taken to his bed. They had needed to wash and feed him. He slept a lot. They had alerted the nurse who, having seen the patient at home, arranged for an urgent admission.

From the old medical notes it was clear the patient had a long psychiatric history dating back 40 years. His initial diagnosis was obsessive-compulsive disorder but the majority of his admissions had been for agitated depression. He had taken at least one overdose in the past. There was a documented history of alcohol abuse, but it was not clear if this was still an issue. More recently he had developed idiopathic Parkinson's disease. Cognitive impairment had been noted on his last admission: computed tomography had showed cerebral atrophy and some small infarcts and he had been started on aspirin. His medication which accompanied him on admission also included paroxetine, lithium, and co-beneldopa (Madopar).

Very little history was available from the patient, who needed to be roused from sleep.

He said he felt "terrible" but could not elaborate. He denied any pain. He admitted being sleepy. No clear psychotic features were noted but it was questioned whether or not the patient understood.

Examination of the patient's cardiovascular and respiratory systems was unremarkable as was that of the abdomen. Neurological examination revealed normal cranial nerves. Parkinsonian features were clearly demonstrated with rest tremor and cogwheel rigidity worse on the left. The patient could walk but needed assistance and conclusions about his gait were not drawn. Reflexes were normal and symmetrical—plantars were both downgoing.

Initial results showed a normal haemoglobin, a slightly raised white cell count ( $12.3 \times 10^9/l$ ), normal urea, creatinine, and electrolytes, normal glucose on BM finger prick testing and normal urine dipstick.

### Questions

(1) What is the diagnosis in this patient and what would you also consider?

(2) What particular risk factors for this condition were present in this patient?

(3) How is this condition normally managed?

Department of Old Age Psychiatry,  
Maudsley Hospital,  
Denmark Hill, London  
SE5 8AZ, UK

Correspondence to:  
Dr Henderson

Submitted 13 July 1999  
Accepted 10 September  
1999

## A rare case of radiculopathy in an elderly man

Answers on p 591.

W K Edrees, B Lee

An 82 year old man was admitted to a district general hospital with a two week history of pyrexia, low back pain referred down the left leg, and progressive weakness of his left leg. On examination he was pyrexia, 38.5°C, with signs of lower motor neurone lesion extending from L2 to S1 with no other findings. His haemoglobin concentration was 78 g/l, white cell count  $7.7 \times 10^9/l$ , and erythrocyte sedimentation rate 115 mm/hour.

Computed tomography for the LS spine showed no cord compression and identified a lesion at the left psoas muscle. Subsequently, computed tomography of the abdomen was performed (see fig 1). This was followed by aspiration and a core biopsy under computed

tomographic guidance. Bacteriology was negative and cytology non-conclusive. The patient was treated empirically with antibiotics and his symptoms gradually settled down.

Seven weeks later, the patient experienced sudden severe abdominal pain and a large mass was apparent in the left side of the abdomen. Computed tomography with enhancement was performed (see fig 2).

### Questions

- (1) Describe the findings in fig 1?
- (2) Describe the findings in fig 2?
- (3) How the patient was managed and what was the diagnosis?

Level 5, Belfast City  
Hospital, Lisburn  
Road, Belfast  
BT9 7AB, UK  
W K Edrees  
B Lee

Correspondence to:  
Mr Edrees  
(email:  
wkedrees@hotmail.com)

Submitted 22 September  
1999  
Accepted 8 October 1999

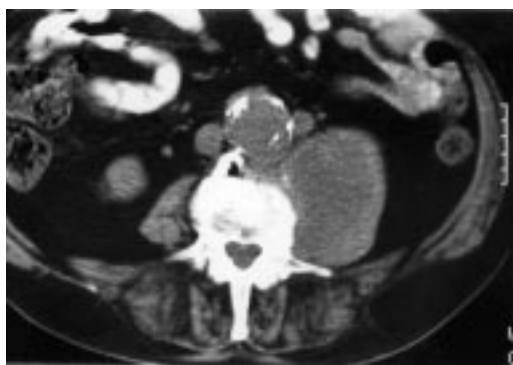


Figure 1 Computed tomogram of the abdomen.

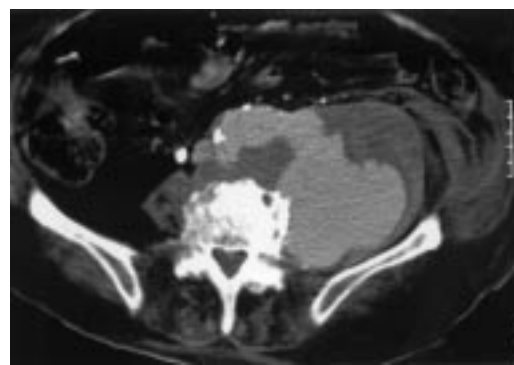


Figure 2 Computed tomogram with enhancement.

## How can fruits and sugar induce headache and hypoglycaemia?

Answers on p 592.

Victor Y Kopyev, Eugene Lozner

A 47 year old white woman, while she was being evaluated for atypical chest pain, mentioned that she had had a life long history of a "sugar intolerance". On further questioning she described her symptoms as a severe headache, sweating, nausea, vomiting, abdominal pain, and fainting occurring shortly after she ate something sweet. She had had these symptoms since infancy from the time she was weaned. She developed an aversion to sweets and followed a diet, which consisted mainly of meat and dairy products. She had a brother who had the same problem. Ten to 20 years ago she was given a "glucose tolerance test" by her family physician who gave her a glass of sweetened orange juice. She developed a severe attack of her usual symptoms, shaking, and

perspiration and she almost lost consciousness. Hypoglycaemia was documented by her physician. Fortunately, she recovered spontaneously. At that time her doctor recommended that she continue with her diet. She remained well and was able to stay almost symptom-free by carefully selecting what she ate. Her review of systems and physical examination were also remarkable for excellent dental health.

### Questions

- (1) What diagnosis would account for her "sugar intolerance" and what diagnostic test would you recommend?
- (2) How would you treat hypoglycaemia in such patients?
- (3) What needs to be done for the patient?

State University of  
New York Health  
Science Centre and  
Crouse Irving  
Memorial Hospital,  
Syracuse, New York,  
USA  
V Y Kopyev  
E Lozner

Correspondence to:  
Dr Victor Kopyev, The Good  
Health Centre, 1394 S  
Cleveland-Massillon Road,  
Copley, Ohio 44321, USA

Submitted 9 July 1999  
Accepted 22 September  
1999

## SELF ASSESSMENT ANSWERS

**A pulmonary mass and hyperviscosity****Q1: What diagnosis is suggested by the raised plasma viscosity and monoclonal IgM band and how would you confirm this?**

The diagnosis is Waldenstrom's macroglobulinaemia. A raised plasma viscosity and IgM monoclonal band of greater than 3 g/l are strongly suggestive of a lymphoplasmacytoid malignant lymphoma. This condition is commonly referred to as Waldenstrom's macroglobulinaemia and was first described in 1944.<sup>1</sup> Other lymphoproliferations which may rarely secrete an IgM paraprotein include low grade non-Hodgkin's lymphoma and multiple myeloma plasmacytoma. The disease usually develops in the seventh decade and in the early stages it typically presents with lethargy, weight loss, recurrent infections, and features of hyperviscosity (epistaxis, visual disturbance, peripheral neuropathy, headache, altered consciousness, or congestive cardiac failure). Unlike myeloma, Waldenstrom's macroglobulinaemia does not result in lytic bone lesions. The diagnosis is confirmed by bone marrow examination, which (as in our patient) shows an excess of lymphoplasmacytoid cells.

**Q2: What is the likely explanation for the lung mass?**

A pulmonary deposit of lymphoplasmacytoid malignant lymphoma is the likely explanation for the lung mass. Lung involvement in Waldenstrom's macroglobulinaemia has been documented but is uncommon, occurring in fewer than 5% of cases. Bollinelli *et al* described five forms of pulmonary involvement—namely, infectious manifestations, parenchymal involvement, discrete pulmonary deposits (as in this patient) which may be single or multiple, bronchial infiltration, and pleural involvement.<sup>2</sup> In patients who develop pulmonary lesions, two thirds will have radiographic abnormalities at presentation.<sup>3</sup>

A trucut biopsy of the lung mass in this patient revealed a heavy infiltrate of plasma cells consistent with a localised deposit of lymphoplasmacytoid malignant lymphoma.

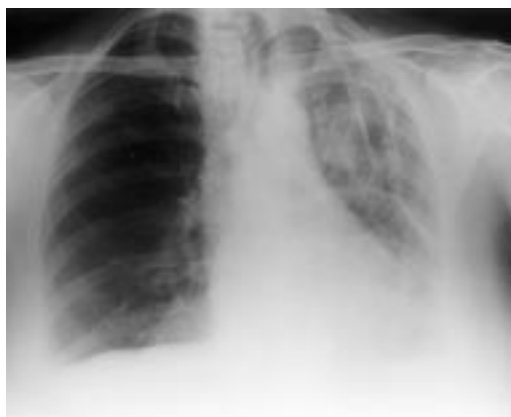

Figure 1 Chest radiograph after treatment.

**Learning points**

- Pulmonary involvement is a rare feature of Waldenstrom's macroglobulinaemia
- Pulmonary features may be the first sign of the disease
- Treatment is palliative and may include plasmapheresis and chemotherapy

**Q3: What treatment would you consider?**

As Waldenstrom's macroglobulinaemia is incurable, treatment is only indicated in symptomatic cases. Plasmapheresis is effective for short term control of hyperviscosity and its associated symptoms. The oral alkylating agent chlorambucil is effective in controlling the disease and there are reports of its successful use in cases with pulmonary involvement,<sup>4,5</sup> although treatment for 12 months may be required before an adequate response is obtained. Treatment with combinations of chemotherapeutic agents has also been found to be effective.

In view of her hyperviscosity, our patient was admitted to hospital for plasmapheresis, ultimately requiring eight sessions. As treatment for her underlying macroglobulinaemia she received chemotherapy with six cycles of the nucleoside analogue fludarabine (25 mg/m<sup>2</sup> daily for five days, repeated every four weeks). There was a marked improvement in the appearances of the chest radiograph (see fig 1 below) and the patient is now symptom free. Plasma viscosity fell to 1.85 mpa/s with an IgM monoclonal band of 5 g/l. Maintenance therapy has been given with chlorambucil. We know of no other reported cases of Waldenstrom's macroglobulinaemia with pulmonary involvement that have successfully treated with fludarabine.

**Final diagnosis**

Waldenstrom's macroglobulinaemia presenting with a pulmonary deposit of lymphoplasmacytoid malignant lymphoma.

- 1 Waldenstrom J. Incipient myelomatosis or "essential" hyperglobulinaemia with fibrogenopenia: a new syndrome? *Acta Med Scand* 1944;117:216–47.
- 2 Bollinelli R, Carles P, de Boissezon JF, *et al*. Formes respiratoires de la macroglobulinaemia de Waldenstrom. *Journal Français de Médecine et Chirurgie Thoraciques* 1970;24:437–80.
- 3 Raush PG, Herion JC. Pulmonary manifestations of Waldenstrom's macroglobulinaemia. *Am J Hematol* 1980;9:201.
- 4 Hull R, Barton E. Pulmonary paraprotein production in Waldenstrom's macroglobulinaemia. *Postgrad Med J* 1982;58:57–8.
- 5 Rabiner S, Aprill S, Radner D. Waldenstrom's macroglobulinaemia. Report of a case with pulmonary involvement and improvement in pulmonary symptoms only following chlorambucil therapy. *Am J Med* 1972;53:685–9.

**Abdominal pain in a 22 year old woman****Q1: What is the syndrome presented by this patient?**

Budd-Chiari syndrome (BCS).

**Q2: What is the underlying disease?**

Latent myeloproliferative disorder (polycythaemia vera).

**Discussion**

Because of clinical evidence of portal hypertension (splenomegaly, oesophageal varices), we considered the possibility of BCS. Ludwig *et al* suggested the following definition for BCS: "hepatic venous outflow obstruction and its manifestations, regardless of cause, the obstruction being either within the liver or the inferior vena cava between the liver and the right atrium".<sup>1</sup>

A colour Doppler sonogram was obtained and confirmed the diagnosis: the major hepatic veins were not seen and an enlarged subhepatic accessory vein was draining a hypertrophic caudate lobe. Colour Doppler sonography is increasingly being used for the diagnosis of BCS, and it provides a safe and accurate alternative to liver biopsy.<sup>2</sup> Magnetic resonance angiography gives similar information and may be of value when diagnosis is not clear after sonographic examination.<sup>3</sup>

There are a large number of known causes of BCS: thrombogenic conditions (coagulopathy, myeloproliferative disease, etc), malignant tumours, or membranous obstruction of the inferior vena cava.<sup>4</sup> Sonography and magnetic resonance angiography excluded a tumour or a membranous obstruction of the inferior vena cava. For this patient, standard laboratory data were normal, except a sideropenia which may result from an occult oesophageal varices bleeding. Although oesophageal varices characteristically produce acute severe haemorrhage, it can unusually cause an occult bleeding and lead to iron deficiency anaemia.<sup>5</sup>

Using conventional criteria, the diagnosis should have been an idiopathic BCS. When cultures of bone marrow and peripheral blood mononuclear cells were grown using the method described by McLeod *et al*, we observed that spontaneous erythroid colonies developed without addition of erythropoietin.<sup>6</sup> This result is specific for primary myeloproliferative syndrome,<sup>7</sup> which is believed to be the second cause of BCS after malignant tumours. Polycythaemia vera is rare before the age of 40, accounting for fewer than 5% of the cases.<sup>8</sup> This patient presents similarities with those reported by Valla *et al*; the absence of peripheral blood anomalies typical of myeloproliferative disorder could be explained by the portal hypertension.<sup>7</sup> So, the mechanism of vein thrombosis could be related to platelet dysfunction without increased blood viscosity.<sup>9</sup> The exact nature of the dysfunction is at the present time unknown.

**Final diagnosis**

Budd-Chiari syndrome with latent myeloproliferative disorder (polycythaemia vera).

1 Ludwig J, Hashimoto E, Mc Gill D, *et al*. Classification of hepatic venous outflow obstruction: ambiguous terminology of Budd-Chiari syndrome. *Mayo Clin Proc* 1990;65:51–5.

2 Arora A, Seth S, Sharma MP, *et al*. Case report: unusual CT appearances in a case of Budd-Chiari syndrome. *Clin Radiol* 1991;43:431–2.

**Learning points**

- Budd-Chiari syndrome (BCS) can be diagnosed by ultrasound Doppler colour sonography and magnetic resonance imaging
- Myeloproliferative disorder is a common cause of BCS
- Search for a latent myeloproliferative disorder by means of spontaneous erythroid colony formation in bone marrow culture should be done when BCS occurs without other recognisable causes, even when there are no peripheral blood changes

3 Kane R, Eustace S. Diagnosis of Budd-Chiari syndrome: comparison between sonography and MR angiography. *Radiology* 1995;195:117–21.

4 Okuda H, Yamasata H, Obata H, *et al*. Epidemiological and clinical features of Budd-Chiari syndrome in Japan. *J Hepatol* 1995;22:1–9.

5 Richter JM. Occult gastrointestinal bleeding. *Gastroenterol Clin North Am* 1994;23:53–66.

6 McLeod DL, Shreeve MM, Axelrad AA. Improved plasma culture system for production of erythrocytic colonies in vitro: quantitative assay method for CFU-E. *Blood* 1974;44:517–34.

7 Valla D, Casadevall N, Lacombe C, *et al*. Primary myeloproliferative disorder and hepatic vein thrombosis. *Ann Intern Med* 1985;103:329–34.

8 Najean Y, Mugnier P, Diesch C, *et al*. Polycythemia vera in young people: an analysis of 58 cases diagnosed before 40 years. *Br J Haematol* 1987;67:285–91.

9 Schafer AL. The hypercoagulable states. *Ann Intern Med* 1985;102:814–28.

**A rare cause of unilateral hearing loss****Q1: What is the differential diagnosis?**

The cause of sarcoidosis is still obscure and it is a diagnosis of exclusion. The differential diagnosis of sarcoidosis of nasopharynx is shown below (box 1).

**Q2: What does the chest radiograph show?**

The chest radiograph (see p 584) shows bilateral hilar shadows and there are also widespread nodular shadows throughout both lung fields with a normal heart size.

**Q3: What is the cause of deafness in the left ear?**

The cause of the deafness is left otitis media with effusion (glue ear). All adult patients with unilateral otitis media must have biopsy of the nasopharynx to exclude pathology especially malignant tumour. Sarcoidosis may involve the nasopharynx causing inflammatory reaction which may result in eustachian tube dysfunction and leads to otitis media with effusion. There may also be direct involvement of the middle ear mucosa by sarcoidosis. Tympanometry is the measurement of compliance and resistance or impedance of the middle ear mechanism. The result obtained can be classified broadly into three groups. Type A shows symmetrical graph with maximum compliance at 0 mm H<sub>2</sub>O as in normal middle ear mechanism, type B shows a flat trace indicating a marked decrease in compliance usually due to damping of middle ear mechanism and tym-

**Box 1: Differential diagnosis of sarcoidosis of nasopharynx**

This can be classified into specific, non-specific, and others

*Specific*

- Tuberculosis
- Leprosy
- Lupus vulgaris
- Syphilis
- Rhinosporidiosis
- Mucormycosis
- Aspergillosis
- Histoplasmosis
- Blastomycosis
- Sporotrichosis
- Leishmaniasis

*Non-specific*

- Foreign body granuloma
- Wegener's granulomata

*Others*

- AIDS
- Hodgkin's lymphoma
- Lethal midline granuloma (midfacial lymphoma)
- T cell lymphoma, for example, Lennert's lymphoma
- Chronic berylliosis
- Crohn's disease
- Drugs

panic membrane by presence of fluid associated with normal ear canal volume or a perforation of tympanic membrane if there is a large canal volume. Type C shows that the maximum compliance is displaced into the negative region below  $-100$  mm H<sub>2</sub>O. Type B tympanogram in the case presented suggests otitis media with effusion.

**Q4: What are the otolaryngological manifestations of sarcoidosis?**

The otolaryngological manifestations of sarcoidosis are rare and the sites most frequently affected are the mucosal surfaces of the upper aerodigestive tract including the nose, pharynx, larynx, lymph nodes, salivary glands, conjunctiva, and uveal tract. Other less common sites affected are nasopharynx, middle ear, and facial nerve. Nasal sarcoidosis occurs in 3%–20% of systemic cases. The presenting nasal symptoms include discharge which ranges from serosanguinous to mucopurulent, nasal obstruction, and epistaxis. There may be secondary sinusitis as a result of superadded infection involvement with the disease. Nasal skin and bone lesions are asymptomatic. There may be generalised swelling with discoloration of the overlying skin. Septal perforation may occur spontaneously or after septal surgery in unrecognised cases. Sarcoidosis should always be considered in recurrent alternating Bell's

palsy which is a component of Melkersson-Rosenthal syndrome. Involvement of the uveal tract in the eye and the parotid glands is seen in Heerfordt's syndrome.

**Discussion**

Sarcoidosis is a systemic disease of unknown aetiology characterised by non-caseating epithelioid granuloma of various organs. The manifestations of sarcoidosis are protean, ranging from asymptomatic but abnormal findings on chest radiography in many patients to progressive multiorgan failure in a minority. The aetiology of sarcoidosis is unknown, atypical mycobacteria tuberculi has been suggested as a causative factor but attempts to confirm this by polymerase chain reaction (PCR) has been inconclusive. It occurs world wide and affects all races, both sexes, and all ages but it is commoner in ages from 20 to 40 years. It is commoner and more severe in black people than whites.<sup>1</sup> Evidence of involvement of the nasopharynx is very rare and there have been only two reports in the literature within the past three decades.<sup>2,3</sup>

There is still no specific diagnostic test for sarcoidosis. Kveim-Siltzbach is positive in all mucosal cases and 75% of active sarcoidosis but this is no longer used because of the risk of transmission of viral hepatitis and AIDS. Transbronchial biopsy is the most useful and it is positive in 90% of pulmonary sarcoidosis. Serum angiotensin converting enzyme may be positive but it is not specific for the disease. It is useful however in assessing the activity of the disease and also as a guide to treatment with corticosteroids. There have been attempts by several groups to isolate DNA from *Mycobacteria tuberculosis* from samples of patients with sarcoidosis using sequence capture-PCR but most reports showed that *M tuberculosis* does not play a pathogenic part in sarcoidosis in most patients.<sup>4</sup>

Systemic corticosteroids remain the mainstay of treatment and the use of topical beclomethasone dipropionate has been proved to be helpful in patients whose symptoms are confined to the nasal mucosa.<sup>5</sup> Other drugs that have been used in the treatment of sarcoidosis are azathioprine, chlorambucil, and cyclophosphamide but the experience of their efficacy is anecdotal and limited.<sup>1</sup> Laser surgery may be used for reduction of granuloma in the larynx or the nose until possible spontaneous regression occurs.<sup>6</sup> Sarcoidosis is usually self limiting with spontaneous resolution, although in a few patients there is progressive downhill course, culminating in irreversible fibrosis and severe impairment of organ function.<sup>7</sup>

**Final diagnosis**

Sarcoidosis of the nasopharynx.

1 Newman LS, Rose CS, Maier LA. Sarcoidosis. *N Engl J Med* 1997;336:1224–34.

2 Weiss JA. Sarcoidosis in otolaryngology. *Laryngoscope* 1960; 70:1351–98.

3 Lanciak J, Gryczynski M. Sarcoidosis of nasopharynx. *Otolaryngol Pol* 1979;33:555–7.

4 Vokurka M, Lecossier D, du Bois RM, et al. Absence of DNA from mycobacteria of the *M tuberculosis* complex in sarcoidosis. *Am J Respir Crit Care Med* 1997;156:1000–3.



- 5 McCaffrey TV, McDonald TJ. Sarcoidosis of the nose and paranasal sinuses. *Laryngoscope* 1983;93:1281–4.
- 6 Frederiksen L-G, Jorgensen K. Sarcoidosis of the nose treated with laser surgery. *Rhinology* 1996;34:245–6.
- 7 Peckham DG, Spiteri MA. Sarcoidosis. *Postgrad Med J* 1996;72:196–200.

## A difficult psychiatric patient

### Q1: What is the diagnosis in this patient and what would you also consider?

The differential diagnosis in this patient was very wide.

- Despite the lack of obvious signs, focal sepsis such as a chest infection or a urinary tract infection would explain these symptoms in this patient.

- In this age group a significant proportion of myocardial infarcts are silent and could explain the drowsiness and loss of vigour.

- Elderly people often present with problems caused by their prescribed medication. These can include drug interactions (which increase in likelihood with increasing polypharmacy), accidental underdosing (for example Madopar), accidental overdosing (for example lithium), and in a patient with a history such as this non-accidental overdose may also be a possibility.

- A further cerebrovascular accident could have occurred.

- Fluctuating confusion can be part of Lewy body dementia which might have been the explanation for his parkinsonism combined with cognitive impairment.

- Less likely metabolic disturbances such as hypothyroidism, hypothermia, or the onset of diabetes mellitus should be considered.

- With this man's history a relapse of a depressive disorder is a strong possibility—this was what his family and community psychiatric nurse initially thought.

- The role of alcohol in this man's presentation was not clear but intoxication or withdrawal could have exacerbated any of the above.

- The actual diagnosis in this man was a chronic subdural haematoma (see fig 1).

### Q2: What particular risk factors for this condition were present in this patient?

The factors are:

- Age: more common in the elderly with a peak incidence in the seventh decade.

- Sex: more common in males (ratio 2:1–5:1).

- Risk of falls: more common than violent trauma in this age group as a cause of subdural haemorrhage. This man's cerebrovascular disease, Parkinson's disease, history of alcohol misuse, and his prescribed drugs all increase his risk of falling. In fact when this man's family were contacted to gain additional information they reported that the patient had fallen out of bed three weeks previously but he had not appeared hurt and they had not linked it with his presenting complaint.

- Subdural haematomas are more common in those with a history of alcohol misuse.

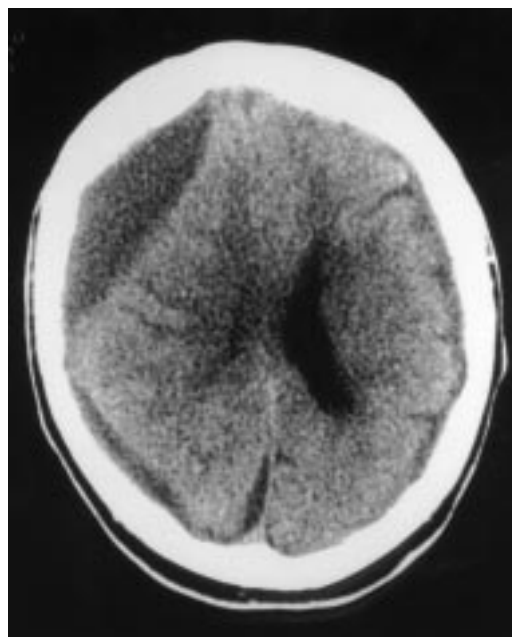


Figure 1 Non-contrast computed tomogram showing bilateral subdural haematomas, the right greater than the left with midline shift. The right subdural haematoma is exerting quite a marked mass effect with effacement of the cerebral sulci.

### Key lessons

- Always obtain an informant history if presented with a confused patient
- Not all behavioural disturbance in psychiatric patients is due to psychiatric illness
- Remember chronic subdural haematoma in confused patients especially the elderly

- Aspirin: well documented increased risk in those on antiplatelet or anticoagulant medication.

- Pre-existing cerebral atrophy increases the strain on bridging veins whose rupture leads to the haematoma itself.

### Q3: How is this condition normally managed?

Referral to a neurosurgeon. The haematoma can be drained using burr holes.

Despite his age and cognitive impairment this man was accepted by the local neurosurgeons who evacuated his haematoma via burr holes. Although he had a difficult postoperative period, he was eventually discharged home.

### Discussion

Chronic subdural haematoma has been described as “the great neurological imitator”.<sup>1</sup> It can obscure underlying disease or be obscured by it and it can simulate another neurological condition—for example, Parkinson's or even drug intoxication. The stereotypical patient is rarely seen due to difficulties obtaining a full history, the influence of comorbid illness, and the inherent variability in presentation—for example, 30% have no history of trauma and 60% have no neurological signs.<sup>2</sup> The diagnosis

may be particularly easy to miss in patients with a psychiatric history in whom behavioural disturbance is commonly ascribed to their psychiatric illness.

In one study of 88 subdural haematomas the correct diagnosis was made on admission in only 28%.<sup>3</sup> In a smaller series 8/21 subdural haematomas were only picked up at post-mortem examination.<sup>4</sup> This was a classic problem in psychiatric hospitals in the era before computed tomography. In a study of 200 post-mortems on psychiatric patients Cole found 14 subdural haematomas, only one of which had been diagnosed in life.<sup>5</sup> The importance of the diagnosis rests with the fact that the condition is usually treatable with burr hole drainage and the majority do well afterwards.

The most common reason for failure to diagnose a chronic subdural haematoma is the failure to consider it in the differential diagnosis when faced with an elderly confused patient, particularly when there are a number of diagnostic distractions.

### Final diagnosis

Chronic subdural haematoma.

- 1 Aring C. Subdural haemorrhage. *JAMA* 1960;173:1351–2.
- 2 Rozelle C, Wofford J, Branch C. Predictors of hospital mortality in older patients with subdural haematoma. *J Am Geriatr Soc* 1995;43:240–4.
- 3 Luxon L, Harrison M. Chronic subdural haematoma. *Q J Med* 1979;48:43–3.
- 4 Dronfeld M, Mead G, Langman M. Survival and death from subdural haematoma on medical wards. *Postgrad Med J* 1977;53:57–60.
- 5 Cole G. Intracranial space occupying lesions in mental hospital patients: necropsy study. *J Neurol Neurosurg Psychiatry* 1978;41:730–6.

### A rare case of radiculopathy in an elderly man

#### Q1: Describe the findings in fig 1?

Figure 1 (p 586) reveals a large soft tissue mass at the region of the left psoas muscle consistent with a large psoas abscess, a haematoma, or a soft tissue tumour. The aorta is calcified and shows a small aneurysm, 4 cm in diameter, with no obvious evidence of leak.

#### Q2: Describe the findings in fig 2?

Figure 2 (p 586) reveals a large retroperitoneal haematoma, at the site of previously diagnosed mass at the left psoas muscle, in direct communication with the aorta.

#### Q3: How the patient was managed and what was the diagnosis?

This is a case of chronic contained rupture of an abdominal aortic aneurysm (AAA).

The patient was transferred to the Vascular Unit where immediate laparotomy was performed. Retroperitoneal rupture of a 4 cm abdominal aortic aneurysm was found with a 2 cm tear in the left posterolateral wall, communicating with a large pseudoaneurysm extending from the aorta to the left flank. The aneurysm was repaired using a Dacron straight graft.

### Learning points

- Contained rupture of an aortic aneurysm should be suspected in cases of peripheral neuropathy associated with a psoas mass even if the size of the aneurysm is less than 5 cm
- A soft tissue mass within the psoas muscle and renal displacement associated with an abdominal aneurysm are the most important signs of contained aortic rupture on computed tomography.

His postoperative recovery was stormy with the onset of multiple organ failure. He died three weeks postoperatively.

The pathology of the aortic wall showed atherosclerosis. Bacteriological cultures from the aortic wall, haematoma, and psoas muscle were negative.

### Discussion

The risk of AAA rupture is associated with increasing transverse diameter of the aneurysm, and it is felt that small aneurysms, less than 5 cm, have a low risk of rupture, around 0.5% per annum.<sup>1</sup>

The diagnosis of chronic contained rupture of AAA is very difficult with the absence of the symptomatic triad of severe pain, shock, and an abdominal mass. The condition has been reported to occur in 1%–3% of cases operated upon. Misdiagnosis is very common and a rare presentation has been reported simulating obstructive jaundice,<sup>2</sup> duodenal and ureteric obstruction,<sup>3</sup> inguinal and femoral masses,<sup>4</sup> and symptomatic inguinal hernia.<sup>5</sup> Femoral and sciatic neuropathy has been documented in only few cases as a rare presentation of contained rupture of AAA.<sup>6–10</sup> It may arise from compression of the nerve or from intraneural compression of a haemorrhagic dissection into the nerve sheath.

The criteria for identifying a chronic contained rupture were described by Jones *et al* in 1986: known AAA, previous pain that may have resolved, haemodynamic stability, computed tomography showing retroperitoneal haematoma, and pathological confirmation of organised haematoma.<sup>11</sup>

Two mechanisms leading to sealed rupture seem to exist: slow haemorrhage and high resistance of the surrounding tissues.

### Final diagnosis

Chronic contained rupture of an abdominal aortic aneurysm.

- 1 Limet R, Sakalihassan N, Albert A. Determination of the expansion rate and incidence of rupture of abdominal aortic aneurysms. *J Vasc Surg* 1991;14:540–8.
- 2 Lieberman DA, Keefe EB, Rahatzad M, *et al*. Ruptured abdominal aortic aneurysm causing obstructive jaundice. *Dig Dis Sci* 1983;28:88–93.
- 3 Hodgson KJ, Webster D. Abdominal aortic aneurysm causing duodenal and ureteric obstruction. *J Vasc Surg* 1986;3:364–7.
- 4 Khaw H, Sotturrai VS, Craighead CC, *et al*. Ruptured abdominal aortic aneurysm presenting as symptomatic inguinal mass: report of six cases. *J Vasc Surg* 1986;4:384–9.

- 5 Grabowski EW, Pilcher DB. Ruptured abdominal aortic aneurysm manifesting as symptomatic inguinal hernia. *Am Surg* 1981;**47**:311–2.
- 6 Bolton PM, Blumgart LH. Neurological complications of ruptured abdominal aortic aneurysm. *Br J Surg* 1972;**59**:707–9.
- 7 Merchant RF, Cafferata HT, DePalma RG. Ruptured aortic aneurysm seen initially as acute femoral neuropathy. *Arch Surg* 1982;**117**:811–13.
- 8 Razzuk MA, Linton RR, Darling RC. Femoral neuropathy secondary to ruptured abdominal aortic aneurysms with false aneurysms. *JAMA* 1967;**201**:139–42.
- 9 Aune S, Trippestad A. Chronic contained rupture of an abdominal aortic aneurysm complicated by infection and femoral neuropathy. *Eur J Surg* 1995;**161**:613–14.
- 10 Savage CR, Gallagher EJ. Lower-limb pain in chronic rupture of abdominal aneurysms. *BMJ* 1960;**ii**:1542–3.
- 11 Jones CS, Reilly MK, Dalsing MC, et al. Chronic contained rupture of abdominal aortic aneurysms. *Arch Surg* 1986;**121**:542–6.

### How can fruits and sugar induce headache and hypoglycaemia?

#### Q1: What diagnosis would account for her “sugar intolerance” and what diagnostic test would you recommend?

This patient has a typical history of hereditary fructose intolerance. The disease, first reported in an adult in 1956 by Chambers and Pratt,<sup>1</sup> usually comes to the attention of medical professionals incidentally when a patient seeks help for a different reason. Patients with this disease generally complain of phobic symptoms, faintness, sweating, abdominal pain, nausea, and vomiting after taking sugar or fructose. They also do not enjoy sweet taste. Our patient and her brother survived infancy and early childhood, developed a self protective aversion to sweets, and remained almost symptom-free following their meat and cheese diet.

Hereditary fructose intolerance is a recessively transmitted metabolic condition caused by catalytic deficiency of aldolase B in liver, kidney, and intestine.<sup>2</sup> Aldolase B deficiency leads to inability to metabolise fructose, sorbitol, as well as other carbohydrates containing these sugars such as sucrose. The most frequent allele causing the disease in populations of northern European descent is A149P accounting for over 85% of mutant aldolase B alleles that have been studied in the UK.<sup>3</sup> Development of hypoglycaemia after fructose ingestion or infusion is the easiest confirmatory test, though it unfortunately carries some risk and discomfort to the patient. Our patient’s family doctor actually had performed that test in the past and confirmed typical biochemical changes. The other possible confirmatory studies include direct assay of fructaldolase activity in tissue (usually intestinal) biopsy,<sup>31</sup>P nuclear magnetic resonance spectroscopy to show an increase in sugar phosphates and decrease in inorganic phosphates in the liver of a patient with hereditary fructose intolerance after a fructose load, and the polymerase chain reaction combined with restriction enzyme digestion or oligonucleotide hybridisation for the most prevalent previously identified aldolase B mutations A149P, A174D, and N334K. The latter test will miss patients with rare alleles but will identify most of the patients of northern European descent.

#### Clinical symptoms and signs

- After taking sugar or fructose: symptoms of hypoglycaemia (phobic symptoms, faintness, sweating, coma, death) and gastrointestinal symptoms (abdominal pain, nausea, vomiting)
- Excellent dental health
- Aversion to sweets

#### Diagnostic tests

- Hypoglycaemia after a fructose load
- Fructaldolase activity in tissue biopsy
- <sup>31</sup>P nuclear magnetic resonance spectroscopy
- Polymerase chain reaction for the aldolase B mutations

#### Management

- Intravenous or oral glucose for hypoglycaemia
- Exclusion of fructose, sucrose, sorbitol from diet and medications
- Medic-Alert bracelets advising the prohibited sugars and treatment of hypoglycaemia

#### Q2: How would you treat hypoglycaemia in such patients?

The treatment of choice for hypoglycaemia in patients with hereditary fructose intolerance is intravenous infusion of glucose. Hypoglycaemia is thought to develop due to inhibition of both gluconeogenesis and glycogenolysis because of the accumulation of fructose-1-phosphate and depletion of inorganic phosphate due to aldolase B deficiency. The exact mode of inhibition of glycogenolysis is unknown. In vitro studies suggest that the block of glycogen breakdown occurs at the level of phosphorylase.<sup>2</sup> Fructose-1-phosphate also prevents the formation of gluconeogenic intermediates (fructose-1,6-biphosphate and glucose-6-phosphate) by competitive effects on aldolase A and glucose-6-phosphate isomerase, respectively.<sup>2</sup> In the absence of a fructose challenge there is no such metabolic inhibition and patients with hereditary fructose intolerance can tolerate prolonged fasting.

#### Q3: What needs to be done for the patient?

Fructose, a constituent of fruits, vegetables, honey, and the disaccharide sucrose (table sugar), is present at a level of 50 to 100 g in the average Western diet. If the undiagnosed infant survives the difficult initial period of weaning, the child usually develops a self protective aversion to most sweet tasting foods as did our patient and her brother. Following a voluntary diet, which is refined by trial and error over their life times, adults with the condition can

do well and remain undiagnosed for many years. A particular hazard for them has been indiscriminate use of fructose infusion as a part of total parental nutrition program. More than 20 fatal or near fatal cases resulting from this cause have been and continue to be reported in these patients.<sup>4</sup> Introduction of a strict exclusion diet brings rapid return of normal health and development. The patient should use a Medic-Alert bracelet advising the prohibited sugars and the appropriate treatment of hypoglycaemia. Sucrose and sorbitol are also

favoured components of syrups, suspensions, and coatings for tablets. Review of all prescription and over-the-counter medications is very important for patient well being.

- 1 Chambers RA, Pratt RTC. Idiosyncrasy to fructose. *Lancet* 1956;**ii**:340.
- 2 Ali M, Rellos P, Cox TM. Hereditary fructose intolerance. *J Med Genet* 1998;**35**:353–65.
- 3 Cross NCP, de Franchis R, Sebastio G, *et al.* Molecular analysis of aldolase B genes in hereditary fructose intolerance. *Lancet* 1990;**335**:306–9.
- 4 Cox TM. Iatrogenic deaths in hereditary fructose intolerance. *Arch Dis Child* 1993;**69**:413–15.