

SELF ASSESSMENT QUESTIONS

Metabolic acidosis in an Afro-Caribbean man with hyperpigmentation

D A Darko, N N Chan, A Jackson, C Peiris, D O'Shea

Answers on p 439.

A 46 year old Afro-Caribbean man presented with a 10 day history of increasing malaise, polydipsia, polyuria, and weight loss. One day before admission he had become increasingly unwell and had repeated vomiting without abdominal pain. He regularly drank six units of alcohol daily (42 units per week) and had consumed three pints of beer on the day of admission. There was no previous history of diabetes, pancreatitis, or renal disease. His mother had developed type 2 diabetes in her 30s, but no other family members were known to have diabetes or any endocrine diseases.

On examination, he was dehydrated, afebrile, mildly disorientated (Glasgow coma score 14/15), and had no stigmata of chronic liver disease. Kussmaul's type respiration and ketotic breath were evident. He was obese (body mass

index 35 kg/m²) with skin hyperpigmentation in the distribution of the nape of his neck, axillae (fig 1), and extensor surfaces. He was tachycardic with a pulse rate of 100 beats/min, and his blood pressure was 130/90 mm Hg on standing and 110/80 mm Hg sitting. Abdominal examination was unremarkable.

Biochemical investigations showed 3+ ketonuria on urine dipstick, arterial pH was 7.04, standard bicarbonate 4.0 mmol/l, carbon dioxide tension 1.89 kPa, and oxygen tension 20.0 kPa with a plasma glucose of 70 mmol/l. Serum sodium concentration was 134 mmol/l, potassium 3.6 mmol/l, urea 21 mmol/l, creatinine 196 µmol/l, and calculated plasma osmolality was 374.6 mOsm/kg (normal range 278–305). His serum amylase was raised at 184 mU/l (normal range <100). Other investigations including full blood count, liver function tests, a chest radiograph, and an electrocardiogram were all normal. Septic screen including blood and urine cultures were negative.

**Department of
Diabetes and
Endocrinology,
Charing Cross
Hospital, Fulham
Palace Road, London
W6 8RF, UK**
D A Darko
N N Chan
A Jackson
C Peiris
D O'Shea

Correspondence to:
Dr Darko (e-mail:
d.darko@ic.ac.uk)

Submitted 18 February 1999
Accepted 12 July 1999

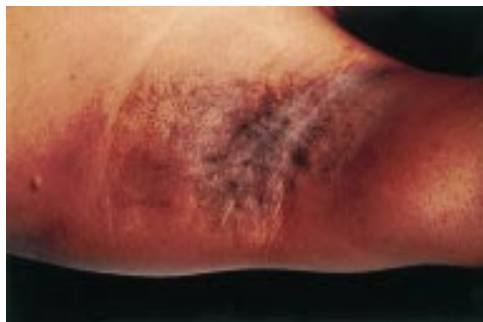

Figure 1 Hyperpigmentation in the axilla.

Questions

- (1) What is the metabolic condition in this case? Discuss the possible differential diagnosis.
- (2) What is the dermatological diagnosis (fig 1) and which endocrine/metabolic conditions is this cutaneous sign associated with?
- (3) What further investigations may be warranted in this patient?

Swelling of a metacarpophalangeal joint

A Kumar, A P Thomas

Answers on p 440.

**Department of
Trauma and
Orthopaedics, New
Cross Hospital,
Wolverhampton, UK**
A Kumar
A P Thomas

Correspondence to:
Dr A Kumar, 99 Lea House,
Bushey Fields Road, Dudley
DY1 2LU, UK

Submitted 9 June 1999
Accepted 5 July 1999

A 60 year old man was referred to the orthopaedic clinic for swelling of the metacarpophalangeal joint of the right middle finger which had gradually increased in size over the last five years. He was being treated with oral anti-inflammatory drugs for occasional discomfort. There was no history of fever, trauma, or involvement of any other joint. He had no other relevant medical history. On examination there was a slightly tender partly cystic swelling over the dorsoulnar aspect of the head of the third metacarpal. There was a fixed flexion deformity of 10 degrees at the metacarpophalangeal joint but full flexion was possible. All the routine haematological and biochemical investigations were normal. A radiograph of the right hand is shown in the fig 1.

Questions

- (1) What does the radiograph show?
- (2) What is the differential diagnosis?
- (3) How would you treat this condition?

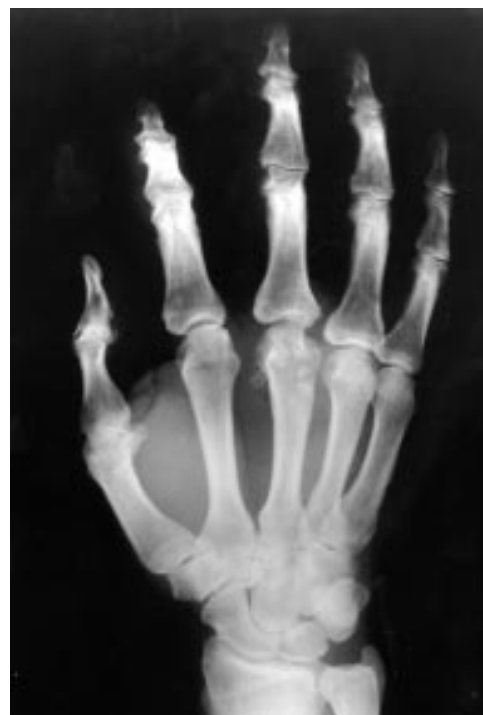

Figure 1 Radiograph of right hand.

A 30 year old male with headache and abnormal cranial magnetic resonance imaging

A S Kashyap, Shekhar Kashyap

Answers on p 441.

**Department of
Medicine, Armed
Forces Medical
College, Pune 411040,
India**
A S Kashyap

**Cardiothoracic
Centre, Golibar
Maidan, Pune, India**
S Kashyap

Correspondence to:
Dr A S Kashyap (e-mail:
skashyap@pn2.vsnl.net.in)

Submitted 19 April 1999
Accepted 13 August 1999

A 30 year old male presented with history of mild intermittent diffuse headache of few weeks' duration. There was no history of vomiting, visual disturbances, diplopia, cranial surgery, or radiotherapy. On examination he was of average built, with body mass index (weight in kg divided by height in m²) of 23. Clinically he appeared tense and anxious. Blood pressure was normal. Fundi and visual fields were normal. There was no focal neurological deficit. There were no clinical evidences of thyroid, gonadotrophin, or glucocorticoid insufficiency. Other general and systemic examinations were normal. Cranial magnetic resonance imaging (MRI) was done (fig 1).

Questions

- (1) What is the abnormality seen on MRI?
- (2) What are the two main types of this abnormality?

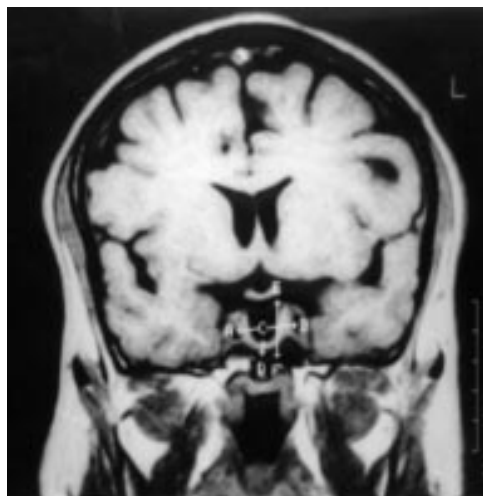


Figure 1 MRI of the brain.

Sudden hemiplegia after a motorcycle accident

A M-H Ho, J D Wells

Answers on p 442.

A 21 year old previously healthy man lost control of his motorcycle and tumbled down to the bottom of an embankment. He suffered a brief loss of consciousness, got up, and, with pain in his left arm, pushed the motorcycle up the embankment back onto the side of the road. At that point, he developed a sudden onset of dysphasia and dense right hemiplegia.

At the hospital, he was found to have normal vital signs, a closed fracture of the left humerus, right hemiplegia with no other neurological deficit, and normal computed tomography of the head. Digital subtraction left internal carotid arteriogram was immediately carried out.

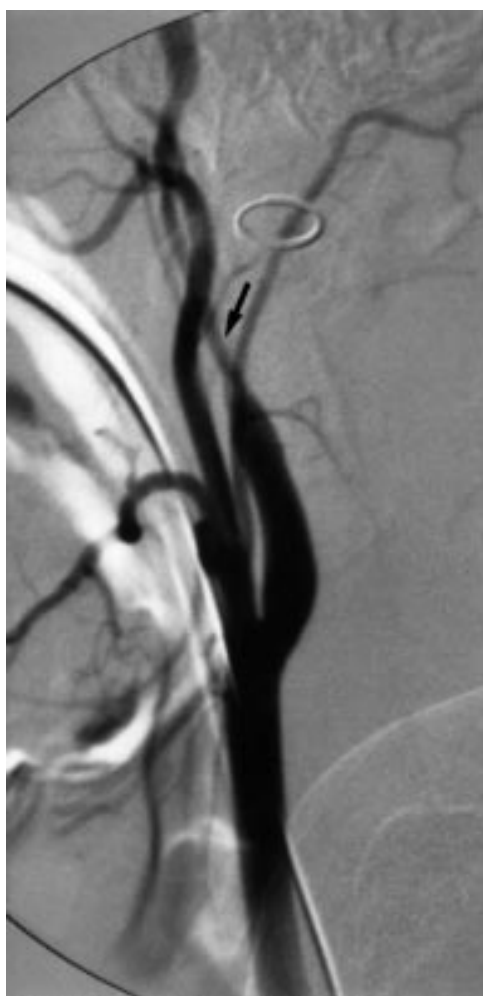

Figure 1 Lateral view of the patient's right internal carotid arteriogram using digital subtraction techniques shows a dissection.

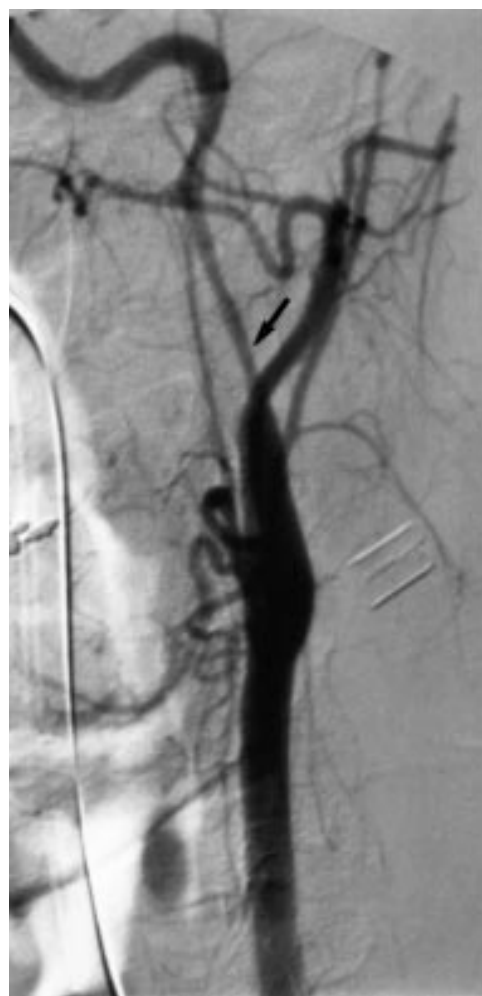

Figure 2 Oblique view of the patient's left internal carotid arteriogram shows a dissection.

Questions

- (1) What does the carotid arteriogram show (figs 1 and 2)?
- (2) What is the best way to manage this patient?
- (3) What is the differential diagnosis of acute neurological deficit after trauma?

Department of
Anaesthesia and
Intensive Care, Prince
of Wales Hospital, The
Chinese University of
Hong Kong Faculty of
Medicine, Hong Kong
A M-H Ho

Division of
Neurosurgery,
Department of
Surgery, Hamilton
Health Sciences
Corporation,
McMaster University
Faculty of Health
Sciences, Hamilton,
Ontario, Canada
J D Wells

Correspondence to:
Dr Anthony Ho, Department
of Anaesthesia and Intensive
Care, Prince of Wales
Hospital, Shatin, NT, Hong
Kong (e-mail:
hoamh@hotmail.com)

Submitted 2 July 1999
Accepted 13 August 1999

A young man with acute paraparesis

H M S Elasha, D Footitt, J Gibson, T J Wilkin

Answers on p 444.

A previously fit and well 32 year old man was admitted to the neurology ward in November 1998 with a 24 hour history of rapidly progressive leg weakness such that he was unable to stand. He felt tingling in his hands and lower legs, but no loss of sensation. Two weeks earlier he had noticed intermittent weakness in both legs. He reported no other neurological or constitutional symptoms. Twelve weeks earlier he had returned from a holiday in California.

His past medical history was unremarkable except for bronchial asthma controlled by salbutamol and beclomethasone inhalers. On further questioning, he admitted to unusually more colds than normal as well as mild fatigue and tiredness of six months' duration.

On examination, he was tanned with palmar crease and buccal pigmentation. His pulse was regular at 80 beats/min, blood pressure was 130/60 mm Hg (unable to stand to check postural drop), and his temperature was normal. The remaining general physical examination was normal. Higher mental function, cranial nerves, and speech were normal. His upper

limbs were stiff with a supinator catch but normal power, sensation, and coordination. The tone in his lower limbs was raised, with severe pyramidal distribution weakness. All the deep tendon reflexes were very brisk with flexor plantars. Pinprick sensation was subjectively diminished in both feet with no sensory level. Other sensory modalities were intact. Magnetic resonance imaging of the brain and spine were normal. Routine investigations revealed a normal full blood count, sodium concentration 116 mmol/l, potassium 8.9 mmol/l (confirmed on repeated sample), urea 17.2 mmol/l, creatinine 165 mmol/l, glucose 5.8 mmol/l, bicarbonate 15 mmol/l, chloride 86 mmol/l, and serum calcium was normal. Thyroid function was normal. An electrocardiogram is shown in fig 1.

Questions

- (1) Describe the changes in the electrocardiogram
- (2) How would you explain the neurological symptoms and signs?
- (3) What is the final diagnosis and how would you confirm it?

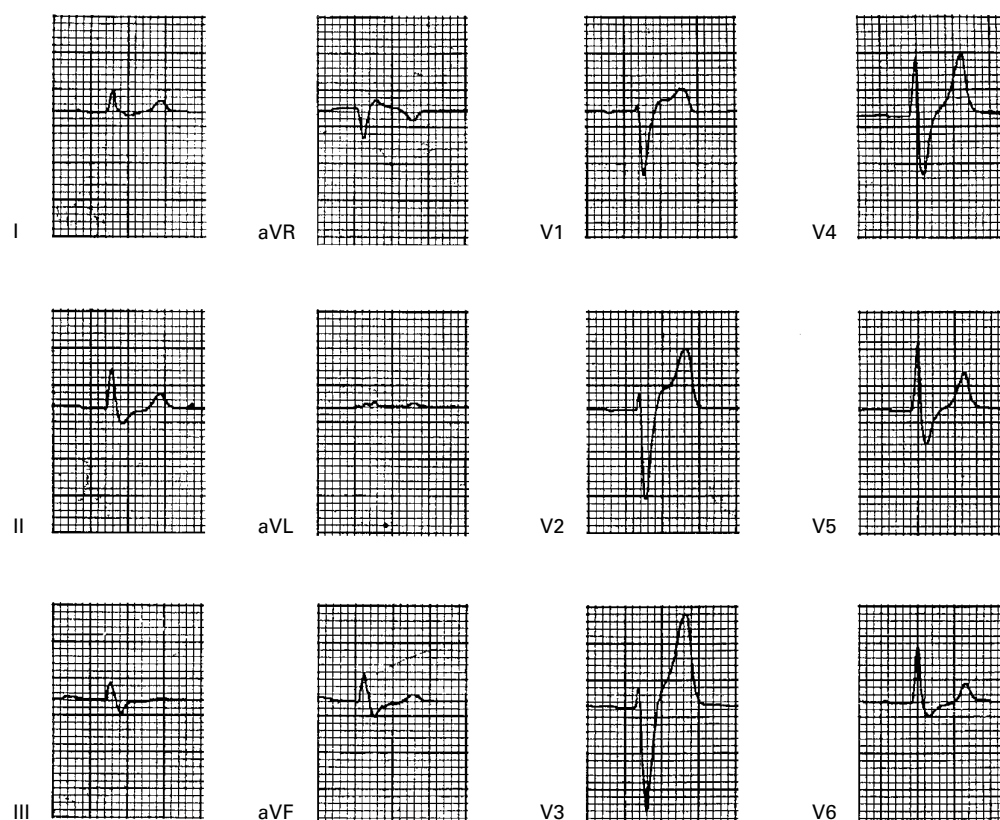


Figure 1 Electrocardiogram of patient.

**Derriford Hospital,
Plymouth, UK:
Department of
Endocrinology**
H M S Elasha
T J Wilkin

**Department of
Neurology**
D Footitt
J Gibson

Correspondence to:
Dr H M S Elasha, Medical
Department, West
Cumberland Hospital,
Hensingham, Whitehaven,
Cumbria CA28 8JG, UK
(e-mail:
Hassanelasha@yahoo.com)

Submitted 24 May 1999
Accepted 18 August 1999

Pain in the right wrist

S Shyamsundar, A L Pimpalnerkar

Answers on p 445.

A 29 year old female typist presented with a two year history of pain in her right wrist. There was no history of trauma nor was there a history of any other musculoskeletal disorder. Earlier radiographs (fig 1) and clinical examination had proved inconclusive. Subsequent radiographs were taken eight and 12 months later (figs 2 and 3).

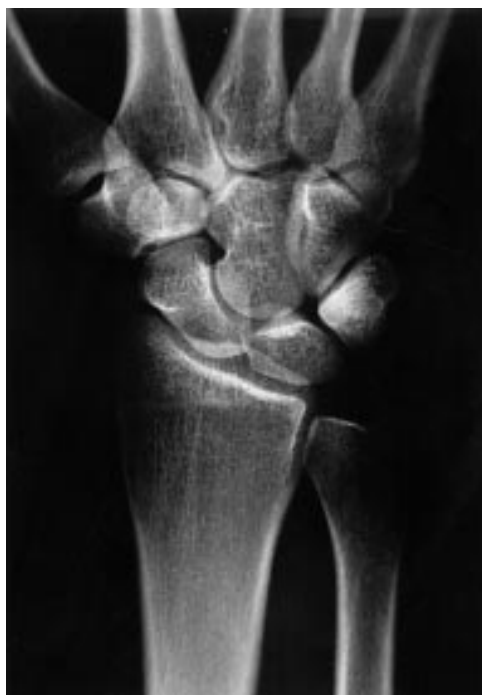

Figure 1 Radiograph of the wrist taken previously.

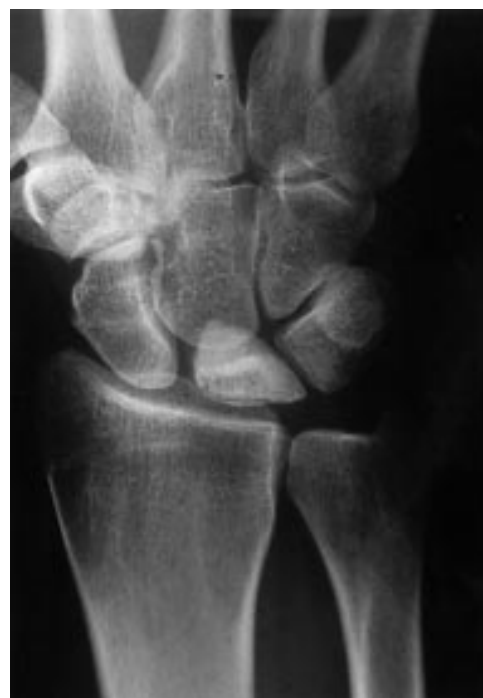

Figure 2 Radiograph of the wrist taken eight months later.

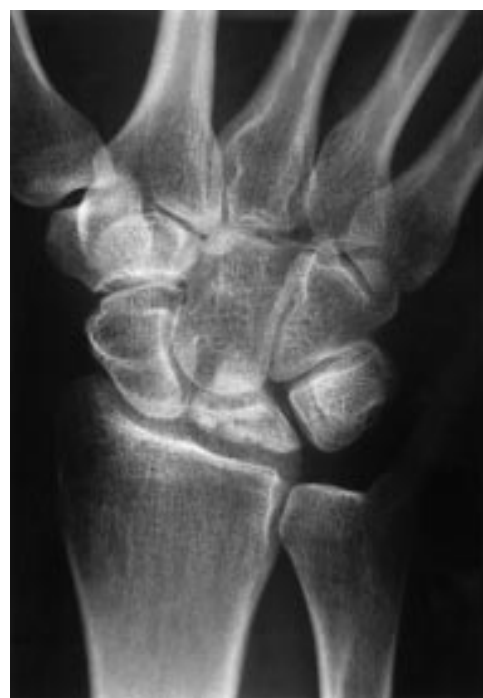

Figure 3 Radiograph of the wrist taken 12 months later.

**Department of
Orthopaedics, Royal
Bournemouth
Hospital,
Bournemouth, UK**
S Shyamsundar
A L Pimpalnerkar

Correspondence to:
Lt Cmdr A L Pimpalnerkar,
Department of
Orthopaedics, Royal Hospital
Haslar, Gosport, Hants
PO12 2AA, UK

Submitted 18 June 1999
Accepted 26 July 1999

Questions

- (1) Describe the radiographic features in figs 1, 2, and 3.
- (2) What is the clinical diagnosis? What investigation would have helped clinch the diagnosis at the first presentation.
- (3) What would be your line of management for this patient? Rationalise your answer.

Atypical cellulitis

Answers on p 446.

Debkumar Ray, Mitesh Khakhar, Alistair Flowerdew

**Department of
General Surgery,
Dorset County
Hospital, Dorchester,
Dorset, UK**

D Ray
M Khakhar
A Flowerdew

Correspondence to:
Mr D Ray, 32 Falconview,
Badger Farm, Winchester
SO22 4EP, UK (e-mail:
debkumarray@hotmail.com)

Submitted 21 May 1999
Accepted 19 August 1999

A 76 year old man was admitted to the surgical ward with a two week history of right iliac fossa pain associated with two days history of high fever (38.6°C) and right inguinoscrotal swelling. There were no associated bowel and/or urological symptoms. He was not diabetic and had a coronary artery bypass graft in 1993. On examination he was slightly confused, dehydrated, and pyrexial. Abdominal examination revealed an ill defined tender lump over right lumbar area along with a tender right inguinoscrotal swelling. There was evidence of cellulitis and spreading lymphangitis over the right groin.

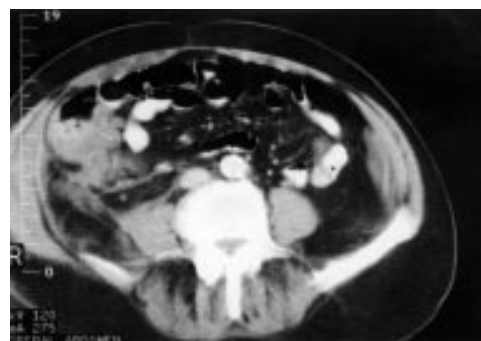

Figure 2 Computed tomogram of lumbar area.

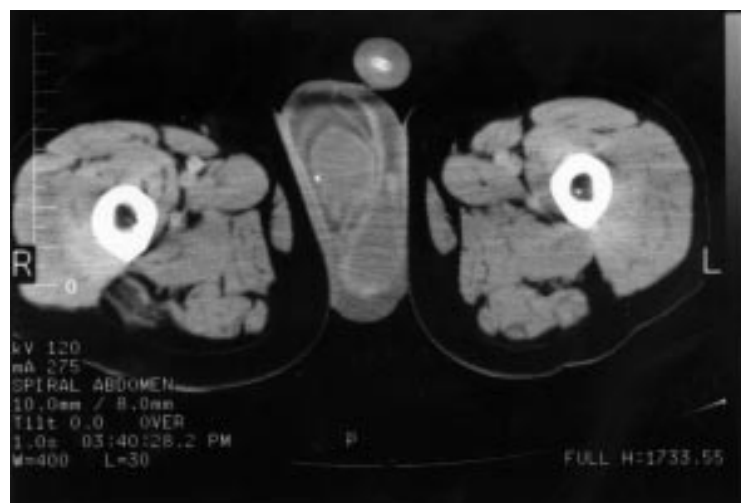


Figure 1 Computed tomogram of perineum and upper thigh.

A plain abdominal and chest x film were normal. A full blood count showed a white cell count of $10.6 \times 10^9/l$ and haemoglobin concentration of 136 g/l. Blood urea concentration was 10.9 mmol/l and serum creatinine 86 mmol/l. Computed tomography was performed next morning.

Two interesting sections of the scan are shown in figs 1 and 2.

Questions

- (1) What are the computed tomography findings in figs 1 and 2?
- (2) What is the most likely diagnosis?
- (3) What should be the next step of management?

An interesting electrolyte problem

Ruxana T Sadikot, Ivan M Robbins

Answers on p 447.

**Department of
Medicine, Division of
Allergy, Pulmonary
and Critical Care
Medicine, Vanderbilt
University School Of
Medicine and
Department of
Veterans Affairs
Medical Center,
Nashville, Tennessee,
USA**

R T Sadikot
I M Robbins

Correspondence to:
Dr Ruxana T Sadikot,
Division of Allergy,
Pulmonary and Critical Care
Medicine, Vanderbilt
University School of
Medicine, T-1217 MCN,
Center for Lung Research,
Nashville, TN 37232-2650,
USA (e-mail:
RTSadikot@POL.net)

Submitted 20 July 1999
Accepted 13 August 1999

A 76 year old white man was admitted to the intensive care unit with a one day history of confusion, altered mental status, and a three day history of nausea, vomiting, and abdominal discomfort. On the day of admission he was initially taken to a local hospital where a nasogastric tube was placed and three litres of blood tinged aspirate was obtained. The patient was transferred to our facility for further care. His past medical history was significant for hypertension, peptic ulcer disease and long standing constipation for which he used 2–3 bottles per day of milk of magnesia. His other prescribed medications included amlodipine and vitamin supplements. He denied use of alcohol or illicit drugs. On examination he was afebrile, his blood pressure was

106/52, and pulse rate 93 beats/min. He was confused and disorientated to time and place. His abdomen was soft to palpation with hypoactive bowel sounds. There were no focal neurological signs. The remainder of the physical examination was unremarkable. His baseline and initial electrolytes are shown in table 1. Results of a liver function test and complete blood count were within normal limits.

Questions

- (1) What additional history would help in making a diagnosis?
- (2) What is the most likely explanation for the electrolyte disturbance?

Table 1

	Baseline (serum)	Admission (serum)	Post-treatment (serum)	Urine electrolytes (on admission)
Sodium (mmol/l)	140	141	143	12
Potassium (mmol/l)	4.2	3.0	4.0	22
Chloride (mmol/l)	105	60	110	12
Bicarbonate (mmol/l)	28	65	27	—
Calcium (mmol/l)	23	3.6	2.1	—
Magnesium (mmol/l)	0.9	2.6	0.9	—
BUN (mmol/l of urea)	3.6	31.7	15.0	—
Creatinine (μmol/l)	79.6	530.4	168.0	—
pH	—	7.46	7.42	—
Pco ₂ (kPa)	—	5.6	5.1	—

BUN = blood urea nitrogen; Pco₂ = carbon dioxide tension.

Respiratory compromise relieved by laparotomy

Anu Bali, David A Walker, John P Iredale, Colin D Johnson

Answers on p 448.

**Southampton
University Hospital,
Southampton, UK**
A Bali
J P Iredale

**Intensive Care Unit,
Queen Alexandra
Hospital, Portsmouth,
UK**
D A Walker

**University
Department of
Surgery, Southampton
University Hospital,
Southampton, UK**
C D Johnson

Correspondence to:
Dr J P Iredale, University
Department of Medicine,
Mail point 811,
Southampton University
Hospital, Tremona Road,
Southampton SO16 6YD,
UK (e-mail:
jpi@soton.ac.uk)

Submitted 6 July 1998
Accepted 26 July 1999

A 40 year old woman presented with a four month history of lethargy, reduced appetite, diarrhoea, and weight loss. In addition she complained of shortness of breath on exertion. Her alcohol intake was high with consumption in excess of 28 units of alcohol per day. Eighteen months previously she had been investigated at another hospital for epigastric pain and had been found to have a pancreatic pseudocyst of 3 cm in diameter and she was advised to stop drinking alcohol. There was no other past medical history of note. Examination at first presentation revealed the presence of spider naevi with an enlarged liver, extending some 7 cm below the costal margin, with marked ascites, raised serum amylase and liver enzymes: alkaline phosphatase 362 IU/l, alanine aminotransferase 24 IU/l, amylase 118 IU/l, and γ -glutamyltransferase 835 IU/l. The provisional clinical diagnosis made was advanced alcoholic liver disease with cirrhosis. An outpatient chest radiograph and abdominal ultrasound were arranged and a follow up appointment made for one month.

After the ultrasound, urgent admission was arranged. She had developed symptoms of breathlessness that were sufficiently severe that walking to the bathroom precipitated dyspnoea. On examination she had a displaced cardiac apex beat, a third heart sound, reduced breath sounds at both lung bases, and a mass in the right upper quadrant of her abdomen. Her biochemistry tests were repeated: alkaline phosphatase 464 IU/l; alanine aminotransferase 12 IU/l, amylase 446 IU/l, and γ -glutamyltransferase 186 IU/l. Chest radiographs at admission are shown in figs 1A and B.

Questions

- (1) What does the chest radiograph show and what would be your next investigation?
- (2) What is the diagnosis and how would you manage this patient?

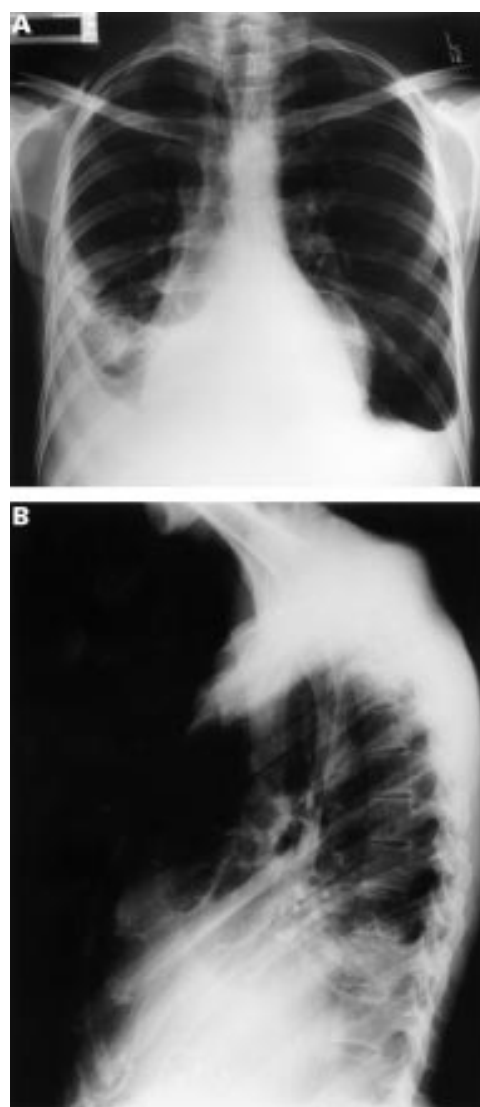


Figure 1 Chest radiographs: anteroposterior (A) and lateral (B) views.

Chronic non-healing ulcers of the scalp after trauma

Vyjayanti Kulkarni, Vedantam Rajshekhar

Answers on p 450.

**Department of
Neurological Sciences,
Christian Medical
College Hospital,
Vellore, India 632004**
V Kulkarni
V Rajshekhar

Correspondence to:
Dr V Rajshekhar, CMC
Hospital, Vellore, 632004,
India (e-mail:
v_rajshekhar@hotmail.com)

Submitted 19 April 1999
Accepted 26 July 1999

A 11 year old boy presented with soft tissue swelling and multiple discharging sinuses over the forehead, which he had had for past eight months. There was no history of tuberculosis or any major illness. There had been no response to antibiotic treatment. He had sustained a forehead laceration in a road traffic accident, four years ago, which was primarily sutured and had healed well. Systemic and neurological examinations were normal. Local examination revealed a soft to firm, subcutaneous swelling over the forehead with multiple sinuses, discharging serosanguinous and granular material.

The biochemical tests were unremarkable except for a high erythrocyte sedimentation rate of 125 mm/hour. HIV testing was negative. Chest radiography showed no abnormality. The skull x ray film showed irregular patchy areas of radiolucencies in the right frontal and anterior parietal bones, with no surrounding sclerosis (figs 1 and 2). Cranial computed tomography revealed corresponding bone hypodensities, with a thin layer of epidural enhancement.

Questions

- (1) What is the differential diagnosis of this clinical presentation and radiological picture?
- (2) How should this patient be managed?
- (3) What is the optimal treatment of this condition?

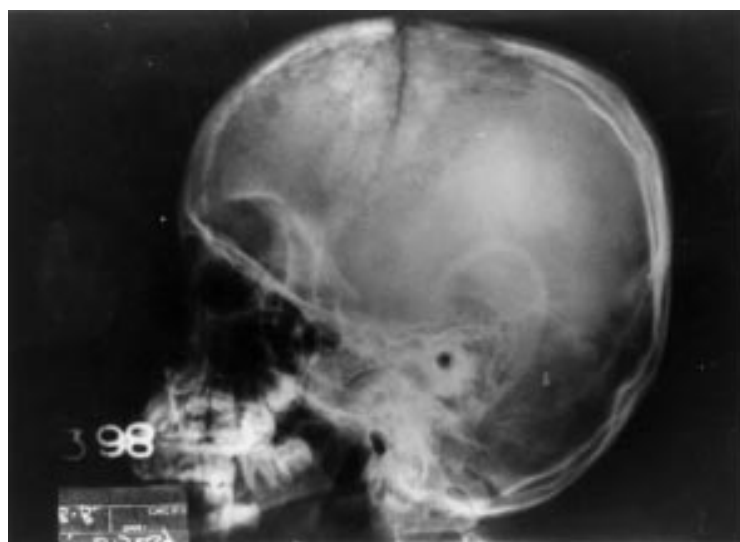

Figure 1 Plain radiograph of the skull, lateral view, showing multiple irregular patchy radiolucencies involving the frontal and parietal bones.

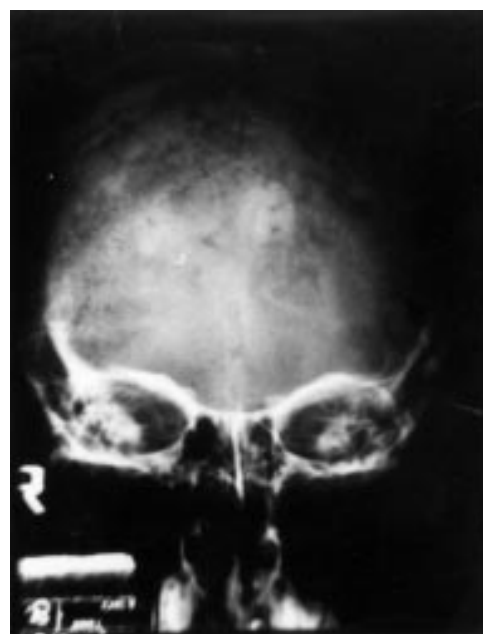


Figure 2 Plain radiograph of the skull, anteroposterior view, showing multiple irregular patchy radiolucencies involving frontal and parietal bones.

An unusual complication of carcinoma of the caecum

Answers on p 451.

Y Ramkissoon, H Ghoorahoo, S F Haydock, K M O'Shaughnessy

Clinical Pharmacology Unit, Department of Medicine, Addenbrooke's Hospital, Cambridge, UK

Y Ramkissoon
H Ghoorahoo
S F Haydock
K M O'Shaughnessy

Correspondence to:
Dr K M O'Shaughnessy,
Clinical Pharmacology Unit,
Addenbrooke's Centre for
Clinical Investigation, Box
110, Addenbrooke's
Hospital, Hills Road,
Cambridge CB2 2QQ, UK
(e-mail:
kmo22@medschl.cam.ac.uk)

Submitted 21 April 1999
Accepted 19 August 1999

A 64 year old woman presented with loss of appetite, weight loss, and altered bowel habit. A barium enema confirmed the presence of a caecal carcinoma. A liver ultrasound scan was normal and admission for a right hemicolectomy was planned. Three days before the planned admission, she awoke with severe pain in the left gluteal region. Over the next few hours the pain increased in severity and the affected region became swollen and discoloured. She was referred for hospital admission. On arrival at hospital she was apyrexial, with a tachycardia of 120 beats/min but a blood pressure of 140/86 mm Hg. She was noted to have a large (>10 cm) well demarcated area of reddish purple discoloration over her left thigh. Power and reflexes were reduced in the left leg. The area of the lesion spread rapidly and

crepitus developed. A surgical opinion was sought. An urgent computed tomogram was requested to determine the full extent of the lesion before surgical intervention. Images were obtained of the pelvic and gluteal region (fig 1) and the thorax (fig 2). The patient remained alert and comfortable during the imaging. Shortly after the scan was completed, however, the patient suffered a cardiac arrest with electromechanical dissociation and died.

Questions

- (1) What abnormality is seen on the computed tomogram in fig 1?
- (2) What is the lethal abnormality present on the computed tomogram in fig 2?
- (3) What is the underlying diagnosis and what are the treatment options for this condition?

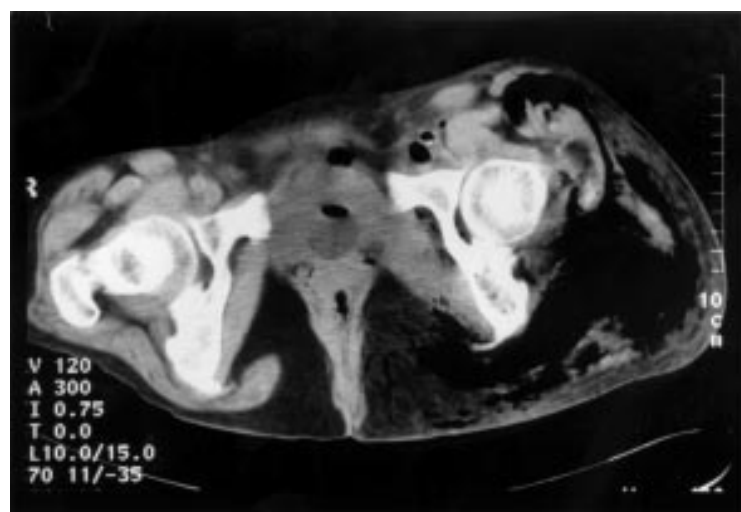

Figure 1 Computed tomogram of thigh region.

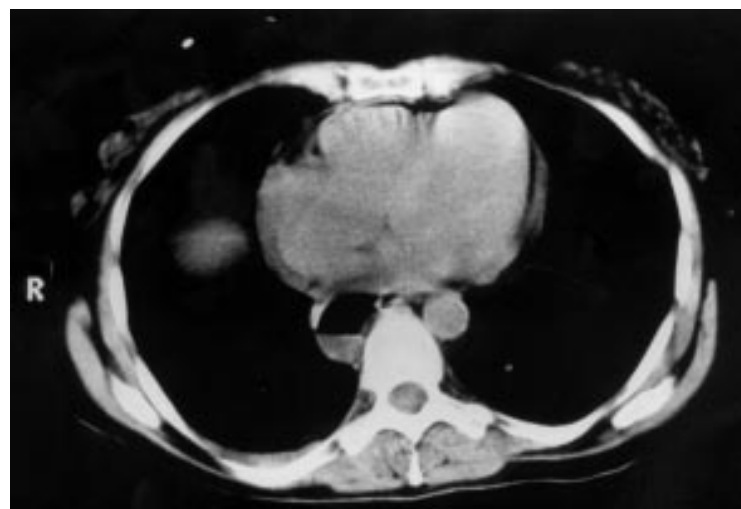


Figure 2 Computed tomogram of thorax.

SELF ASSESSMENT ANSWERS

Metabolic acidosis in an Afro-Caribbean man with hyperpigmentation**Q1: What is the metabolic condition in this case? Discuss the possible differential diagnosis**

The presence of marked hyperglycaemia, ketonuria, and metabolic acidosis confirmed the diagnosis of diabetic ketoacidosis. Other possible causes of anion gap metabolic acidosis in this case include alcoholic ketoacidosis, acute pancreatitis, and acute renal failure with uraemic acidosis.

Although alcohol may have contributed to the development of ketoacidosis in this case, it is unlikely to be the sole cause since plasma glucose is often low or normal in alcoholic ketoacidosis¹ whereas it is markedly raised in this case. The increased serum amylase raises the possibility of acute pancreatitis which may lead to lactic acidosis. However the patient did not have abdominal pain throughout the course of his illness, and serial measurements of the serum amylase showed further elevation. The mildly increased serum amylase was more likely due to the renal impairment as amylase is renally excreted. Finally, the uraemia in acute renal failure may have contributed to the metabolic acidosis, although not to a great extent as the renal function (peak plasma urea was 21 mmol/l) of our patient improved almost immediately after treatment.

Q2: What is the dermatological diagnosis (fig 1, p 429) and which endocrine/metabolic conditions is this cutaneous sign associated with?

The presence of velvety, rough, and hyperpigmented skin in the distribution of the nape of the neck, axilla, and extensor surfaces is consistent with the clinical diagnosis of acanthosis nigricans. This cutaneous sign is associated with many endocrine and metabolic conditions as listed in box 1.^{2,3}

Box 1: Acanthosis nigricans: endocrine/metabolic associations^{2,3}

- Obesity
- Insulin resistance
- Hyperinsulinaemia
- Type 2 diabetes mellitus
- Hypothyroidism
- Hypogonadism
- Hyperprolactinaemia
- Addison's disease
- Cushing's syndrome
- Acromegaly
- Polycystic ovary syndrome
- Pituitary tumours

Q3: What further investigations may be warranted in this patient?

Further investigations should aim at excluding other causes of metabolic acidosis, screening for potential metabolic/endocrine pathologies associated with acanthosis nigricans, and predicting future insulin requirement in this patient.

In this patient endocrine investigations were unremarkable including growth hormone, insulin like growth factor-1, androgen profile, overnight dexamethasone suppression test, and 24 hour urinary free cortisol on two separate occasions. He had autonomous insulin secretion as evidenced by a fasting serum C peptide of 1231 pmol/l and in addition negative anti-islet cell and antiglutamic acid decarboxylase (GAD) antibodies.

Clinical course

This patient made good progress after initiation of treatment with intravenous fluid, insulin infusion, and prophylactic broad spectrum antibiotics. His serum amylase, plasma urea, and creatinine returned to normal. A random serum cholesterol was 4.3 mmol/l and triglyceride 2.86 mmol/l. He made an uncomplicated recovery and was discharged on Human Mixtard 30/70 36 units twice daily with dietary advice. After dietary modification, his home glucose reading was excellent (4–6 mmol/l) which led to gradual reduction and finally withdrawal of insulin. With diet control alone, his fasting glucose remained satisfactory at 6.4 mmol/l and HbA1c of 5.9% when reviewed nine months later despite no significant change in his weight.

Discussion

Diabetic ketoacidosis is common in type 1 diabetes, although it can also occur in type 2 diabetes^{4,5} usually in the presence of metabolic stress or pancreatic β -cell failure. Rarely, diabetic ketoacidosis can also occur in insulin resistant states such as acanthosis nigricans⁶ and acromegaly.⁷ The aetiology of diabetic ketoacidosis occurring in the presence of circulating insulin in these resistant states remains unclear but may be related to severe underlying insulin resistance.

The recognition of underlying insulin resistance is important in the management of these patients. Conventionally, the occurrence of diabetic ketoacidosis signifies the requirement of lifelong insulin therapy. However, in individuals with insulin resistance long term insulin therapy may lead to weight gain, which could worsen the underlying insulin resistance. The clinical course of our patient would suggest that the glucose intolerance in this group of patients may be satisfactorily controlled with diet alone. The absence of anti-islet cell and GAD antibodies (an investigation not readily available currently in secondary care) suggest that they are unlikely to be insulin dependent in the future.⁸ Similar cases have

Learning points

- Acanthosis nigricans is commonly associated with insulin resistance and type 2 diabetes.
- Diabetic ketoacidosis, the hallmark of type 1 diabetes, may also occur in type 2 diabetes associated with insulin resistant states.
- Normoglycaemic remission may occur in ketoacidosis onset type 2 diabetes.
- Antibodies to islet cells and GAD antibodies may serve as a useful guide to predict future insulin dependency.

previously been described in a series of African-American type 2 diabetic patients (n=79), with negative anti-islet cell and GAD antibodies who presented with hyperglycaemia with or without ketoacidosis, and were insulin independent at 3–12 months of initial presentation.⁹ Near normoglycaemic remission on dietary treatment alone, lasted a median of 3.5 years and about 15% of their patients had a remission greater than five years.⁹ It is been proposed that differences in β -cell glucose sensitivity and insulin secretion exist within ethnic populations, and the African-American type 2 diabetic subjects may have a greater β -cell insulin secretory defect.¹⁰ Close follow up of these patients and their insulin requirements is important to determine which diagnostic category, ketoacidosis onset type 2 diabetes or late onset type 1 diabetes, they fall into.

Final diagnosis

Diabetic ketoacidosis and acanthosis nigricans.

- 1 Fulop M. Alcoholic hypoglycaemia and ketosis. *West J Med* 1979;131:321–2.
- 2 Matsuoka LY, Wortsman J, Gavin JR, *et al.* Spectrum of endocrine abnormalities associated with acanthosis nigricans. *Am J Med* 1987;83:719–25.
- 3 Winkelmann RK, Randolph Scheen S, Underdahl LO. Acanthosis nigricans and endocrine disease. *JAMA* 1960; 174:1145–52.
- 4 Bagg W, Sathu A, Streat S, *et al.* Diabetic ketoacidosis in adults at Auckland Hospital, 1988–1996. *Aust N Z J Med* 1998;28:604–8.
- 5 Nagasaka S, Ishikawa SE, Itabashi N, *et al.* Ketoacidosis-onset type 2 diabetes in Japanese. *Diabetes Care* 1998;21: 1376–7.
- 6 Bau CT, Sheu WHH, Song YM, *et al.* Acanthosis nigricans and diabetic ketoacidosis. *Diabetes Care* 1997;20:1202.
- 7 Katz JR, Edwards R, Khan M, *et al.* Acromegaly presenting with diabetic ketoacidosis. *Postgrad Med J* 1996;72:682–3.
- 8 Littorin B, Sundkvist G, Hagopian W, *et al.* Islet cell and glutamic acid decarboxylase antibodies present at diagnosis of diabetes predict the need for insulin treatment. *Diabetes Care* 1999;22:409–12.
- 9 Banerji MA, Chaiken RL, Lebovitz HE. Long-term normoglycemic remission in black newly diagnosed NIDDM subjects. *Diabetes* 1996;45:337–41.
- 10 Osei K, Gaillard T, Schuster DP. Pathogenetic mechanism of impaired glucose tolerance and type 2 diabetes in African-Americans: the significance of insulin secretion, insulin sensitivity and glucose effectiveness. *Diabetes Care* 1997;20:396–404.

Swelling of a metacarpophalangeal joint

Q1: What does the radiograph show?

Radiograph shows multiple rounded areas of calcification over the head of third metacarpal and erosion of the head of the metacarpal.

Q2: What is the differential diagnosis?

The most likely diagnosis on the basis of history, clinical examination, and radiographic appearance is synovial osteochondromatosis. The other possible differential diagnoses are listed in box 1.

Box 1: Differential diagnoses

- Rheumatoid arthritis
- Chronic infection (including tuberculosis)
- Trauma: osteochondral fracture
- Osteochondritis dissecans
- Osteoarthritis
- Neuropathic arthritis
- Gout

Q3: How would you treat this condition?

Treatment usually involves removal of the osteocartilaginous nodules with excision of the involved synovium.

Discussion

Synovial chondromatosis is an uncommon pathological condition which mostly involves the synovium of a large joint and rarely occurs in the hand. However a few cases affecting small joints of the hand have been reported in the literature.^{1–4} Pathologically it arises from metaplasia of the synovium of the joint and rarely the tendon sheaths. It has been postulated that the multipotential synovioblasts under unknown conditions undergo multifocal metaplasia to form chondroblasts leading to formation of cartilaginous nodules. These nodules can later undergo secondary ossification.^{5,6}

The clinical diagnosis of synovial chondromatosis can be difficult because of non-specific signs and symptoms and rarity of the condition. This disease should be considered in the differential diagnosis of a swollen and painful joint. The common presenting symptoms are pain, swelling, and stiffness of the joint. Physical examination may show tenderness, effusion, and palpable nodules. The radiographic appearance depends upon the extent of ossification of the cartilaginous nodules. In the absence of such ossification the radiograph may show no abnormality and preoperative diagnosis may be difficult. When the lesion occurs with in the capsule of a small joint which has only limited capacity for expansion, secondary erosion of the bone can be seen. In this situation synovial chondrosarcoma should be ruled out on histological examination.

Histological examination shows multiple cartilaginous masses beneath the synovium. These cartilaginous masses may separate from the synovium to form loose bodies. If the cartilaginous masses undergo ossification the condition is termed as synovial osteochondromatosis. The synovial origin of these cartilaginous masses should be emphasised to differentiate this condition from others. As histopathology often shows an increased cellularity and

nuclear atypia it is essential to avoid an erroneous diagnosis of chondrosarcoma which requires a totally different management.^{1 5}

The natural history of the disease is of slow progression and may be self limiting⁶ but if untreated for a long duration, it can lead to an extensive destruction of adjacent bony structures.¹ Malignant transformation, though reported,⁷ is uncommon. Although a case of spontaneous regression of the disease involving the knee joint has been reported,⁸ the treatment usually involves removal of the cartilaginous nodules with en bloc excision of the involved synovium.

Progress

The swelling was excised under general anaesthesia. There was a loosely encapsulated mass of immature cartilage arising from the dorsum of the metacarpophalangeal joint under the extensor hood. The histopathology was reported as synovial tissue together with fragments of varying sizes containing lobulated hyaline chondroid tissue with no features of malignancy (fig 1 below). The patient remains asymptomatic after three years of follow up.

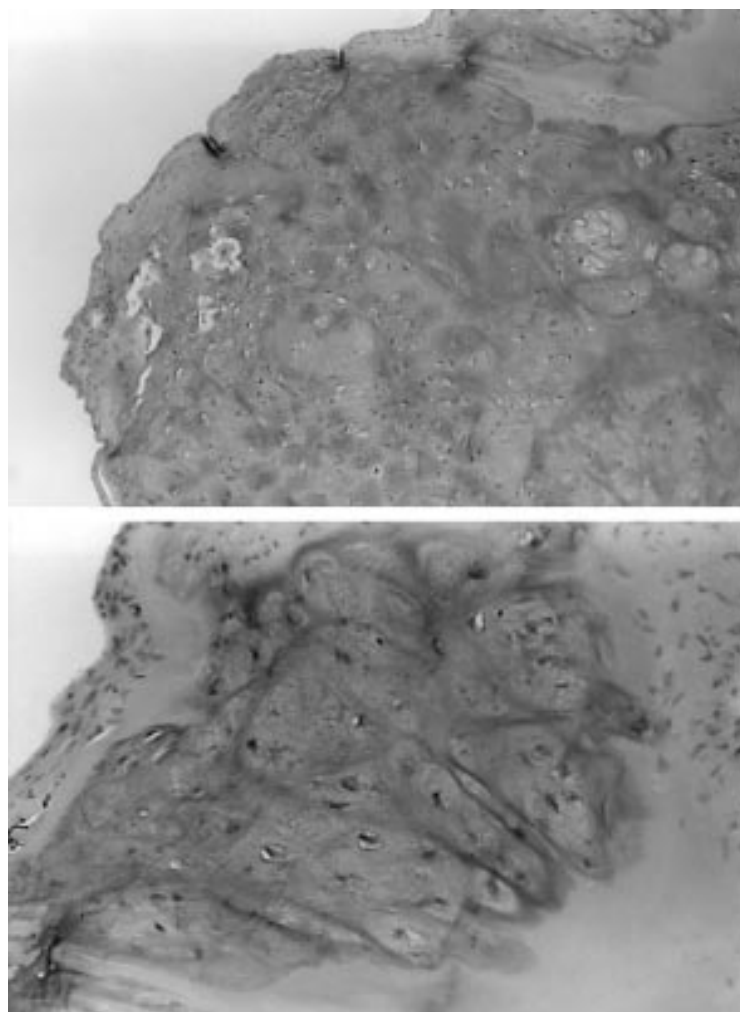


Figure 1 Photograph of the histology of the lesion showing lobulated hyaline chondroid tissue (haematoxylin and eosin; upper magnification $\times 20$, lower magnification $\times 160$).

Final diagnosis

Intra-articular synovial osteochondromatosis.

- 1 Constant E, Harebottle NH, Davis DG. Synovial chondromatosis of the hand. *Plast Reconstr Surg* 1974;54:353–8.
- 2 Cremone JC, Wolff TW, Wolford FG. Synovial chondromatosis of the hand. *Plast Reconstr Surg* 1982;69:871–4.
- 3 Takami H, Takahashi S, Ando M. Synovial chondromatosis of the proximal interphalangeal joint of a finger. *J Hand Surg [Am]* 1994;19:794–6.
- 4 Reed SC, Wright CS. Synovial chondromatosis of the metacarpophalangeal joint: case report and review of the literature. *Can J Surg* 1996;39:407–9.
- 5 Murphy FP, Dahlin DC, Sullivan CR. Articular synovial chondromatosis. *J Bone Joint Surg Am* 1962;44:77–86.
- 6 Jeffreys TE. Synovial chondromatosis. *J Bone Joint Surg Br* 1967;49:530–4.
- 7 Mullins F, Berard CW, Eisenberg SH. Chondrosarcoma following synovial chondromatosis. *Cancer* 1965;18:1180–8.
- 8 Swan EF, Owens WF. Synovial chondrometaplasia: a case report with spontaneous regression and a review of the literature. *South Med J* 1972;65:1496–500.

A 30 year old male with headache and abnormal cranial magnetic resonance imaging

Q1: What is the abnormality seen on magnetic resonance imaging (see p 430)?

Coronal contrast enhanced T1 weighted MRI scan through pituitary region demonstrates an enlarged sella turcica (C) with normally enhancing pituitary tissue (I) displaced inferiorly, an abnormality suggestive of empty sella. Optic chiasm (E), intracavernous carotid arteries (A: right and B: left side and sphenoid sinus (D, F) are clearly visible. This is often an incidental radiological finding and in most cases there is no associated abnormality of pituitary function. Pituitary fossa enlargement is a result of communicating extension of sub-arachnoid space (chiasmatic cistern) into the pituitary fossa. This promotes remodelling and enlargement of the bony sella. The pituitary gland is usually flattened against the floor of the sella, and the pituitary stalk may be deviated laterally.¹

Q2: What are the two main types of this abnormality?

An empty sella can occur as a result of congenital diaphragmatic defect (primary empty sella) or damage to the diaphragm by surgery, radiation therapy, or pituitary tumour infarction (secondary empty sella).

Discussion

A primary empty sella is a fairly common incidental radiological finding and is usually associated with only minor disturbances of pituitary function. In this condition the sella tends to be symmetrically ballooned without bony erosion. Suprasellar subarachnoid space (chiasmatic cistern) herniates through an incomplete diaphragma sella, so that the sella is filled with cerebrospinal fluid (CSF) within an arachnoid lined sac. An incomplete diaphragma sella appears to be a prerequisite. Whether persistently or transiently increased CSF pressure is required to produce sella enlargement in these patients is not clear. CSF pressure is generally normal, when measured, in these patients. Pituitary volume is usually

normal; this is in contrast with partially empty sella caused by a degenerated pituitary adenoma, where the pituitary volume is usually increased.

Most patients with primary empty sella are obese, multiparous women with headaches; about 30% have hypertension.² Selection bias cannot be excluded in case reports, since skull radiographs may be obtained in patients with headache, which in turn, uncovers the empty sella. Most patients with a primary empty sella have normal pituitary function, and approximately 15% have mild hyperprolactinaemia (usually <100 µg/l, with or without galactorrhoea and amenorrhoea). Hyperprolactinaemia may be due to stalk stretching or coincidental microprolactinomas. Since even a mild prolactin increase may result in gonadal dysfunction, this may merit treatment, but patients should be reassured that this problem is usually unlikely to result in additional pituitary dysfunction. The development of pituitary dysfunction appears to be related to the degree of sellar enlargement as demonstrated by computed tomography in 56 adults with normal pituitary function and 11 patients with hypopituitarism.³ Development of growth hormone secretory reserve is often abnormal in these patients, probably as a result of obesity. Spontaneous CSF rhinorrhoea and pseudotumour cerebri have each been reported in 10% of these patients, but this association may represent an ascertainment bias.² CSF rhinorrhoea may need surgical correction. Visual field defects have been reported and are thought to be due to herniation of the optic chiasm into the sella turcica. Once diagnosis of primary empty sella syndrome is established on MRI or computed tomography, further diagnostic studies should be performed to exclude hormone excess or deficiency: when hormone concentrations are normal, therapy is reassurance.

Primary empty sella syndrome can also occur in children, with an incidence of 48% in children with either an isolated growth hormone deficiency or a combination of pituitary hormone deficiencies; only 2% of children with normal pituitary function have empty sella.³ Primary empty sella syndrome may be associated with central precocious puberty.⁴ Association with midline defects and cleft palate has been documented.⁵

In secondary empty sella associated with destruction of pituitary gland, hypopituitarism is the outcome. Pituitary destruction occurs when a large pituitary adenoma undergoes infarction (usually a haemorrhage) or as a consequence of surgical resection. Hypopituitarism may be partial or complete, and measurement of serum pituitary and target organ hormones is necessary to establish the diagnosis of hormone deficiency and to determine the central (hypothalamic or pituitary) cause of the dysfunction.⁶

Follow up

This patient's serum corticotrophin and cortisol; thyrotrophin and thyroxine, luteinising hormone and testosterone, and prolactin con-

Learning points

Primary empty sella

- Common incidental radiological finding.
- Pituitary functions usually normal.
- Mild hyperprolactinaemia occurs in 15% of patients.

Secondary empty sella

- Result of damage to diaphragma sella by surgery or radiotherapy.
- Result of pituitary tumour infarction.
- Partial or complete hypopituitarism: common.

centrations were normal. The patient refused to undergo stimulation tests for growth hormone deficiency. He was reassured and treated symptomatically for his headache with good results. Cause of the headache is most likely tension, and is unrelated to primary empty sella syndrome. He is on regular follow up in the endocrinology clinic.

Final diagnosis

Primary empty sella syndrome and tension headache.

- 1 Vance ML. Hypopituitarism. *N Engl J Med* 1994;330:1651–62.
- 2 Biller BMK, Daniels GH. Neuroendocrine regulation and diseases of the anterior pituitary and hypothalamus. In: Fauci AS, Braunwald E, Isselbacher KJ, *et al*, eds. *Harrison's principles of internal medicine*. New York: McGraw-Hill, 1998: 1972–99.
- 3 Pocecco M, de Campo C, Marinoni S, *et al*. High frequency of empty sella syndrome in children with growth hormone deficiency. *Helv Paediatr Acta* 1988;43:295–301.
- 4 Rappaport R, Logrono R. Primary empty sella syndrome in childhood: association with precocious puberty. *Clin Pediatr (Phila)* 1991;30:466–71.
- 5 Laron Z, Taube E, Kaplan I. Pituitary growth hormone insufficiency associated with cleft lip and palate: an embryonal developmental defect. *Helv Paediatr Acta* 1997;24:576–81.
- 6 Thorner MO, Vance ML, Laws ER Jr, *et al*. The anterior pituitary. In: Wilson JD, Foster DW, Kronenberg HM, *et al*, eds. *Williams textbook of endocrinology*. Philadelphia: W B Saunders, 1998: 249–340.

Sudden hemiplegia after a motorcycle accident

Q1: What does the carotid arteriogram show?

The digital subtraction arteriogram reveals dissection of the left internal carotid artery. The lateral (fig 1) and oblique (fig 2) views are shown (see p 431). The middle third of the internal carotid artery shows marked narrowing giving it a rat-tail appearance (arrows). This extends to the petrous segment, beyond which the vessel is normal.

Q2: What is the best way to manage this patient?

The patient was immediately started on intravenous heparin therapy, with the target activated partial thromboplastin time set at 2–2.5 times normal. His was admitted to the intensive care unit for monitoring and to ensure hypotension and hypertension were promptly controlled. His anticoagulation con-

tinued for six months with warfarin. With physiotherapy, his deficit largely resolved in the ensuing six months.

Q3: What is the differential diagnosis of acute neurological deficit after trauma?

There are many ways for sorting out the various causes of acute neurological dysfunction after trauma. The acronym HEADACHE may help when timely diagnoses are needed (see box 1).

Box 1: HEADACHE

- Haematoma
- Elevated intracranial pressure
- Air or fat embolism
- Diffuse axonal injury
- Alcohol and drugs, metabolic causes (diabetes, thyroid, etc)
- Cord injury
- Hypoperfusion and hypoxia
- Epilepsy

In this case, the patient likely suffered an acute embolic event, causing hypoperfusion.

Discussion

When stroke occurs in a young adult, one must consider cervicocerebral (carotid and vertebral) artery dissection. The cause is usually traumatic: sports, instrumentation, penetrating injuries, cervical manipulation, etc. However, even minor activities such as brushing teeth, coughing, and intercourse have resulted in dissection.¹ Post-traumatic dissection involves a longitudinal intimal tear with intramural bleeding. A large clot obstructs the vascular lumen and can lead to thrombosis and distal embolism. Atherosclerosis and vascular pathology predispose to dissections.

The extracranial internal carotid artery is the most frequently reported site of cervicocerebral dissection.¹ The vessel is tethered as it enters the foramen lacerum and can be injured along its entire relatively unprotected course.² Carotid dissections sometimes result in cerebral ischaemia owing to haemodynamic compromise from stenosis, but more often to embolism of thrombotic fragments.³ Disruption of the endothelial surface exposes thrombogenic elements to the blood.

The diagnosis of cervical carotid dissection is based on clinical picture (head and neck pain, cerebral ischaemia, cranial nerve compression, and subarachnoid haemorrhage) and arteriographic findings.^{1,2} Normal brain computed tomography in an acutely hemiplegic person who has had recent cervicocerebral trauma (our patient had a concussion and left humeral fracture) should prompt the diagnosis of an arterial dissection.¹ Stroke occurs in 56% of cases of blunt internal and common carotid traumatic injury.⁴ The deficits, usually from an embolic event, occur after a lucid interval usually of several hours to a few days after the

Learning points

- Cervicocranial arterial dissections can result from even minor trauma; it is an uncommon cause of acute ischaemic stroke, except among young adults.
- Extracranial carotid dissection is the commonest type of cervicocranial dissection.
- Normal computed tomography of the brain in an acutely hemiplegic person after trauma should raise the possibility of cervicocranial arterial dissection.
- In the absence of haemorrhage, most carotid dissections with ischaemia can be treated with 3–6 months of anticoagulants; antiplatelet therapy is given in dissection with no ischaemia.
- Long term prognosis tends to be favourable in dissections without subarachnoid haemorrhage.

insult (~1 hour in our case).² Dissection usually begins >2 cm distal to the carotid bifurcation and extends rostrally, terminating before entry of the artery into the petrous bone (as was seen in this case), where mechanical support limits further dissection. Irregular narrowing of the artery is the most frequent arteriographic finding, resulting in a “wavy ribbon” appearance, or a “string sign” if severe.² A tapered occlusion beginning distal to the carotid sinus is less specific, but occurs in about 20% of cases.² Intimal flaps may be seen near the proximal margin of the dissection. An extraluminal pouch (dissecting aneurysm) may be visualised distally, usually near the base of the skull.²

The acute prognosis of patients who have arterial dissections not complicated by strokes is good.¹ The acute prognosis of ischaemic stroke is less favourable and reflects the extent of the infarction and is not specific to the arterial process.¹ Bogousslavsky *et al* wrote that of 30 patients with strokes secondary to dissections, seven died, and 12 made good recoveries.⁵ Patients with intracranial dissections have a poorer prognosis than those with extracranial lesions, in part because the dissections may be complicated by subarachnoid haemorrhage.¹ The danger of early and late recurrent stroke is not high for those without severe underlying atherosclerosis or vascular pathology. Overall, regression or resolution of the stenotic arterial lesion is the rule.

Since most cerebral injury probably results from thromboembolic complications of the dissection,³ patients with acute ischaemic events and without subarachnoid haemorrhage (as in extracranial carotid dissection) are given intravenous heparin, followed by oral anticoagulants. Therapy is continued until repeat vessel imaging at three months, and beyond if necessary, shows good resolution.² Long term

antiplatelet therapy may be needed for those with persistent lumen irregularities. Patients without ischaemic symptoms may be given antiplatelet therapy for 6–12 months from the outset. Surgical intervention may be contemplated in select cases.

Final diagnosis

Traumatic dissection of the extracranial internal carotid artery.

- 1 Adams Jr HP, Love BB, Jacoby MR. Arterial dissections. In: Ginsberg MD, Bogousslavsky J, ed. *Cerebrovascular disease: pathophysiology, diagnosis, and management*. Malden, MA: Blackwell Science 1998: 1430–46.
- 2 Saver JL, Easton JD. Dissections and trauma of cervico-cerebral arteries. In: Barnett HJM, Mohr JP, Stein BM, Yatsu FM, ed. *Stroke: pathophysiology, diagnosis, and management*. 3rd Ed. New York: Churchill Livingstone, 1998: 769–86.
- 3 Steinke W, Schwartz A, Hennerici M. topography of cerebral infarction associated with carotid artery dissection. *J Neurol* 1996;243:323–8.
- 4 Ramadan F, Rutledge R, Oller D, et al. Carotid artery trauma: a review of contemporary trauma center experiences. *J Vasc Surg* 1995;21:46–55.
- 5 Bogousslavsky J, Despland P-A, Regli F. Spontaneous carotid dissection with acute stroke. *Arch Neurol* 1987;44: 137–40.

A young man with acute paraparesis

Q1: Describe the changes in the electrocardiogram

The electrocardiogram shows small P waves, broad QRS complexes, and peaked T waves, all of which are consistent with hyperkalaemia. Other electrocardiographic features of hyperkalaemia include prolongation of the PR interval, complete heart block, and atrial asystole. Ventricular fibrillation and standstill may occur with severe hyperkalaemia.

Q2: How would you explain the neurological symptoms and signs?

The acute paraparesis is due to hyperkalaemic paralysis. The patient was treated with intravenous calcium gluconate, sodium bicarbonate, and dextrose and insulin infusion. He made a quick symptomatic recovery within one hour after starting treatment. Hyperkalaemic paralysis which may mimic the picture of acute Guillain-Barré syndrome has been previously described.¹ Hereditary hyperkalaemic paralysis is a separate clinical entity. Causes of secondary hyperkalaemic paralysis is shown in box 1.

Q3: What is the final diagnosis and how would you confirm it?

All the biochemical abnormalities are secondary to chronic autoimmune primary adrenal

Box 2: Causes of primary adrenal insufficiency

Gradual onset

- Autoimmune adrenalitis.
- Tuberculosis.
- Adrenomyeloneuropathy.
- Systemic fungal infections (for example, histoplasmosis).
- AIDS (opportunistic infections with viruses, fungi, bacteria, or protozoa).
- Metastatic carcinoma (bronchial, breast, lymphoma).
- Adrenal infiltration (amyloidosis, sarcoidosis, haemochromatosis).
- Drugs (ketoconazole, aminoglutethimide, suramin, mitotane, metyrapone).

Acute onset

- Meningococcal and other septicaemias.
- Warfarin therapy.
- Coagulation disorders.
- Antiphospholipid syndrome.
- Abdominal trauma.

insufficiency (Addison's disease). The short Synacthen (tetracosactrin) stimulation test, is the most commonly used test for the diagnosis of primary adrenal insufficiency. Adrenal function is considered to be normal if the basal or postcorticotrophin (Synacthen) plasma cortisol is at least 500 nmol/l or preferably, at least 550 nmol/l.² Basal plasma adrenocorticotrophic hormone concentration is usually raised in primary adrenal insufficiency. This patient showed a flat cortisol response after administration of Synacthen (cortisol concentration 107, 105, and 122 nmol/l at 0, 30, and 60 mins respectively). His antiadrenal cortex antibodies were strongly positive. He was treated with intravenous fluids, hydrocortisone, and fludrocortisone. He was well, and his electrolytes and renal function were normal when seen as an outpatient two weeks later. Causes of primary adrenal insufficiency are shown on box 2.³

Discussion

The symptoms and signs of chronic primary adrenal insufficiency are non-specific and may vary depending on the chronicity and severity of the adrenal destructive process, and the relative deficiency of glucocorticoids and mineralocorticoids. Patients can present with fatigue, weakness, listlessness, orthostatic hypotension, and weight loss. Gastrointestinal symptoms such as abdominal cramps, nausea, anorexia, vomiting, and diarrhoea are often the presenting features. Hyperpigmentation which affects the skin and mucosal surfaces is the most specific sign of chronic primary adrenal insufficiency, but its absence does not exclude this diagnosis. Addison's disease may

Box 1: Causes of hyperkalaemic paralysis

- Renal failure.
- Adrenal insufficiency.
- Rhabdomyolysis.
- Administration of potassium salts in intravenous infusions.
- Aldosterone antagonist (spironolactone).

be misdiagnosed as anorexia nervosa⁴ or depression.⁵

Acute adrenal insufficiency is a life threatening medical emergency which needs immediate medical action. Once the diagnosis is suspected, treatment should be instituted and not delayed for investigations. Plasma samples can be saved for later analysis of the cortisol concentration to confirm the diagnosis. Hypotension, nausea, vomiting, and diarrhoea are prominent features.

In the early stages of chronic adrenal failure, the serum electrolytes are normal, but abnormalities such as hyponatraemia, hyperkalaemia, metabolic acidosis, and renal impairment occur in the later stages of the disease when adrenal destruction is advanced. The hyponatraemia is due to aldosterone deficiency and vasopressin secretion secondary to hypovolaemia. Hyperkalaemia is due to a combination of aldosterone deficiency, acidosis, and renal impairment.

Our patient presented with the acute neuromuscular manifestations of hyperkalaemia (hyperkalaemic paralysis) in the absence of the classical symptoms of chronic adrenal failure, which is a very unusual presentation of Addison's disease.

The predominance of hyperkalaemia in this patient could be partly explained by the absence of vomiting and diarrhoea, which tend to lower the serum potassium level. In addition the severity of metabolic acidosis in the presence of renal impairment is an other contributing factor.

The management of primary adrenal insufficiency consists of glucocorticoid and mineralocorticoid replacement, usually in the form of hydrocortisone and fludrocortisone respectively. Patients should carry a card containing information on current therapy, and they should also wear a bracelet or necklace, such as those issued by Medic Alert.⁶

Patients must also be advised to double up the dose of hydrocortisone for a few days if they develop a febrile illness, and they should keep ampoules of hydrocortisone in the fridge at home for intramuscular injection, or hydrocortisone suppositories to be used in case of vomiting.⁷

This case emphasises the importance of excluding metabolic abnormalities in patients presenting with acute neurological symptoms as the response to treatment is usually prompt, and the outcome rewarding.

Final diagnosis

Hyperkalaemic paralysis secondary to chronic autoimmune primary adrenal insufficiency (Addison's disease).

5 Keljo DJ, Squires RH. Just in time. *N Engl J Med* 1996;334:46–8.

6 Werbel SS, Ober KP. Acute adrenal insufficiency. *Endocrinol Metab Clin North Am* 1993;22:303–28.

7 Newrick PG, Braatvedt G, Hancock J, et al. Self-management of adrenal insufficiency by rectal hydrocortisone. *Lancet* 1990;335:212–3.

Pain in the right wrist

Q1: Describe the radiographic features in figs 1, 2, and 3 (see p 433)

The radiographs of the right wrist show progressive sclerosis and fragmentation of the lunate bone.

Q2: What is the clinical diagnosis? What investigation would have helped clinch the diagnosis at the first presentation

The radiographic progression is classical of idiopathic avascular necrosis of the lunate: Kienböck's disease. A bone scan or magnetic resonance imaging at the first presentation would have been valuable in clinching the diagnosis.

Q3: What would be your line of management for this patient? Rationalise your answer

As collapse of the lunate has occurred, surgical procedures are ineffective in realigning the ulna. Management at this stage usually involves replacement of the lunate with a titanium implant¹ or arthrodesis of the wrist.

Discussion

Kienböck's disease occurs typically in young adults. Recognised predisposing factors include local trauma and a relatively shortened ulna (negative ulnar variance). The latter predisposes the lunate compression to against the distal radius.² The patient classically complains of pain and weakness of the affected wrist. Examination usually reveals a localised area of tenderness corresponding to the lunate and a significant reduction in grip strength. In later stages of the disease, wrist movements are markedly reduced. Based on the clinical and radiographic features four stages of the disease have been identified (see table 1).

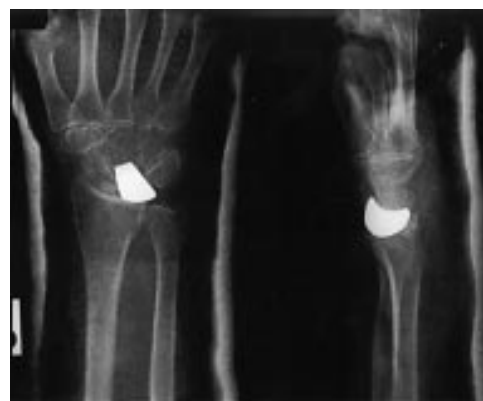

Figure 1 Radiograph showing titanium implant.

1 Naumann M, Reiners K, Schalke B, et al. Hyperkalaemia mimicking acute Guillain-Barré syndrome. *J Neurol Neurosurg Psychiatry* 1994;57:1436–7.

2 May ME, Vaughn ED, Carey RM. Adrenocortical insufficiency—clinical aspects. In: Vaughn ED Jr, Carey RM, eds. *Adrenal disorders*. New York: Thieme Medical, 1989: 171–89.

3 Oelkers W. Adrenal insufficiency. *N Engl J Med* 1996;335:1206–12.

4 Tobin MV, Morris AI. Addison's disease presenting as anorexia nervosa in a young man. *Postgrad Med J* 1988;64:953–5.

Table 1 Four stages of Kienböck's disease

Stage	Features	Management
Stage 1	Ischaemia without radiographic changes (fig 1, see questions)	Rest, splintage, and analgesia
Stage 2	Sclerosis of lunate (fig 2, see questions)	Shortening of radius or lengthening of ulna ³
Stage 3	Collapse of lunate (fig 3, see questions)	Titanium implant (see fig 1, p 445) or radiocarpal fusion
Stage 4	Osteoarthritis of radiocarpal joint	Wrist arthrodesis

Final diagnosis

Advanced Kienböck's disease of the right lunate.

- 1 Swanson DH, Pierce TD. Carpal bone titanium implant arthroplasty. *Clin Orthop* 1997;342:46–58.
- 2 Gelberman RH, Salamon PB, Jurst JM, *et al.* Ulnar variance in Kienböck's disease. *J Bone Joint Surg Am* 1975;57:674–6.
- 3 Weiss APC, Welland AJ, Moore JR, *et al.* Radial shortening for Kienböck's disease. *J Bone Joint Surg Am* 1991;73:384–91.

Atypical cellulitis

Q1: What are the computed tomography findings in figs 1 and 2? (see p 434)

Figure 1 is a section through the perineum and upper thigh showing a right vaginal hydrocoele with normal testis.

Figure 2 is a section through the lumbar area showing retroperitoneal gas, fluid, and necrotic tissue displacing the right kidney anteriorly but both kidneys look normal.

Q2: What is the most likely diagnosis?

Right sided retroperitoneal abscess/necrotising infection, which is extending into right groin with secondary hydrocoele.

Q3: What should be the next step of management?

The patient should be rehydrated and should receive intravenous high dose combination antibiotics to start with and then should be taken to theatre for radical surgical debridement and drainage of pus/necrotic tissue. Finally further investigations are required to identify the source of infection.

Discussion

We treated this patient initially with high dose broad spectrum antibiotics and intravenous fluid therapy with a provisional diagnosis of pyonephrosis and right epididymo-orchitis. The plain x ray film of the abdomen was unremarkable and there was no evidence of any renal stones. The next morning computed tomography (with intravenous contrast but no oral contrast) revealed retroperitoneal necrotising infection but without any definite source. The patient was taken to theatre and underwent a right orchidectomy along with debridement of retroperitoneal necrotic tissue extraperitoneally via a separate lumbar incision. During operation we found more necrotic tissue and milky fluid rather than frank pus. Urgent Gram stain showed the presence of Gram positive cocci and bacilli. He was started on high dose benzylpenicillin, metronidazole, and flucloxacillin along with parenteral feeding. Subsequent intravenous urography was normal but a barium enema (fig 1, right) revealed a polypoidal growth in

the caecum. Laparotomy and right hemicolectomy was performed for a locally invasive adenocarcinoma of caecum with small intra-peritoneal tumour deposits. Eventually he was discharged home after two months of hospital stay.

In summary, this man had retroperitoneal necrotising fasciitis (RNF) due to locally perforated carcinoma of the caecum. RNF is a rare variety of synergistic soft tissue infection of retroperitoneum. Bowel perforation (carcinoma, perforated diverticular disease, or undiagnosed strangulated hernia) and urinary extravasation are commonly found as predisposing pathology. RNF is very difficult to diagnose in its early stage. A Medline search has revealed only three published articles on RNF.^{1–3} Almost all of the patients presented with abdominal wall, groin, and/or inner thigh cellulitis with or without cutaneous gangrene. All of their patients were very ill systemically with severe pain being a key diagnostic symptom. Computed tomography has been found to be a very useful diagnostic tool and if any bowel lesion is not evident on computed tomography, patients should have a barium enema or colonoscopy. When in doubt, aspiration of tissue fluid and urgent Gram stain can be very useful. Frozen section biopsy of the necrotic area has been found to be of good value for early diagnosis.⁴ Bacteriology usually reveals mixed growth of aerobic and anaerobic organisms, of which commonly found organisms are

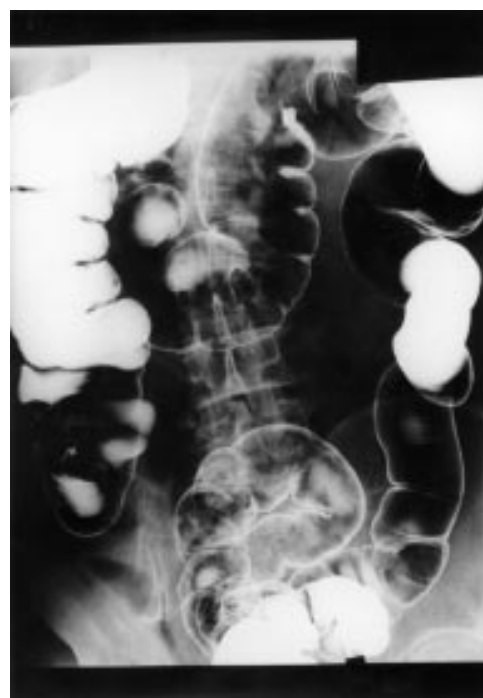

Figure 1 Barium enema showing polypoidal growth in the caecum.

Learning points

- Retroperitoneal necrotising fasciitis (RNF) is a rare but fatal condition.
- Any atypical cellulitis of the abdominal wall, groin, and inner thigh should be treated suspiciously.
- If in doubt computed tomography is a very good tool to diagnose RNF.
- Early and radical surgical debridement is essential with a view to redebridement.
- If RNF is diagnosed, a bowel lesion should be sought for.

Streptococcus faecalis, *S. milleri*, coliforms, and bacteroides spp. Prompt and radical surgical debridement of retroperitoneal tissue is the key treatment and quite often repeat debridement is required.² High dose combination antibiotics are life saving. Hyperbaric oxygen has been found to reduce the mortality and need for repeat debridement,^{5,6} but its role is still controversial.

Mortality is very high (range 37%–80%) depending on the extent of infection. The great majority of patients, who had laparotomy to deal with bowel pathology and retroperitoneal necrosis at the same time, died in the early postoperative period because of septicaemia and subsequent multiorgan failure.¹ Our patient went home and is still alive and well six months after surgery. We believe this is because in first stage we debrided retroperitoneal tissue extraperitoneally and subsequently we dealt with the primary pathology intraperitoneally.

Final diagnosis

Retroperitoneal necrotising fasciitis due to locally perforated carcinoma of the caecum.

- 1 Woodburn KR, Ramsay G, Gillespie G, *et al.* Retroperitoneal necrotising fasciitis. *Br J Surg* 1992;79:342–4.
- 2 Mokoena T, Luvuno FM, Marivate M, *et al.* Surgical management of retroperitoneal necrotising fasciitis by planned repeat laparotomy and debridement. *S Afr J Surg* 1993;31:65–70.
- 3 Ward RG, Walsh MS. Necrotizing fasciitis: 10 years' experience in a district general hospital. *Br J Surg* 1991;78:488–9.
- 4 Stamenkovic I, Daniel Lew P. Early recognition of potentially fatal necrotizing fasciitis, the use of frozen-section biopsy. *N Engl J Med* 1984;310:1689–93.
- 5 Riseman JA, Zamboni WA, Curtis A, *et al.* Hyperbaric oxygen therapy for necrotizing fasciitis reduces mortality and the need for debridements. *Surgery* 1990;108:847–50.
- 6 Anonymous. Hyperbaric oxygen, more indications than many doctors realise (editorial). *BMJ* 1993;307:515–16.

An interesting electrolyte problem**Q1: What additional history would help in making a diagnosis?**

History of ingestion of antacids. The patient gave a history of using at least half to one bottle of antacids and several tablets of "Tums" (calcium carbonate) a day for heartburn and indigestion.

Q2: What is the most likely explanation for the electrolyte disturbance?

The triad of hypercalcaemia, alkalosis, and renal failure suggests a diagnosis of milk alkali syndrome with excessive ingestion of milk of magnesia. The alkalosis was aggravated by vomiting and nasogastric suction leading to volume contraction.

Hospital course

An abdominal film was obtained and intestinal obstruction was excluded. The patient was treated with normal saline and other supportive measures. His electrolytes and renal function normalised within the next 24 hours (table 1).

Discussion

The patient described above presented with a severe metabolic alkalosis (bicarbonate of 65 mmol/l) and hypermagnesaemia. The pathogenesis of metabolic alkalosis in this case is complex and multifactorial. The triad of hypercalcaemia, alkalosis, and renal failure suggests a diagnosis of milk alkali syndrome. However, this syndrome is generally associated with hypokalaemia and hypomagnesaemia. In the patient presented here, excessive ingestion of milk of magnesia ($Mg(OH)_2$) in the presence of renal failure led to reduced excretion of magnesium thus causing hypermagnesaemia. The alkalosis was further aggravated by vomiting, nasogastric aspiration, and volume contraction. Dehydration led to further deterioration in renal function.

Alkalosis of this severity has only been reported sporadically.^{1,2} Voyce *et al* reported a case of severe alkalaemia with a pH of 7.81, as a result of combined metabolic and respiratory alkalosis.³ A serum bicarbonate concentration of 96 mmol/l has been reported in a patient due to excessive ingestion of sodium bicarbonate.² Severe alkalaemia may be fatal and a mortality as high as 41% has been reported with severe metabolic alkalosis.⁴

Metabolic alkalosis is categorised as saline responsive if the urine chloride concentration is less than 15 mmol/l or saline resistant if the urine chloride is greater than 25 mmol/l. Volume depletion, either from gastrointestinal losses, diuretics, or renal compensation for hypercapnia are among the most common causes of chloride responsive metabolic alkalosis. Chloride resistant metabolic alkalosis results from mineralocorticoid excess or potassium depletion. Evaluation of patients with metabolic alkalosis includes assessment of extracellular fluid volume, and urinary electrolytes which helps to determine if the alkalosis is chloride responsive. Fluid repletion is the mainstay of treatment of chloride responsive metabolic alkalosis. In cases of very severe alkalosis infusion of dilute hydrochloric acid (0.01N) may be required. The management of chloride resistant alkalosis requires treatment of the underlying cause.⁵

Hypermagnesaemia occurs rarely, and is usually iatrogenic.⁶ Elderly patients with renal failure are at increased risk of developing hypermagnesaemia. Clinical manifestations of hypermagnesaemia include vomiting, altered

mental status, and respiratory depression. Discontinuation of magnesium is sufficient to correct the problem in most cases, however, haemodialysis may be required to treat severe cases.⁶

This case describes a complex and potentially fatal electrolyte and acid-base disorder, resulting from available and commonly used non-prescription medication. History remains an invaluable guide to the diagnosis of such complex problems. Elderly patients should be particularly warned against abuse of laxatives and antacids.

Final diagnosis

Metabolic acidosis secondary to milk alkali syndrome and nasogastric aspiration with milk of magnesia overdose.

This work was supported by NIH Grant HL-07123.

- 1 Amundson DE, Diamant J. Severe metabolic alkalosis. *South Med J* 1994;87:275-7.
- 2 Rama B, Varghese J, Genova G, et al. Severe acute metabolic alkalosis. *Nebr Med J* 1993;78:151-4.
- 3 Voyce SJ, Goldfine HL, Gore JM. Severe metabolic and respiratory alkalosis associated with the treatment of congestive heart failure. *Arch Intern Med* 1987;147:2211-12.
- 4 Brimiouille S, Katn RJ. Effects of metabolic alkalosis on pulmonary gas exchange. *Am Rev Respir Dis* 1990;141:1185-9.
- 5 Gluck SL. Acid-base (review). *Lancet* 1998;352:474-9.
- 6 Weisinger JR, Bellorin-Font E. Magnesium and phosphorus. *Lancet* 1998;352:391-6.

Respiratory compromise relieved by laparotomy

Q1: What does the chest radiograph show and what would be your next investigation?

The chest radiograph (see p 436) shows an abnormal cardiac shadow, which gives the appearance of a dextrocardia. Closer examination, shows a mass on the right side, which represents the right atrium being compressed forward by a posterior lesion. There is also a double left cardiac border, the medial border being the true one. The lateral border represents a posterior mediastinal cyst. Bilateral pleural effusions are also noted, more marked on the right, and so the differential diagnosis should also cover other causes of bilateral pleural effusions. These include hypoproteinaemia secondary to nephrotic syndrome or chronic liver disease and in addition, given that there are absent breast shadows, in a women of this age a possible diagnosis of metastatic breast carcinoma with previous mastectomies should also be considered. As a next investigation, contrast enhanced computed tomography of the abdomen would offer useful diagnostic information see figs 1 and 2 (below).

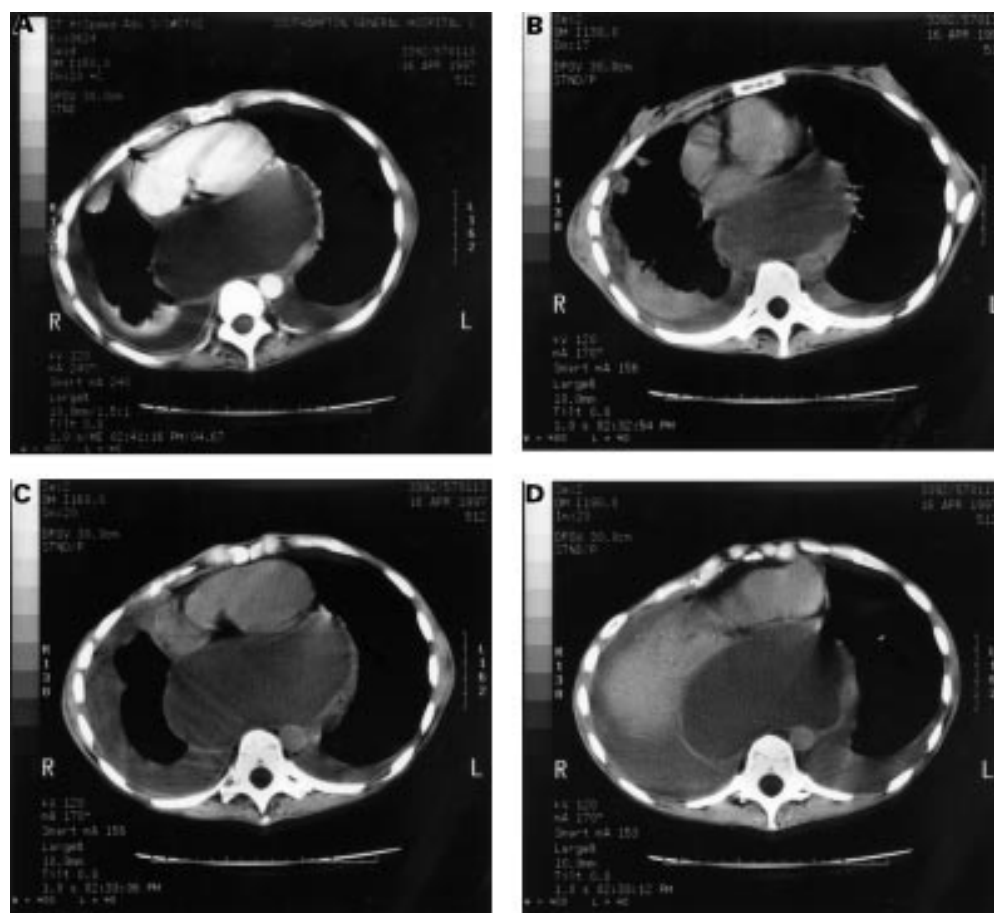


Figure 1 Contrast enhanced computed tomography of the thorax demonstrating a large fluid containing mass in the posterior mediastinum compressing the heart and deviating it to the right. The scan also identifies bilateral pleural effusions and basal consolidation in the right lower lobe.

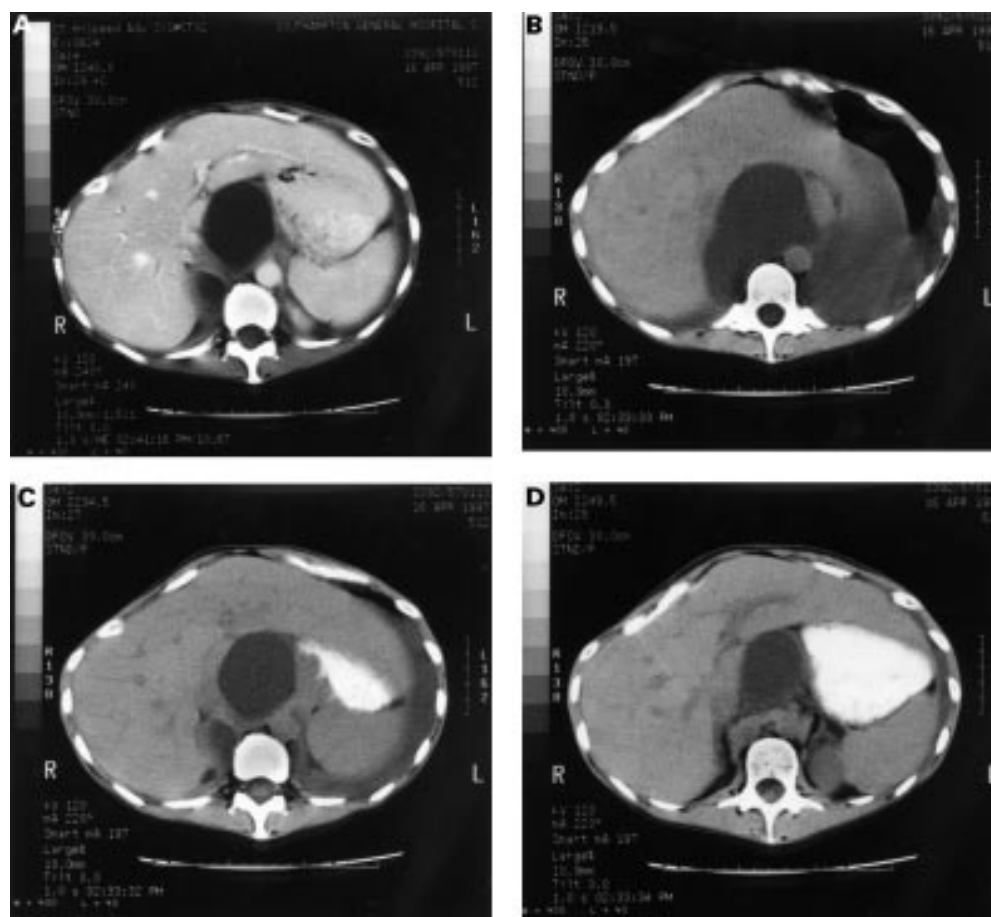


Figure 2 Contrast enhanced abdominal computed tomography demonstrating a large retroperitoneal fluid collection which was seen to be continuous with the intrathoracic collection on the complete series of the images obtained.

Q2: What is the diagnosis and how would you manage this patient?

The diagnosis is mediastinal pancreatic pseudocyst.

The images in figs 1 and 2 (above) show a large pancreatic pseudocyst communicating with the posterior mediastinum via an extension through the oesophageal hiatus of the diaphragm.

The patient was then referred to a pancreatic surgeon and the diagnosis was confirmed at laparotomy. The mediastinal cyst was drained by a tube passing through the diaphragm, across the abdominal cavity to the exterior, and the abdominal pseudocyst was drained by cyst gastrostomy.

Discussion of further management

Mediastinal pseudocyst is a rare complication of pancreatitis, with fewer than 60 cases reported in the English language.¹ The pseudocyst is inflammatory in origin and the lesion lacks a true epithelial lining. As a consequence, extrapancreatic fluid collections, rich in proteolytic enzymes, fat, and necrotic debris accumulate outside the boundary of the gland surrounded by a thick fibrous capsule. While spontaneous resolution of pseudocysts has been reported,² this is unlikely if there is evidence of chronic pancreatitis, pancreatic duct abnormalities exist, or if ultrasound imaging suggests a thick walled lesion.³

The pathogenesis and natural history of pseudocysts in acute and chronic pancreatitis are different.⁴ Both lesions may lead to extension of the pseudocyst along fascial planes which offer least resistance and may result in mediastinal pseudocyst formation. Entry to the thorax is most commonly seen via the oesophageal hiatus, aortic hiatus, or by direct erosion through the diaphragm.⁵

The review of mediastinal pseudocyst case reports by Beauchamp *et al* suggests that they are more commonly seen in men, have a median age of distribution of 45 years and most commonly present with dyspnoea, chest and abdominal pain, and weight loss. Dysphagia may be present if there is oesophageal displacement by the extending pseudocyst. Recurrent hospital admissions for alcohol associated pancreatitis was a feature in most reported cases.

Radiography findings and the role of radiography

Radiographically non-specific findings of pleural effusion, pulmonary oedema, atelectasis, and cardiac enlargement may be accompanied by more specific findings of mediastinal inflammation or abscess and mediastinal pseudocyst.⁶⁻⁸ Kirchner identified that when present, pleural effusions were most commonly left sided and the location of the thoracic mass was in the posterior mediastinum. Magnetic resonance imaging and endoscopic retrograde

cholangiopancreatography have proved useful in diagnosis and planning treatment strategies.

Surgical options

External drainage of the mediastinal pseudocyst represents the simplest surgical approach but is associated with the highest mortality and greatest recurrence rate.⁹⁻¹⁰ Erb and Grimes highlight a greater recurrence of mediastinal pseudocyst with external drainage when compared with intra-abdominal drainage. Thus, while the thoracic symptoms often give the greatest concern, mediastinal pseudocysts are best managed by laparotomy rather than thoracotomy. Thoracic drainage may be useful preoperatively if the cyst is infected. The formation of a controlled fistula into the gastrointestinal tract by cyst intestinal anastomosis, represents the treatment of choice for non-complicated mature pseudocysts and is associated with lowest mortality and recurrence rates. Internal decompression of the pseudocyst may be either with cyst gastrostomy or more commonly with cystojejunostomy Roux on Y.

Conclusion

This case highlights a rare complication of pancreatic disease, manifesting with symptoms outside the gastrointestinal tract. Mediastinal pseudocyst should be considered in the differential diagnosis when a patient with previous pancreatic disease presents with shortness of breath and unexplained thoracic radiographic findings. Radiological techniques offer invaluable diagnostic information and may have a role in treatment. Currently, surgical intervention with internal abdominal drainage of the lesion close to the pancreas, and external transdiaphragmatic drainage of the intrathoracic component offers the best therapeutic outcome.

Final diagnosis

Mediastinal pancreatic pseudocyst.

The authors thank Dr Simon Jackson, Consultant Radiologist, at Derriford Hospital, Plymouth.

- 1 Edwards RD, Jardine A, Vallance R. Pancreatic pseudocyst—an unusual cause of palpitations. *Clin Radiol* 1992;45:128–40.
- 2 Leechawengwong M, Berger HW, Romeu J. Spontaneous resolution of mediastinal pancreatic pseudocyst. *Chest* 1979;75:632–3.
- 3 Warshaw AL, Rattner DW. Timing of surgical drainage for pancreatic pseudocyst. *Ann Surg* 1985;202:720–4.
- 4 Grace PA, Williamson RCN. Modern management of pancreatic pseudocysts. *Br J Surg* 1993;80:573–80.
- 5 Beauchamp RD, Winsett M, Nealon WH. Operative strategies in the management of mediastinal pancreatic pseudocyst. *Surgery* 1989;105:567–70.
- 6 Fishbein R, Murphy GP, Wilder RJ. The pleuropulmonary manifestations of pancreatitis. *Diseases of the Chest* 1962;41:392–7.
- 7 Kaye MD. Pleuropulmonary complications of pancreatitis. *Thorax* 1969;23:297–306.
- 8 Roseman DM, Kowlessar OD, Slesinger MH. Pulmonary manifestations of pancreatitis. *N Engl J Med* 1960;263:294–6.
- 9 Bradley EL. Cysts and pseudocysts of the pancreas. Surgical aspects. In: Berk JE, ed. *Gastroenterology*. Vol 6. London: W B Saunders, 1985: 4151–7.
- 10 Erb WH, Grimes EL. Pseudocysts of the pancreas: a report of 17 cases. *Am J Surg* 1960;100:30.

Chronic non-healing ulcers of the scalp after trauma

Q1: What is the differential diagnosis of this clinical presentation and radiological picture?

A chronic infection of skull and scalp was diagnosed and pyogenic, tuberculous, and fungal osteomyelitis were considered in the differential diagnosis.

Q2: How should this patient be managed?

Chronic non-healing scalp infection needs thorough debridement of the wound and excision of osteomyelitic bone till healthy bone margins are reached. Appropriate antibiotic treatment, based on microbiological tests, is usually needed for weeks to months.

Our patient underwent drainage of the subcutaneous pus and debridement of the wound. The bone was not excised as a very extensive area of bone seemed to be involved on the x ray films, and the outer table looked intact at surgery. Multiple pockets of pus and granulation tissue were seen in the subcutaneous plane. Pus smear showed Gram positive, branching filaments. There was a heavy growth of aerobic actinomycetae on Lowenstein-Jensen medium, and on Sabouraud dextrose agar, suggestive of nocardia, which was sensitive to co-trimoxazole and penicillin. There was no growth of mycobacteria or other pathogens. The histopathological examination revealed dense infiltrate of vascular granulation tissue and exudate (with no granulomata, or caseation), suggestive of chronic non-specific inflammation.

Q3: What is the optimal treatment of this condition?

The natural history of primary cutaneous nocardial disease is not known. As cure with surgical debridement alone occurs in only one third of cases, drug therapy is recommended in all patients.¹ The optimal antibiotic therapy for nocardiosis has not been established. Trimethoprim-sulfamethoxazole acts synergistically against most strains of nocardia (in vitro),² and so also minocycline, amikacin, and imipenem.³ Our patient was thus treated with sulphonamides and amikacin along with surgical debridement. The duration of therapy for nocardiosis varies from three months to one year with the type and extent of the disease.¹ Considering the chronicity of the disease and extensive bony involvement in our patient, a prolonged course of therapy (co-trimoxazole for one year) was advised.

Discussion

Nocardia are soil saprophytes that usually cause respiratory infection in immunocompromised hosts, and extrapulmonary lesions may follow metastatic spread from the pulmonary focus. However solitary, extrapulmonary, lesions, involving skin and subcutaneous tissue, occur in significant number of immunocompetent patients after direct inoculation. In

Learning points

- Primary cutaneous nocardiosis can occur in an immunocompetent host.
- In a case of chronic infection of bone and subcutaneous tissue, with multiple sinuses, nocardiosis should be considered in the differential diagnosis.
- Chronic nocardial skin infection can manifest, after a long period of incubation, after primary inoculation.

primary cutaneous nocardiosis a history of local trauma, with soil contamination, is frequently present and commonly occurs in the extremities in adults (for example gardening accident victims).¹

Two forms of nocardial skin infection have been described⁴—the acute lymphangitic form and chronic actinomycetoma—with formation of nocardia grains (aggregates of filaments). The main sign of infection is the development of firm subcutaneous swelling, but later draining sinus tracts form, which discharge serosanguineous material and grains of nocardia onto the skin surface; bone involvement occurs by extension.⁴ The characteristic histopathological response to nocardial infection is the production of chronic inflammatory exudate without extensive fibrosis, caseation, or granuloma.

In reported cases of primary cutaneous nocardiosis after inoculation, there is seldom any evidence of impaired immune response of the host⁵; and local inflammation and lymphadenopathy usually follows. Initial failure of these mechanisms to eliminate all organisms, and confinement to a local site, may subsequently lead to the development of actinomycetoma.⁴ The factors affecting this change from acute to chronic phase are unclear; but it is proposed that the host's immune response as well as the ability of the organism to lose their cell wall structure,⁵ may affect this transformation. In our case, the long incubation period after inoculation, and subsequent chronicity of the disease, may be due to the transiently altered immune status.

In conclusion, when a patient presents with chronic, non-healing sinuses of the scalp, nocardiosis must be considered in the differential diagnosis, especially if there has been a history of trauma even in the remote past and specific cultures should be asked for.

Final diagnosis

Actinomycetoma form of primary cutaneous nocardiosis of scalp with involvement of skull bones.

1 Wallace RJ Jr. Infections caused by actinomycetes: nocardiosis. In: Kelley WN, ed. *Textbook of internal medicine*. Vol. 2. Philadelphia: JB Lippincott, 1989: 1598–600.

2 Smego RA Jr, Moeller MB, Gallis HA. Trimethoprim-sulfamethoxazole therapy for nocardia infections. *Arch Intern Med* 1983;143:711–18.

3 Goldstein FW, Hartefort B, Acar JF. Amikacin containing regimens for treatment of nocardiosis in immunocompromized patients. *J Clin Microbiol* 1987;6:198–200.

4 Hay RJ. Nocardial infection of the skin. *Journal of Hygiene* 1983;91:385–91.

5 Beaman BL, Scates SM. Role of L forms of *Nocardia caviae* in the development of chronic mycetomas in normal and immunodeficient murine models. *Infect Immun* 1981;33: 893–907.

An unusual complication of carcinoma of the caecum

Q1: What abnormality is seen on the computed tomogram in fig 1 (see p 438)?

The scan shows the characteristic appearance of widespread gas formation in the soft tissues of the thigh and pelvis.

Q2: What is the lethal abnormality present on the computed tomogram in fig 2 (see p 438)?

The striking appearance of gas is seen within the great vessels and the apex of the right ventricle.

Q3: What is the underlying diagnosis and what are the treatment options for this condition?

Postmortem examination confirmed the diagnosis of necrotising myositis with a Duke's C carcinoma of the caecum. Culture of tissue from the gluteal region grew *Clostridium septicum*. The main treatment is by early and widespread surgical excision of all affected tissue. Other treatment options are described below.

Background

Gas gangrene is a rapidly developing, spreading infection of muscle by toxin producing clostridial species, which are anaerobic Gram positive spore forming bacilli found in soil and the gastrointestinal tract of humans and animals.¹ Most cases are caused by *C perfringens* type A. Infection in man is usually secondary to trauma. Rarely a non-traumatic primary myonecrosis can occur. This is commonly due to infection with the relatively aerotolerant *C septicum* that allows infection of healthy tissue. Intestinal tract abnormalities are the major predisposing conditions. Colonic neoplasm is the most common of these and seen in up to 88% of patients with *C septicum* bacteraemia.² Approximately one third of cases of spontaneous clostridial gangrene are caused by *C septicum* (59 cases reported in the literature between 1969 to 1977). The organism produces several toxins but the α -toxin is particularly important causing haemolysis and tissue necrosis. Sudden onset of severe pain at the site of infection is often associated with a marked tachycardia out of proportion to any pyrexia. Prognosis is improved by prompt recognition of the condition. The diagnosis may be confirmed by Gram stain of wound discharge or needle biopsy and radiology for early detection of intramuscular gas. Medical treatment is supportive to combat dehydration, shock, and acute tubular necrosis. In vitro data suggest that *C septicum* is susceptible to a wide range of antibiotics and penicillin,

clindamycin, or metronidazole should all be effective.³ Hyperbaric oxygen has a bacteriocidal effect on most clostridial species and can inhibit further toxin production. In vitro, *C septicum* is more resistant to the lethal effects of hyperoxia in cell free systems.⁴ The use of antitoxin antibodies raised against the α -toxin remains controversial. Early surgical excision of all affected muscle is the essential life saving management. The overall mortality for gas gangrene is between 11% and 31% but between 67% and 100% for *C septicum* infection.

The radiological imaging performed immediately before the cardiovascular collapse graphically illustrates the widespread gas formation both at the site of initial infection and beyond. It is striking that the patient was able

to maintain her cardiac output in the face of the appearance on computed tomography. The subsequent electromechanical dissociation was in retrospect a predictable and irrevocable event.

Final diagnosis

Gas gangrene caused by *C septicum* infection.

- 1 Maclellan JD. The histotoxic clostridial infections of man. *Bacteriological Reviews* 1962;26:177–276.
- 2 Stevens DL, Musher DM, Watson DA, *et al.* Spontaneous, nontraumatic gangrene due to *Clostridium septicum*. *Rev Infect Dis* 1990;12:286–96.
- 3 Brazier JS, Levett PN, Stannard AJ, *et al.* Antibiotic susceptibility of clinical isolates of clostridia. *J Antimicrob Chemother* 1985;15:181–5.
- 4 Hill GB, Osterhout S. Experimental effects of hyperbaric oxygen on selected clostridial species. I. In-vitro studies. *J Infect Dis* 1972;125:17–25.