

SELF ASSESSMENT QUESTIONS

Progressive breathlessness in an 18 year old male

M G Kelly, L G Heaney

Answers on p 311.

A fit 18 year old rugby player presented with a four month history of progressive exertional breathlessness, preceded by an unremarkable flu-like illness. There was no response to inhaled β_2 -agonist, oral theophylline, or inhaled corticosteroids. At assessment, he was breathless on minimal exertion with wheeze. He had never smoked cigarettes. There was no family history of chest disease. He had worked with fibreglass and hardener for one month and had an inhalation anaesthetic for a tonsillectomy, 18 months previously. On examination, his chest was hyperinflated with decreased expansion, hyper-resonant percussion note, reduced breath sounds, and diffuse polyphonic expiratory rhonchi.

Forced expiratory volume in one second was 1.3 litres (30% of predicted), forced vital capacity 4.2 litres (79%), with a ratio of 31%. Residual volume was 3.64 litres (290%) and total lung capacity 8.65 litres (131%). Single

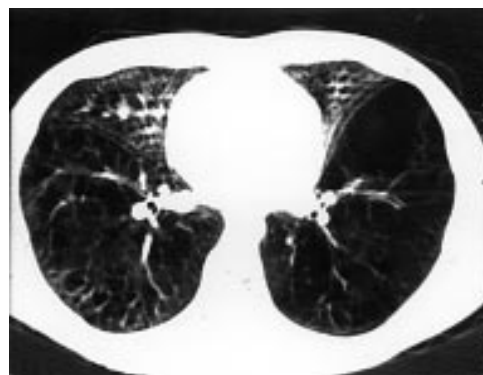


Figure 2 High resolution computed tomogram of thorax.

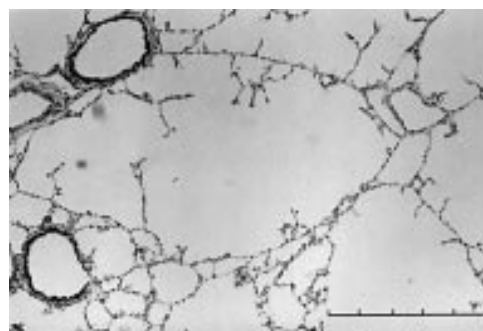


Figure 3 Histology slide from open lung biopsy (scale 1 cm = 50 μ m).

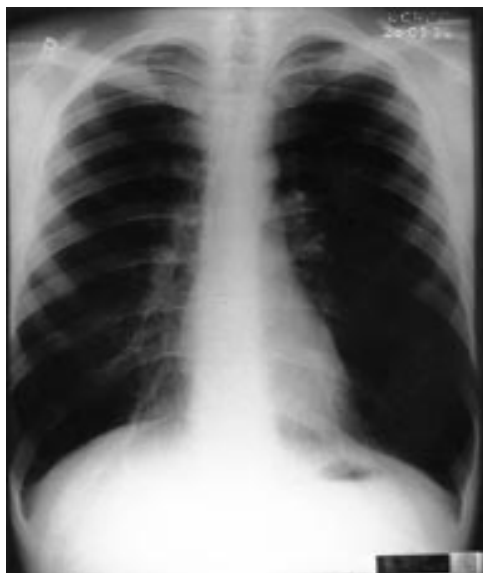

Figure 1 Posteroanterior chest radiograph.

breath carbon monoxide transfer factor was 3.38 mmol/min/kPa (29%). Chest radiography (fig 1), high resolution computed tomography of the thorax at the level of the pulmonary trunk (fig 2), and open lung biopsy (fig 3) are shown.

Questions

- (1) What are the clinical and pathological diagnoses?
- (2) What aetiologies should be considered?
- (3) What treatment options are available?

**Department of
Respiratory Medicine,
Level 11, Belfast City
Hospital, Lisburn
Road, Belfast
BT9 7AB, UK**
M G Kelly
L G Heaney

Correspondence to:
Dr Kelly (e-mail:
m.g.kelly@qub.ac.uk)

Submitted 19 March 1999
Accepted 13 August 1999

Sleeping eyes

O Vancollie, E Delgrange, J Donckier

Answers on p 312.

A 73 year old woman was admitted to hospital for weight loss, dysphagia with solids, and dyspnoea. She had suffered from Raynaud's phenomenon for 10 years. The main relevant findings are shown in the figures (figs 1–4). Erythrocyte sedimentation rate was normal and C reactive protein was 33 mg/l (normal <5 mg/l). White cell count was normal. Laboratory studies also revealed plasma lactate dehydrogenase of 1362 IU/l (normal 220–480 IU/l) and creatine phosphokinase of 1323 IU/l (normal 15–190 IU/l) consistent with myositis. Myoglobin was 1512 µg/l (normal <70 µg/l). Renal function was normal. Antinuclear antibodies were raised up to 1/2560 with a nucleolar staining pattern and extractable nuclear antigens were negative. Rheumatoid factor was

negative. Plain chest radiography and lung function tests were normal. Doppler echocardiography demonstrated normal left ventricular function but severe pulmonary hypertension (pulmonary arterial systolic pressure was 56 mm Hg). Capillaroscopy showed dilated nailfold capillary loops.

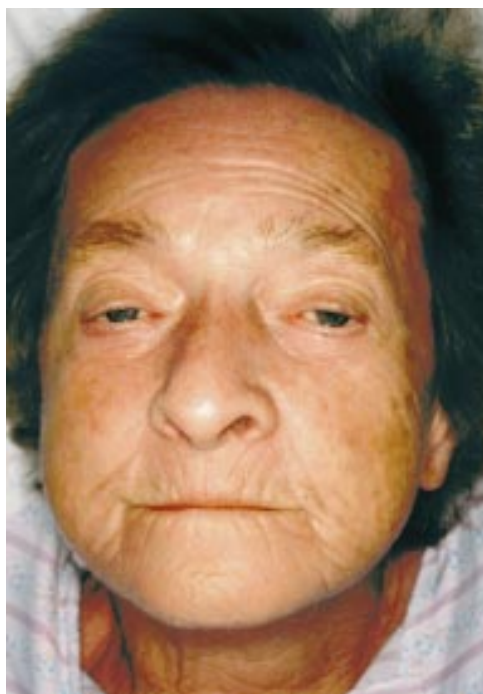

Figure 1 The patient's face (reproduced with her permission).

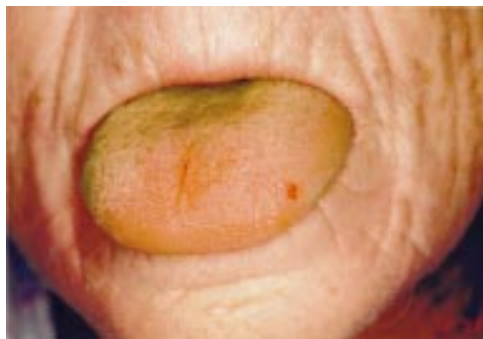

Figure 2 Photograph taken on examination.

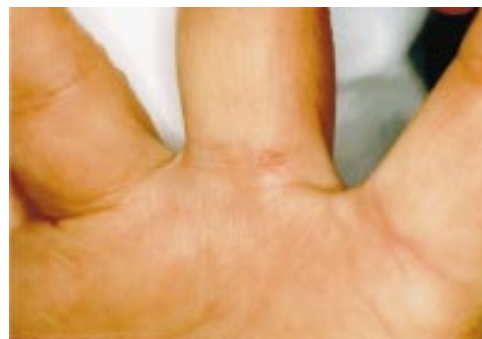

Figure 3 Photograph of the patient's hand.

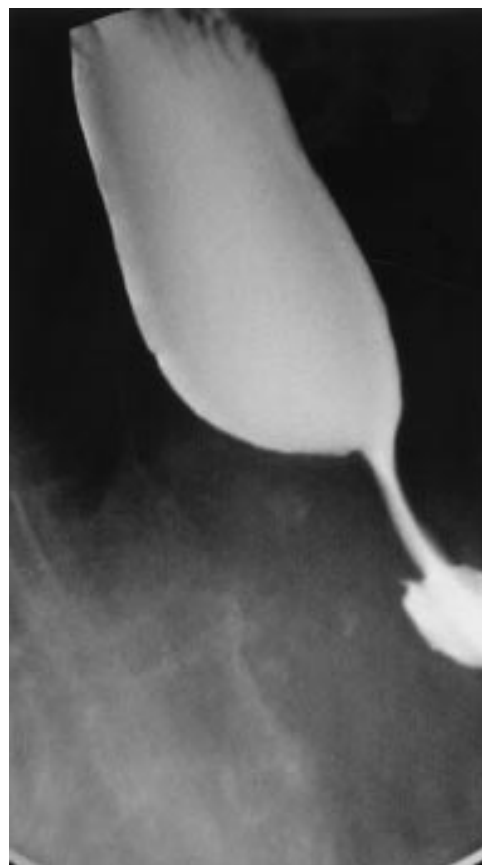


Figure 4 Barium swallow.

University Hospital
UCL of
Mont-Godinne,
Department of
Internal Medicine,
5530 Yvoir, Belgium
O Vancollie
E Delgrange
J Donckier

Correspondence to:
Professor Donckier
(e-mail: Julian.Donckier@
mint.ucl.ac.be)

Submitted 19 April 1999
Accepted 5 July 1999

Questions

- (1) What do the clinical photographs and radiograph show?
- (2) What is the most likely diagnosis?
- (3) What are the possible explanations for bilateral ptosis and myositis?

Answers on p 312.

Diffuse swelling of the penis in a young adult

N Sarath Krishna, E S Glen

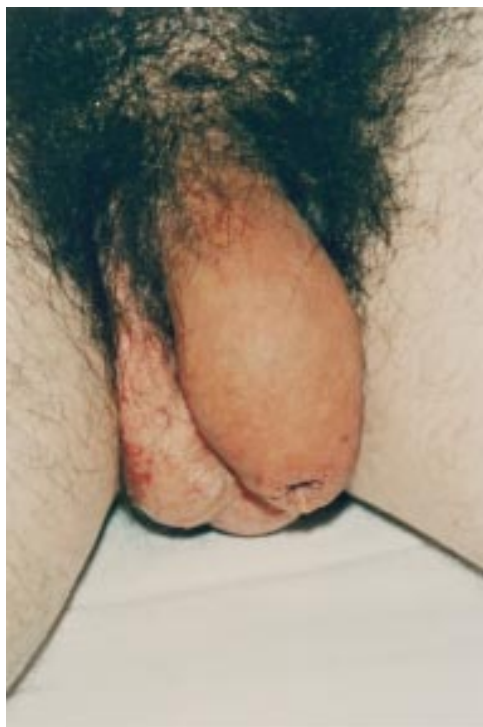

Figure 1 Photograph of swollen penis (reproduced with the patient's permission).

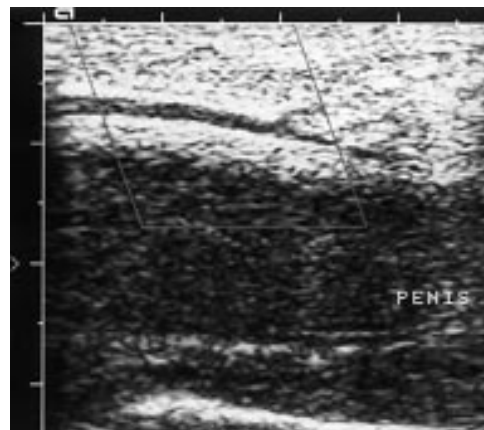


Figure 2 Doppler ultrasound scan.

Department of
Urology, Southern
General Hospital, 1345
Govan Road, Glasgow
G51 4TF, Scotland, UK
N Sarath Krishna
E S Glen

Correspondence to:
Mr Sarath Krishna Nalagatla
(e-mail:
sarath@rohini25.freemove.
co.uk)

Submitted 1 June 1999
Accepted 5 July 1999

Answers on p 313.

Epsom General
Hospital, Epsom,
Surrey UK:
Department of
Chemical Pathology
L Ranganath

Department of
Haematology
M J Semple

Correspondence to:
Dr L Ranganath,
Department of Clinical
Chemistry, Royal Liverpool
University Hospital, Prescot
Street, Liverpool L7 8XP, UK
(e-mail:
lrang@liverpool.ac.uk)

Submitted 1 June 1999
Accepted 12 July 1999

A 25 year old man presented to our hospital with a seven day history of pain in the root of the penis and two day history of swelling of the penis. On questioning there was no history of prolonged intercourse, local trauma, insect bite, or infection. He had no relevant past medical history. General physical and abdominal examination were unremarkable. On local

examination the penis was diffusely swollen due to oedema. A long, thick, firm, and cord like structure was felt along the dorsal aspect of the penis. It was not tender. There was no evidence of venous thrombosis elsewhere. Urine microscopy, full blood count, and coagulation studies were all within normal limits. Colour Doppler ultrasonography of the penis showed a prominent superficial dorsal vein of penis with no evidence of spontaneous flow. A clinical photograph of penis and Doppler ultrasound scan of the penis are shown in figs 1 and 2 respectively.

Questions

- (1) What is the probable diagnosis?
- (2) What is the aetiology and pathology of this condition?
- (3) How can this condition be managed?

Hypercalcaemia in a 63 year old man

L Ranganath, M J Semple

A 63 year old man with IgG myeloma was found to have hypercalcaemia; specific hypocalcaemic measures such as intravenous fluids and pamidronate 60 mg followed by 1.6 g of oral sodium clodronate daily in addition to antimyeloma agents such as prednisolone, Adriamycin, and carmustine were unsuccessful in restoring eucalcaemia (fig 1).

Blood test results while on treatment with clodronate are shown in table 1.

Questions

- (1) What is the cause of the apparent resistance to bisphosphonates?
- (2) What further investigations for hypercalcaemia should be undertaken?
- (3) What are the causes of hypercalcaemia in myeloma?

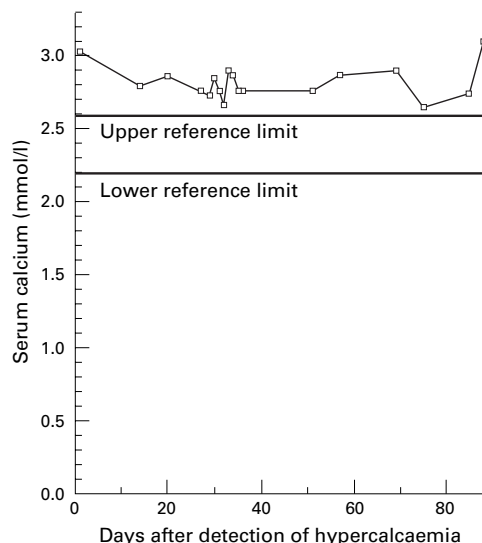


Figure 1 Profile of serum corrected calcium before and after treatment.

Table 1 Blood test results while on treatment with clodronate

	Patient's result	Reference range
Calcium (corrected)	3.03 mmol/l	(2.2–2.6)
Phosphate	1.34 mmol/l	(0.80–1.40)
Alkaline phosphatase	137 IU/l	(35–230)
Albumin	35 g/l	(35–53)
Total protein	103 g/l	(63–79)
Urea	7.1 mmol/l	(2.3–6.3)
Creatinine	106 µmol/l	(50–130)
Intact parathyroid hormone	4.7 pmol/l	(0.5–5.5)
25-Hydroxycholecalciferol	80 nmol/l	(20–110)
1, 25-Dihydroxycholecalciferol	93 pmol/l	(40–150)

Subacute haemorrhage into the spinal cord

John J Craig, R S Cooke, J P McCann

Answers on p 314.

A 27 year old previously well man developed mid-back pain immediately after doing "star jumps". The pain was not relieved by rest and was associated with increasing weakness and sensory disturbance of the legs. On admission to hospital 72 hours later he had asymmetric flaccid weakness of the legs, absent deep tendon reflexes, flexor plantar responses, and reduced sensation to T4 on the left and T8 on the right. Perineal sensation was preserved but he required the insertion of a urinary catheter because of urinary retention. Examination was otherwise unremarkable.

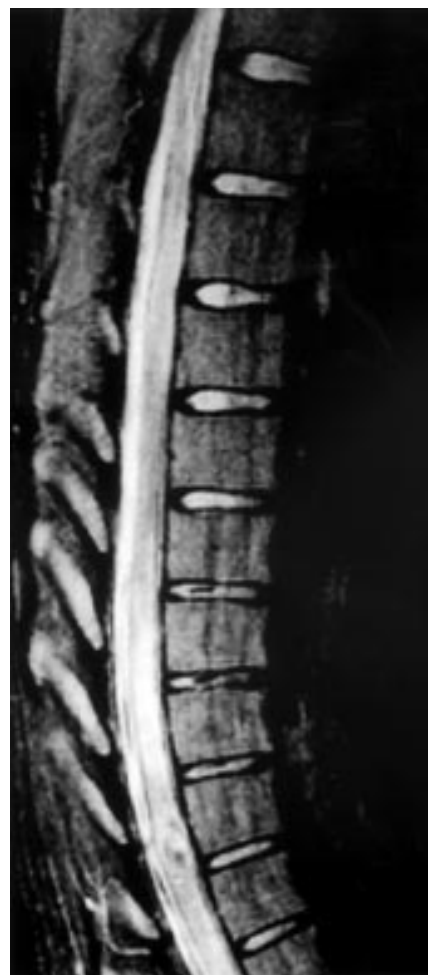

Figure 1

Department of
Neurology, Royal
Victoria Hospital,
Belfast BT12 6BA, UK
J J Craig
R S Cooke

Spinal Injuries Unit,
Musgrave Park
Hospital, Belfast
J P McCann

Correspondence to:
Dr Craig

Submitted 11 January 1999
Accepted 18 August 1999

Questions

- (1) What is the investigation and what does it show (fig 1)?
- (2) What should be done next?
- (3) Are any other investigations indicated?
- (4) What long term problems might this young man complain of and how should they be managed?

SELF ASSESSMENT ANSWERS

Progressive breathlessness in an 18 year old male**Q1: What are the clinical and pathological diagnoses?**

Chronic obstructive pulmonary disease and pulmonary emphysema.

Q2: What aetiologies should be considered?

The α_1 -antitrypsin levels should be checked, as deficiency is associated with pulmonary emphysema.¹ This was normal. In addition, α_1 -antitrypsin dysfunction and α_1 -antichymotrypsin deficiency² should be considered. Inorganic dust exposure³ and cadmium exposure⁴ have been associated with pulmonary emphysema and it has been described in intravenous drug abusers, particularly of heroin, methadone,⁵ and injected dissolved methylphenidate (Ritalin) tablets.⁶ Hereditary bullous emphysema can develop precociously in rare syndromes such as Salla's disease, cutis laxa, and idiopathic non-arteriosclerotic cerebral calcification syndrome.⁴ None of these unusual aetiologies were identified in our patient.

Q3: What treatment options are available?

Inhaled bronchodilator therapy is the mainstay of treatment, with β_2 -agonists and anticholinergic agents. A trial of oral corticosteroids should be performed and if significant improvements in symptoms and lung function documented, this may justify inhaled corticosteroids. There is however no evidence that steroids halt the progression of smoking induced emphysema. In this case, there was no response to oral steroids. In advanced pulmonary emphysema, surgical options include lung volume reduction surgery and bullectomy, to improve lung mechanics and thereby reduce dyspnoea and increase exercise capacity. In younger subjects, significant ventilatory impairment progressing to respiratory failure may be treated with lung transplantation. In this case, reduction surgery was not performed but the patient did progress to single lung transplantation 30 months after presentation. However, even with transplantation, outcome is poor, with a five year actuarial survival of only 42.6%.⁷

Discussion

Emphysema (abnormal enlargement of air-space beyond the terminal bronchioles, with destruction of their walls without fibrosis), in the majority of cases, is related to cigarette smoking, though in rare cases other factors may be involved as outlined above. Other possible factors considered in this case were exposures to fibreglass and inhalational anaesthetic gases. Exposure to fibreglass does not cause airway obstruction³ and there have been no reports of associations between emphysema and anaesthetic gases. We did not perform a functional assessment of α_1 -antitrypsin or

Learning points

- Pulmonary emphysema does not always occur in tobacco smokers.
- Emphysema progresses at variable rates and can be rapidly progressive.
- The inflammatory mechanisms causing pulmonary emphysema are incompletely understood.
- In young patients with symptoms suggestive of asthma, an alternative diagnosis should be considered when poorly responsive to conventional treatment.

measure α_1 -antichymotrypsin levels, but even if abnormal, the speed of progression in a non-smoker would be remarkable, making this an unlikely causative factor. We have identified only one previous similar report,⁸ with idiopathic emphysema and rapid deterioration in ventilatory function, progressing to respiratory failure in a young non-smoker.

Recent research suggests that protease-antiprotease,⁹ and oxidant-antioxidant imbalance,^{4,9} may be involved in the pathogenesis of emphysema. We suggest that a single exposure to a toxic or infectious agent may have caused inflammatory cell sequestration, protease and reactive oxidant species release, and progressive lung destruction in our patient.

It has been suggested that emphysema may progress, even after removal of the stimulus.¹⁰ This case demonstrates deteriorating lung function, with no obvious ongoing inflammatory stimulus and illustrates that chronic inflammation and lung destruction over many years is not always required to produce emphysema and end stage respiratory failure.

Final diagnosis

Idiopathic pulmonary emphysema.

- 1 Siafakas NM, Verriere P, Pride NB, *et al.* Optimal assessment and management of COPD. *Eur Respir J* 1995;8:1398-420.
- 2 Faber JP, Poller W, Olek K, *et al.* The molecular basis of α_1 -antichymotrypsin deficiency in a heterozygote with liver and lung disease. *J Hepatol* 1993;18:313-21.
- 3 Hunting KL, Welch LS. Occupational exposure to dust and lung disease among sheet metal workers. *Br J Indust Med* 1993;50:432-42.
- 4 Fraser RS, Paré JAP, Fraser RG, *et al.* Diseases of the airways. *Synopsis of diseases of the chest*. 2nd Ed. London: WB Saunders, 1994: 2102.
- 5 Weisbrod GL, Rahman M, Chamberlain D, *et al.* Precocious emphysema in intravenous drug abusers. *J Thorac Imaging* 1993;8:233-40.
- 6 Sherman CB, Hudson LD, Pierson DJ. Severe precocious emphysema in intravenous methylphenidate (Ritalin) abusers. *Chest* 1987;92:1085-7.
- 7 Arcasoy SM, Kotloff RM. Lung transplantation. *N Engl J Med* 1999;340:1081-91.
- 8 Habenstein KR, Roy TM, Fields CL. Pulmonary emphysema in a non-smoker with normal alpha-1-antitrypsin. *J Ky Med Assoc* 1992;90:327-30.
- 9 Celli BR, Snider GL, Heffner J, *et al.* Review of chronic obstructive pulmonary disease. *Am J Respir Crit Care Med* 1995;152:S78-121.
- 10 Maestrelli P, Calcagni PG, Saetta M, *et al.* Integrin upregulation on sputum neutrophils with chronic airway obstruction. *Am J Respir Crit Care Med* 1996;154:1296-300.

Table 1 Characteristics of the two main variants

	Diffuse (%) Limited (%)	
	Proximal	Distal (hands, feet, face, forearms)
Cutaneous sclerosis	Recent	Old (for years)
Raynaud's phenomenon	20	40
Calcinosis	60	90
Telangiectasia	70	5
Interstitial pulmonary fibrosis	5	35
Pulmonary hypertension	20	1
Renal crisis	30	10
Anti Scl-70 antibodies	10	75
Anticentromere antibodies	50	70
Ten years' survival		

Sleeping eyes

Q1: What do the clinical photographs and radiograph show?

She presented a bilateral blepharoptosis (fig 1) with a thickening of the eyelid. There was also an inability to open the mouth fully (fig 2) accompanied by furrowing and puckering around the mouth. Her face is drawn. There are lingual and digital telangiectasia (fig 3). A barium swallow (fig 4) performed in the assessment of dysphagia, revealed a loss of peristalsis and a stricture of the oesophagus.

Q2: What is the most likely diagnosis?

Systemic sclerosis is a rare connective tissue disease characterised by fibrotic changes in the skin, blood vessels, and various internal organs such as the lungs and gastrointestinal tract. There are two main variants including limited and diffuse forms (table 1).

Serum antinuclear antibodies are a prominent feature of systemic sclerosis with a prevalence ranging from 89% to 95%.¹

This case illustrates limited cutaneous systemic sclerosis complicated by pulmonary hypertension.²

Q3: What are the possible explanations for bilateral ptosis and myositis?

Bilateral ptosis is a rare clinical condition. Differential diagnosis is given in box 1. A metabolic origin was excluded by a blood sample. Myasthenia can be associated with systemic sclerosis but bilateral ptosis is generally encountered during myasthenia crisis, which was not the case in our patient.

The bilateral ptosis was caused by thickening of the eyelids.

Muscular involvement is present in the majority of cases of systemic sclerosis (weakness of muscles). A few patients have florid

Box 1: Bilateral ptosis: differential diagnosis

- Endocrine or metabolic myopathy
- Myasthenia gravis
- Muscular dystrophy
- Polyradiculoneuropathy
- Scleroderma
- Miscellaneous: bilateral cavernous sinus syndrome, bilateral Claude Bernard-Horner syndrome

changes of polymyositis and are usually classified as having an overlap syndrome.

Final diagnosis

Systemic sclerosis.

1 Jacobsen S, Halberg P, Ullman S, *et al.* Clinical features and serum antinuclear antibodies in 230 Danish patients with systemic sclerosis. *Br J Rheumatol* 1998;37:39–45.

2 Denton CP, Cailles JB, Phillips GD, *et al.* Comparison of Doppler echocardiography and right heart catheterization to assess pulmonary hypertension in systemic sclerosis. *Br J Rheumatol* 1997;36:239–43.

Diffuse swelling of the penis in a young adult

Q1: What is the probable diagnosis?

Mondor's disease of the penis. It is thrombophlebitis of the superficial dorsal vein of the penis.

Q2: What is the aetiology and pathology of this condition?

The main cause of the disease is frequent or prolonged intercourse. Other causes are enumerated in box 1. Thrombophlebitis of the superficial dorsal vein of the penis is a benign disease. Clinical and experimental evidence from previous reports suggests that stretching and torsion of the vein resulting from genital trauma leads to endothelial damage and thrombosis. Thrombophlebitis of the superficial dorsal penile vein can be divided into three clinical stages: acute, subacute, and chronic.

Q3: How can this condition be managed?

The majority of the cases of Mondor's disease of the penis are treated conservatively. The acute stage has been treated in a variety of ways with anti-inflammatory agents, anticoagulant drugs, and antibiotics with good results. For subacute and chronic stages, most have used anti-inflammatory agents and local heparin creams. Most cases resolve in four to six weeks. It is important that the patient should avoid sexual intercourse during medical treatment. In persistent cases, either penile vein resection or thrombectomy has been recommended. The prognosis is good. There are no reports of erectile dysfunction or penile deformity after treatment.

Discussion

Superficial venous thrombosis of the chest wall was first reported by Mondor in 1939.¹ It was described in the penile veins by Braun-Falco in 1955.² Isolated superficial dorsal vein thrombosis was reported in 1958 by Helm and Hodge.³ Mondor's disease of the penis is a

Box 1: Common causes of penile Mondor's disease

- Repeated sexual intercourse
- Trauma to penis
- Infection
- Penile intravenous drug abuse
- Idiopathic

Learning points

- Mondor's disease of penis is a benign condition.
- Trauma from prolonged or frequent sexual intercourse is the commonest cause.
- Sudden and painful or painless cord like induration on the penile dorsal surface is the commonest presentation.
- Doppler ultrasonography is helpful in both diagnosis and follow up.
- Medical treatment and, when indicated, vein resection are successful.

benign condition. Sexual intercourse should be considered as the main aetiological factor.⁴ Patients present with cord like induration on the dorsal surface of the penis. Pain may or may not be present. Swelling of the penis due to oedema is seldom present. It can present as an acute thrombophlebitis in which case pain and fever are often associated with significant inflammation of the penis. Diagnosis is obvious on clinical examination. Colour Doppler ultrasonography⁴ is an important tool in the diagnosis and follow up of these patients to visualise resolution of the thrombus and restoration of normal blood flow. Most of the cases seen early respond well to conservative treatment such as anti-inflammatory agents and anticoagulant and antithrombotic drugs. These drugs reduce the recovery period. In cases of infection antibiotics must be used. Most cases resolve in four to six weeks and are recanalised by nine weeks.⁴ In persistent cases, surgical treatment is recommended—for example, stripping of the vein or thrombectomy.⁵ Surgical treatment in these advanced cases is very effective for relieving pain, decreasing skin induration, and producing aesthetically pleasing results. There have been no reports of deformity of the penis or impotence after treatment.

Final diagnosis

Mondor's disease of the penis.

- 1 Mondor H. Tronculite sous-cutanee de la paroi thoracique antero-laterale. *Mem Acad Chir* 1939;65:1271–8.
- 2 Braun-Falco O, zur Klinik. Histologie und pathogenese der strangformigen oberflächlichen phlebitiden. *Derm w schr* 1955;132:705–15.
- 3 Helm JD Jr, Hodge IG. Thrombophlebitis of a dorsal vein of the penis: report of a case treated by phenylbutane (Butalidin). *J Urol* 1958;79:306–7.
- 4 Sasso F, Gulino G, Bazar M, et al. Penile Mondor's disease: an underestimated pathology. *Br J Urol* 1996;77:729–32.
- 5 Mondor H, Bertrand I. Thrombophlebitis et peri-phlebitis de la paroi thoracique anterieur. *Presse Med* 1951;59:1533.

Hypercalcaemia in a 63 year old man**Q1: What is the cause of the apparent resistance to bisphosphonates?**

The non-suppressed serum intact parathyroid hormone during hypercalcaemia should suggest the possibility of coexisting primary hyperparathyroidism, although this is usually responsive to calcium reducing therapeutic measures. Both oral and intravenous routes of

bisphosphonate administration proved ineffective in inducing eucalcaemia and excludes malabsorption as a cause. The possibility of an artifactual cause for hypercalcaemia must be considered.

Q2: What further investigations for hypercalcaemia should be undertaken?

Ionised calcium should be measured on an anaerobically collected heparinised plasma sample to exclude primary hyperparathyroidism and confirm the presence of abnormal calcium binding globulins.

Q3: What are the causes of hypercalcaemia in myeloma?

See table 1.

Table 1 Causes of hypercalcaemia in myeloma

Myeloma bone disease
Postulated chemical mediators for osteoclast activating factor include ^{1, 2}
Interleukin-1
Interleukin-6
Tumour necrosis factor- α
Lymphotoxin
Colony stimulating factors
Unidentified factors
PTH-rP ³
Abnormal calcium binding globulins ^{4, 5}
Coincident presence of another disease causing hypercalcaemia including primary hyperparathyroidism ⁶

PTH-rP = parathyroid hormone related peptide.

Discussion

The plasma ionised calcium in this man on oral clodronate was found to be 1.10 mmol/l (reference range 1.13–1.32) when a simultaneous corrected calcium was 3.03 mmol/l excluding primary hyperparathyroidism and confirming the existence of abnormal calcium binding globulins. Concordance of measured total calcium between cresolphthalein complexone (in house laboratory method) and atomic absorption spectrophotometry confirmed the validity of the in-house measurement. A fasting urine sample revealed very low calcium excretion consistent with a low filterable (includes ionised) calcium (ratio of calcium and creatinine clearance was 0.001). In retrospect it was clear that our patient did not reliably exhibit renal impairment or symptoms such as polyuria and polydipsia at the time of recognition of hypercalcaemia, undoubtedly attributable to non-raised ionised calcium.

Hypercalcaemia in myeloma, generally due to bone resorption, is associated both with renal failure as well as a poor prognosis.⁷ Factors leading to hypercalcaemia in myeloma are shown in table 1. Abnormal calcium binding globulins, bound to variable regions of Fab regions of the immunoglobulin molecule, have been described in myeloma previously and are considered to be very rare. Prompt recognition prevents inappropriate calcium reducing treatment and false attribution of a poor prognosis in such cases. Of course, it must be remembered that genuine hypercalcaemia may be superimposed on the artifactual and greatly complicate the metabolic picture. Resistance to calcium reducing measures alerted us to the possibility of calcium binding proteins in this

patient with myeloma. In centres where ionised calcium is not routinely measured the artifactual nature of hypercalcaemia may be suspected when such resistance to calcium reducing measures is encountered.

Calcium in the blood is found in a bound state (approximately 40%; mainly bound to albumin in health), in a complex with citrate and other anions (<10%), as well as in an ionised form (approximately 50%).⁸ Only the ionised calcium controls and influences crucial biological processes such as neuromuscular transmission and excitability. Thus, changes in serum protein levels or acid-base status will affect the relationship between ionised and total calcium. Despite this total plasma calcium, adjusted to plasma albumin (adjusted or corrected serum calcium (mmol/l) = measured calcium concentration \pm 0.02 for every g/l of albumin above or below an arbitrary figure respectively such as 42 g/l in our laboratory), remains the most commonly measured index even in hypoalbuminaemia and paraproteinaemias. Although ionised calcium can be measured easily using ion selective electrodes, it is impractical to measure ionised calcium in all situations requiring calcium measurement as specimens must be obtained anaerobically to minimise changes in specimen pH.

Approaches to correction, described above, attempt to estimate the ionised calcium by adjusting for interindividual and intraindividual variation in albumin or total protein concentrations. Such “corrections” invoke the use of equations incorporating the mean of the affinity of albumin or total proteins for calcium.^{9,10} Correction allows both the comparison of an individual calcium result with a reference range as well as the monitoring of calcium in the same person from day to day, minimising artifactual changes due to haemoconcentration (due to tourniquet effect) or haemodilution factors (intravenous fluid therapy). However, such “correction” is misleading when binding proteins with abnormally high affinities are present as in our case.

Correction factors employed to produce total serum calcium are crude estimates of the biologically important ionised calcium. Resistance to therapeutic attempts to reduce circulating calcium concentrations, especially when symptoms and signs of significant hypercalcaemia are absent, should lead to suspicion of the presence of calcium binding globulins in myeloma.

Final diagnosis

Hypercalcaemia due to abnormal calcium binding globulins in myeloma.

- 1 Mundy GR, Salmon SE. Evidence for the secretion of an osteoclast stimulating factor in myeloma. *N Engl J Med* 1974;291:1041–6.
- 2 Roodman GD. Mechanisms of bone lesions in multiple myeloma and lymphoma. *Cancer* 1997;80:1557–63.
- 3 Tamura K, Kubota K, Kurabayashi H, et al. Evidence for parathyroid hormone-related peptide as a cause of hypercalcaemia in myeloma. *Blood* 1994;84:1692–3.
- 4 Jaffe JP, Mosher DF. Calcium binding by a myeloma protein. *Am J Med* 1979;67:343–6.
- 5 Ladenson JH, McDonald JM, Aguanno J, et al. Multiple myeloma and hypercalcaemia? *Clin Chem* 1979;25:1821–5.

- 6 Francis RM, Bynoe AG, Gray C. Hypercalcaemia due to the coexistence of parathyroid adenoma and myelomatosis. *J Clin Pathol* 1982;35:732–6.
- 7 Crawford SM. Hypercalcaemia, renal failure, and relapse in multiple myeloma. *Cancer* 1985;55:898–900.
- 8 Schaafsma G. Calcium in extracellular fluid. In: Nordin BEC, ed. *Calcium in human biology*. London: Springer-Verlaag, 1988: 241–59.
- 9 Parfitt AM. Chlorothiazide-induced hypercalcaemia in juvenile osteoporosis and hyperparathyroidism. *N Engl J Med* 1969;281:55–9.
- 10 Payne RB, Little AJ, Williams RB, et al. Interpretation of serum calcium in patients with abnormal serum proteins. *BMJ* 1973;iv:643–6.

Subacute haemorrhage into the spinal cord

Q1: What is the investigation and what does it show?

The investigation is a sagittal T2 weighted magnetic resonance image (MRI) of the dorsal (thoracic) cord. It shows an ovoid, intramedullary (within the spinal cord) lesion with little associated cord expansion. The lesion is of mixed signal intensity and consists of a nodule of high signal abnormality inferiorly with surrounding low signal. The high signal is consistent with subacute blood and represents methaemoglobin, while the low signal is consistent with chronic haemorrhage and represents haemosiderin. There is also high signal abnormality within the spinal cord extending superiorly and inferiorly in keeping with cord oedema. The differential diagnosis for an intramedullary lesion containing blood in various states of degradation is shown in box 1. The appearances are those of a vascular malformation into which haemorrhage has occurred at different times. The lesion is most likely a cavernous malformation because of all vascular malformations these are the most prone to episodes of repeated bleeding. MRI is particularly sensitive at detecting the different blood degradation products formed because of their differing paramagnetic qualities. Although haemorrhage can occur into a tumour, apart from ependymomas, the mixture of subacute and chronic blood would be unlikely. Cord expansion would be expected for a spinal cord tumour and tumours often show contrast enhancement, neither of which were the case for this patient. Although symptoms began while exercising there was no trauma reported and the time course was not correct for traumatic haematomyelia. Previous reports have commented on vascular malformations bleeding after exercise and minor trauma however.

Box 1: Differential diagnosis for intramedullary lesion of the spinal cord of mixed signal intensities

- Cavernous malformation
- Intramedullary AVM
- Venous malformation
- Capillary malformation
- Post-traumatic haematomyelia
- Haemorrhage into a neoplasm
- Granulomatous disease

Q2: What should be done next?

The patient has a space occupying lesion of the spinal cord which although probably present for some time, has resulted in recent onset of progressive neurological decline. Immediate neurosurgical assessment with a view to surgical exploration must be arranged if further deterioration is to be prevented.

The patient underwent a two level mid-dorsal laminectomy with complete evacuation of the lesion. At operation abnormal vessels were noted over the surface of the cord but there was no evidence of enlarged feeding vessels or draining veins that would be more in keeping with an arteriovenous malformation (AVM). Histopathological examination showed occasional thin walled blood vessels containing blood clot with surrounding gliosis. There was no evidence of tumour. The lesion was felt to be a cavernous malformation.

Cavernous malformations are uncommon vascular malformations that usually occur intracranially.¹ Their presence within the spinal cord, however, is increasingly being recognised with MRI scanning which demonstrates the characteristic but not pathognomonic mixed signal abnormalities of these lesions.² Clinically they may be asymptomatic but most often present either with progressive or episodic neurological decline, or as in our patient with acute neurological dysfunction.³ Surgery is the treatment of choice for this condition but does not always result in improvement either because total removal of the lesion is not possible or symptoms have been present for weeks to months.⁴ In cases where symptoms have been present for a short a time as in this patient immediate surgical intervention may halt disease progression and result in clinical improvement.³

Q3: Are any other investigations indicated?

Because of the presence of dilated vessels over the surface of the cord spinal angiography, which is usually normal with cavernous malformations, should be performed to ensure that the lesion is not in fact an AVM. Neither serpentine filling defects nor abnormal "blushes" were seen on angiography in this case excluding an AVM.

Apart from performing a repeat MRI of the spinal cord to determine if the lesion was completely removed, an MRI of the brain should

Box 2: Long term sequelae of intramedullary insult

- Impaired mobility
- Urinary incontinence
- Faecal incontinence
- Erectile dysfunction
- Impotence
- Impaired activities of daily living skills
- Unemployment

also be performed as some patients have multiple lesions.⁵ The best management of asymptomatic cerebral lesions is not known.

Q4: What long term problems might this young man have and how should they be managed?

This man presented with the features of incomplete paraplegia with paralysis, anaesthesia, and sphincter disturbance. Postoperatively these did not improve rapidly and he required management in a spinal cord injury rehabilitation programme on both an inpatient and outpatient basis. He is likely to have ongoing problems as outlined in box 2 and require specialist follow up for these and other problems such as pressure sores, neuropathic pain, and management of spasticity.

Final diagnosis

Intrinsic spinal cord compression from haemorrhage into a cavernous malformation.

We would like to thank Dr A Gray, Consultant Radiologist, Musgrave Park Hospital, Belfast for making the MR images available and Dr C S McKinstry, Consultant Neuroradiologist, Royal Victoria Hospital, Belfast for reviewing the MR images.

- 1 Requena I, Arias M, Lopez-Ibor L, *et al.* Cavernomas of the central nervous system: clinical and neuroimaging manifestations in 47 patients. *J Neurol Neurosurg Psychiatry* 1991;54:590-4.
- 2 Turjman F, Joly D, Monnet O, *et al.* MRI of intramedullary cavernous haemangiomas. *Neuroradiology* 1995;37:297-302.
- 3 Ogilvy CS, Louis DN, Ojemann RG. Intramedullary cavernous angiomas of the spinal cord: clinical presentation, pathological features, and surgical management. *Neurosurgery* 1992;31:219-30.
- 4 Rees Cosgrove G, Bertrand G, Fontaine S, *et al.* Cavernous malformations of the spinal cord. *J Neurosurg* 1988;68:31-6.
- 5 Rigamonti D, Drayer BP, Johnson PC, *et al.* The MRI appearance of cavernous malformations (angiomas). *J Neurosurg* 1987;67:518-24.