

CASE REPORTS

Crohn's colitis and idiopathic thrombocytopenic purpura

Michael S Boyne, Kevin R Dye

Abstract

A 17 year old girl with active Crohn's colitis developed idiopathic thrombocytopenic purpura that was managed with intravenous immune globulins and cyclosporin A. The possible association between Crohn's disease and immune thrombocytopenia is explored.

(*Postgrad Med J* 2000;76:299–300)

Keywords: Crohn's disease; colitis; thrombocytopenia

Various autoimmune diseases have been associated with inflammatory bowel disease, with the majority of reports describing clustering of autoimmune haemolytic anaemia¹ with ulcerative colitis. An unusual case of Crohn's colitis with the subsequent development of idiopathic thrombocytopenic purpura (ITP) is described.

Case report

A 17 year old girl with a history of Crohn's pancolitis without ileal involvement since age 8, was relatively well until the age of 16, when she had several hospitalisations for exacerbations of her Crohn's disease. This necessitated a medical regimen of prednisone (30 mg/day), azathioprine (100 mg/day), metronidazole, and mesalamine but the symptoms of colitis persisted.

Apart from an anaemia of chronic disease (packed cell volume 0.247), her blood counts were normal until May 1996 when her platelet count was $3 \times 10^9/l$, haemoglobin 85 g/l, packed cell volume 0.258, and leucocyte count $9.2 \times 10^9/l$. She was also experiencing epistaxis and bloody diarrhoea. She had no history of recent viral infections, immunisations, recent blood transfusions, or use of recreational drugs. Physical examination revealed only mild cushingoid facies and there was no hepatosplenomegaly. Erythrocyte sedimentation rate was 60 mm/hour. Antinuclear antibodies, anti-HIV, Coombs' tests, platelet

associated IgG, white cell differential, partial thromboplastin time, and prothrombin time were unremarkable. A peripheral blood smear showed marked thrombocytopenia with occasional giant platelets and no evidence of microangiopathic haemolytic anaemia. A bone marrow biopsy specimen revealed normocellularity with megakaryocytic hyperplasia compatible with peripheral platelet destruction.

The patient's medications were discontinued and she was managed initially with methylprednisone (2 mg/kg/day) and platelet transfusions but without effect. She was then treated with intravenous gammaglobulin (1 g/kg/day) which raised her platelet count to $45 \times 10^9/l$ and maintained on cyclosporin A (5 mg/kg/day) and prednisone (60 mg/day) as an outpatient. Her platelet counts remained between 400 and $680 \times 10^9/l$. A colonoscopy, one month after discharge, revealed no active Crohn's disease. However, two months later, the return of active colitis prompted the addition of mesalamine to her regimen. One month later, she developed an inflammatory colonic mass necessitating left hemicolectomy. Histology of the mass was consistent with severely active Crohn's colitis. She remained asymptomatic, with normal platelet counts and did not require immunosuppressive medication.

Discussion

There are multiple case reports in the literature describing the association of inflammatory bowel disease with extraintestinal autoimmune disorders. The actual prevalence of these associations is not known, as no controlled population studies, to date, have been performed. However, in the case-control study by Snook *et al*, there was a clustering of autoimmune disorders (including primary sclerosing cholangitis) with ulcerative colitis, with a prevalence of 8.2%–10.5%.¹ The study showed little evidence of an association with

Department of Internal Medicine, Carilion Roanoke Community Hospital and University of Virginia School of Medicine, 101 Elm Avenue SE, Roanoke, VA 24013, USA
M S Boyne
K R Dye

Correspondence to:
Dr Michael Boyne, Division of Endocrinology and Metabolism, Johns Hopkins University School of Medicine, 1830 East Monument Street, Suite 333, Baltimore, MD 21287-4904, USA (e-mail: mboyne@welch.jhu.edu)

Submitted 29 March 1999
Accepted 10 September 1999

Table 1 Reported cases of Crohn's disease and idiopathic thrombocytopenic purpura (ITP)

Reference	Age	Sex	Duration between Crohn's disease and ITP	Location of Crohn's disease	Response to glucocorticoids	Platelet antibodies	Treatment of ITP
4	65	F	(+) 28 years	Colon	Transient	Yes	Splenectomy, colectomy
5	19	F	On presentation	Colon, distal ileum	Transient	No	Splenectomy, LTF
6	43	M	(-) 2 months	Colon	Yes	?	Glucocorticoids
7	54	M	(-) 7 months	Colon, distal ileum	Yes	Yes	Glucocorticoids
8	22	F	(+) 6 weeks	Colon	Yes	?	Glucocorticoids, 6MP
Present case	17	F	(+) 9 years	Colon	No	No	IV IgG

Key: 6MP = 6-mercaptopurine; LTF = lost to follow-up; (+) = Crohn's disease occurred before ITP; (-) = ITP occurred before Crohn's disease; IV IgG = intravenous gammaglobulins.

Crohn's disease, irrespective of the extent of colonic involvement.

The association between ITP and ulcerative colitis has been well described,² with an estimated prevalence of 0.1%–0.48%.^{1–3} However, there are only five other reported cases involving ITP and Crohn's disease as summarised in table 1.^{4–8} The most notable common factor is the extensive colonic involvement in all the cases with active colitis being present during the development of the thrombocytopenia. The resolution of ITP, only after colectomy in the case by Kosmo *et al*,⁴ also lends some credence to the idea of the colon being involved in the pathogenesis. Hypothetically, during severe colitis, antigens of the colonic lumen (such as bacterial antigens) could generate a humoral response, leading to antibodies that cross react with platelet surface antigens, thus resulting in ITP. An alternative mechanism could be that severe colonic inflammation leads to local destruction and/or sequestration of platelets in the colonic vasculature, which could result in the absence of circulating platelet antibodies and resistance to glucocorticoids. Of course, one cannot totally dismiss a fortuitous association between Crohn's colitis and a self limiting ITP in these cases.

This patient, notably, despite having Crohn's colitis for nine years, did not develop ITP until she had severe flaring of her colitis, raising the possibility of a temporal association. Also, her ITP developed while on glucocorticoids, and once established, the ITP remained steroid resistant. This steroid resistance was also noted in two of the other cases^{4–5} and has occurred in some cases of ITP associated with ulcerative colitis.^{2–8} The possibility of a drug induced mechanism seems unlikely. Azathioprine, in one series, caused the sudden onset of isolated thrombocytopenia in 1.4% of treated patients with Crohn's disease, but the mechanism is related to bone marrow suppression and there are no reported cases of an immunological mechanism.⁹ Unlike sulfasalazine, which can cause immunological destruction of platelets, mesalamine causes thrombocytopenia through non-immunological mechanisms, that is, bone marrow suppression with hypocellularity.¹⁰ Also, this patient was rechallenged with mesalamine without recurrence of thrombocytopenia. There are no reported cases of ITP associated with metronidazole.

The patient was treated with immune globulins, which stimulated partial recovery of her platelet counts, and then continued on maintenance therapy with cyclosporin A in an attempt to maintain her platelet counts¹¹ and induce remission of the Crohn's colitis. The cyclosporin did induce remission of her colitis as shown by colonoscopy, but this effect was not sustainable, which is consistent with previous observations of similar low dose regimens.¹² Partial colectomy ultimately enabled treatment of the underlying Crohn's colitis, discontinuation of the cyclosporin and there was no recur-

Learning points

- Idiopathic thrombocytopenic purpura can be an extraintestinal autoimmune manifestation of ulcerative colitis and less commonly, Crohn's colitis.
- Medications used to control Crohn's disease may cause drug induced thrombocytopenia and should be excluded as a potential aetiology of the thrombocytopenia.
- Crohn's associated thrombocytopenia should be managed like other cases of ITP, but high dose glucocorticoids may not be effective.

rence of thrombocytopenia. In the cases of ulcerative colitis and ITP, the thrombocytopenia resolved with glucocorticoids or immune globulins, although it was necessary to perform splenectomies in the steroid resistant patients.^{2–8} In three cases of Crohn's colitis, glucocorticoids were therapeutic,^{6–8} but the other cases had only transient responses.^{4–5} These cases did not respond to splenectomy but one eventually responded to colectomy.⁴ Consequently, it would seem reasonable that Crohn's associated ITP should be treated first with glucocorticoids and in resistant or severe cases immune globulins may be tried, which is similar to recognised consensus guidelines on the management of ITP.¹³ The efficacy of cyclosporin is questionable in this case and cannot be recommended at present. The present data in refractory cases seem to indicate that splenectomy may not be a successful therapeutic modality, but it is too early to routinely recommend colectomy as an alternative.

- 1 Snook JA, de Silva HJ, Jewell DP. The association of autoimmune disorders with inflammatory bowel disease. *Q J Med* 1989;72:835–40.
- 2 Yoshida EM, Chaun M, Freeman HJ, *et al*. Immune thrombocytopenic purpura in three patients with pre-existing ulcerative colitis. *Am J Gastroenterol* 1996;91:1232–5.
- 3 Edwards FC, Truelove SC. The course and prognosis of ulcerative colitis. Part III: complications. *Gut* 1964;5:1–15.
- 4 Kosmo MA, Bordin G, McMillan R. Immune thrombocytopenia and Crohn's disease. *Ann Intern Med* 1986;104:136.
- 5 Baudard M, Molina T, Benfiguig K, *et al*. Idiopathic thrombocytopenic purpura with Crohn's disease. *Haematologia* 1998;83:92–3.
- 6 Arruda VR, Montes CG, Seva-Pereira A, *et al*. Association of severe autoimmune thrombocytopenic purpura and Crohn's disease. *Am J Gastroenterol* 1997;9:1948–9.
- 7 Manzano ML, Yela C, Castellano G, *et al*. Idiopathic thrombocytopenic purpura and pancytopenia in a patient with Crohn's disease: a new association. *Am J Gastroenterol* 1996;91:1678.
- 8 Zlatanovic J, Korelitz BI, Wisch N, *et al*. Inflammatory bowel disease and immune thrombocytopenic purpura: is there a correlation? *Am J Gastroenterol* 1997;92:2285–8.
- 9 Connell WR, Kamm MA, Ritchie JK, *et al*. Bone marrow toxicity caused by azathioprine in inflammatory bowel disease: 27 years of experience. *Gut* 1993;34:1081–5.
- 10 Daneshmend TK. Mesalamine-associated thrombocytopenia. *Lancet* 1991;337:1297–8.
- 11 Schultz KR, Strahlendorf C, Warrior I, *et al*. Cyclosporin A therapy of immune-mediated thrombocytopenia in children. *Blood* 1995;85:1406–8.
- 12 Feagan BG, Rochon J, Fedorak RN, *et al*. Low-dose cyclosporine for the treatment of Crohn's disease. *N Engl J Med* 1994;330:1846–51.
- 13 American Society of Haematology ITP Practice Guideline Panel. Diagnosis and treatment of idiopathic thrombocytopenic purpura: recommendations of the American Society of Hematology. *Ann Intern Med* 1997;126:319–26.

Osteomyelitis and possible endocarditis secondary to *Lactococcus garvieae*: a first case report

P Rachael James, Suzanna M C Hardman, David L H Patterson

Abstract

Although osteomyelitis is commonly caused by staphylococcal infection, the first case of a lumbar osteomyelitis secondary to *Lactococcus garvieae* is reported. The case was complicated by possible endocarditis of an aortic valve prosthesis.

(*Postgrad Med J* 2000;76:301–303)

Keywords: *Lactococcus garvieae*; osteomyelitis

Lactococci are often believed to be of low virulence. We report a first case of osteomyelitis secondary to *Lactococcus garvieae* in a previously well, middle aged woman.

Case report

A 56 year old woman was referred to a rheumatology clinic with a nine week history of lower back pain and a five week history of rigors and night sweats. She was anorexic and had lost approximately 3.5 kg in weight in six weeks. Systems review was unremarkable. Her past medical history included a xenograph aortic valve replacement for aortic stenosis 12 years earlier (Ionesu-Shiley valve) and she was known subsequently to have mild aortic regurgitation. She took no prescribed medication and until this illness had been fit and well. Examination was unremarkable other than tenderness over L5/S1 and a soft early diastolic murmur at the left sternal edge in keeping with the aortic regurgitation. Results of routine tests were as follows: haemoglobin 99 g/l (mean corpuscular volume 92 fl), white cell count $6.1 \times 10^9/l$, erythrocyte sedimentation rate 74 mm/hour, and C reactive protein 12.6 mg/l; urea, electrolytes, creatinine, liver function tests, and a bone profile were all normal. The urine culture was negative, the chest radiography was normal, an electrocardiogram showed sinus rhythm with a normal axis and deep T wave inversion in the inferolateral territory. This was unchanged from earlier electrocardiograms (previous history of aortic stenosis). Thoracic and lumbar spine radiographs showed a thoracolumbar scoliosis with loss of disc height at L2/L3 and subchondral bone loss. A bone scan revealed increased tracer activity in the mid-lumbar region (fig 1).

Three days later she was admitted with increasing back pain and spiking temperatures. A diagnosis of presumed osteomyelitis was made and she was treated with analgesics and bed rest, while blood cultures were repeatedly taken during temperature spikes. A computed tomographic guided vertebral biopsy was arranged.

On day 6 after admission, pale splinter haemorrhages were noted in several nails of her hands and toes, not previously documented. There was no splenomegaly or microscopic haematuria and there was no other evidence of embolic phenomena. The murmur of aortic regurgitation was unchanged. A transthoracic echocardiogram revealed a well seated valve replacement in the aortic position, with thin mobile leaflets and mild to moderate transvalvular aortic regurgitation. Other valves appeared normal and no vegetations were identified. In view of the high suspicion of infective endocarditis, a transoesophageal echocardiogram was undertaken. No vegetations or changes consistent with an aortic root abscess were identified. The aortic regurgitation remained unchanged in severity and no further splinter haemorrhages subsequently developed.

All blood cultures, in addition to the biopsied bone, grew Gram positive cocci growing in chains on blood agar. They were identified as *Lactococcus garvieae* and were found to be indistinguishable from one another by API Strep (bioMerieux, Basingstoke, Hants, UK), sensitivity testing and their identity was confirmed by the Streptococcal Reference Laboratory (Respiratory and Systemic Infection Laboratory, London, UK). Vancomycin had been started after the bone biopsy, which was subsequently replaced by teicoplanin to which the organism was sensitive. With antibiotic treatment her clinical course improved and her remaining admission was uneventful. She was discharged after one month of intravenous treatment, with a temperature chart, to complete a further two months of teicoplanin at home via a Hickman line. She has remained well and continues under active follow up.

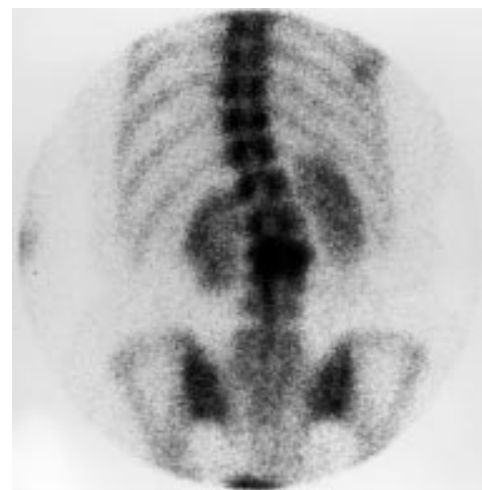


Figure 1 Bone scan showing increased tracer uptake in mid-lumbar region.

University College
London Medical
School, London, UK
P R James

Department of
Academic and Clinical
Cardiovascular
Medicine, University
College London
Medical School and
UCL and Whittington
Hospitals, London, UK
S M C Hardman

Whittington Hospital
NHS Trust, London,
UK
D L H Patterson

Correspondence to:
Dr P R James, Department
of Cardiology, Royal Sussex
County Hospital, Brighton
BN2 5BE, UK

Submitted 23 April 1999
Accepted 16 November 1999

Box 1: The Duke endocarditis service criteria for the diagnosis of infective endocarditis⁵

Definite infective endocarditis:

- Identification of micro-organisms from a vegetation by culture or histology, or from an intracardiac abscess.
- Histology from a vegetation or intracardiac abscess which confirms active endocarditis.
- Two major criteria or one major plus three minor or five minor criteria (see box 2).

Possible infective endocarditis:

Findings consistent with infective endocarditis but which do not satisfy “definite” or “rejected”.

Rejected:

- The presence of a firm alternative diagnosis.
- Resolution of clinical manifestations within four days of antibiotic treatment.
- Absence of pathology evidence at surgery or postmortem within four days of antibiotic treatment.

Discussion

This is the first report of osteomyelitis secondary to infection with *L. garvieae*, an emerging zoonotic pathogen.¹ Although first isolated from bovine sources, mainly involving cases of mastitis,² *L. garvieae* has subsequently been isolated from both fish and humans.¹ Lactococci are facultatively anaerobic, catalase negative, Gram positive cocci that occur singly, in pairs, or in chains. They are most often confused with enterococcus species but can be differentiated by biochemical tests.³ In contrast to streptococci and enterococci, lactococci are unusual pathogens and are considered to be opportunistic and of low virulence in humans. They have previously been recovered from urine and blood.⁴ We are unaware, however, of any previous reports of osteomyelitis secondary to *L. garvieae*, a condition where *Staphylococcus aureus* remains the commonest causative organism.

The complicating issue in this case was the finding of splinter haemorrhages in the presence of bacteraemia and a prosthetic heart valve. There should be a high index of suspicion for infective endocarditis in the presence of heart valve replacements, but there was no evidence on transthoracic or transoesophageal echocardiography of valve prosthesis or aortic root infection. The aortic regurgitation had previously been noted and was transvalvular rather than paraprosthetic. Using the criteria published by the Duke endocarditis service, the diagnosis of endocarditis in this case remains possible (see boxes 1 and 2).⁵ This method for assessing the likelihood of infectious endocarditis employs clinical, microbiological, serological, and echocardiographic parameters as major and minor criteria rather similar to the Jones

Box 2: Definitions of major and minor criteria⁵

Major criteria:

- Detection of an organism *typical* for infective endocarditis—for example, *Streptococci viridans* species, *Streptococcus bovis* from two separate blood cultures.
- Persistently positive blood cultures for an organism *consistent* with infective endocarditis in samples drawn more than 12 hours apart or if three out of four separate cultures are positive and the first and last were drawn at least an hour apart.
- Evidence of endocardial involvement—for example, identification of vegetations or abscesses with echocardiography, new partial dehiscence of a prosthetic valve, new valvular regurgitation.

Minor criteria:

- Predisposition to infective endocarditis—for example, pre-existing heart condition, intravenous drug misuse.
- Fever $\geq 38^{\circ}\text{C}$.
- Vascular phenomena—for example, septic pulmonary infarcts, arterial emboli, mycotic aneurysm, intracranial or conjunctival haemorrhages, Janeway lesions.
- Immunological phenomena: glomerulonephritis, Osler’s nodes, Roth spots, presence of rheumatoid factor.
- Positive blood cultures not meeting major criteria or serological evidence of active infection with an organism consistent with infective endocarditis.
- Echocardiogram consistent with infective endocarditis but not meeting major criteria.

Learning points

- *Lactococcus garvieae* is a rare cause of osteomyelitis.
- The presence of bacteraemia and a prosthetic heart valve requires a high index of suspicion for infective endocarditis.
- The Duke endocarditis service have published criteria for the diagnosis of infective endocarditis using major and minor criteria.

criteria used in the diagnosis of acute rheumatic fever. This yields a high specificity and hence a low chance of a false negative result⁵.

We should like to acknowledge the help of Dr Andrew Mackay MRCP, MRCPATH, MA, MSc, Consultant Microbiologist and Lead Clinician in Pathology, Microbiology Department, Greenwich District Hospital, Vanbrugh Hill, London for his assistance with this report.

- Zlotkin A, Eldar A, Ghittino C, *et al.* Identification of *Lactococcus garvieae* by PCR. *J Clin Microbiol* 1998;36:983–5.
- Collins MD, Farrow AE, Phillips BA, *et al.* *Streptococcus garvieae* sp nov and *Streptococcus plantarum* sp nov. *J Gen Microbiol* 1983;129:3427–31.
- Facklam R, Elliott JA. Identification, classification, and clinical relevance of catalase-negative, Gram-positive cocci, excluding the streptococci and enterococci. *Clin Microbiol Rev* 1995;8:479–95.
- Koneman EW, Allen SD, Janda WM, *et al.*, eds. The Gram positive cocci part II: streptococci, enterococci and the “streptococcus-like” bacteria. *Colour atlas and textbook of diagnostic microbiology*. 5th Ed. Philadelphia: Lippincott-Raven, 1997: 577–649.
- Durak DT, Lukes AS, Bright DK. New criteria for the diagnosis of infectious endocarditis: utilization of specific echographic findings. *Am J Med* 1994;96:200–9.

Phaeochromocytoma unearthed by fluoxetine

A S Kashyap

Abstract

Non-specific noradrenaline reuptake inhibition by high dose selective serotonin reuptake inhibitors, along with catecholamine release from phaeochromocytoma, may lead to a hypertensive paroxysm. This may unmask a clinically silent phaeochromocytoma. Hypertensive paroxysm induced by paroxetine leading to detection of phaeochromocytoma has been reported. The first patient in whom fluoxetine unmasked a phaeochromocytoma is reported.

(*Postgrad Med J* 2000;76:303)

Keywords: selective serotonin reuptake inhibitor; fluoxetine; phaeochromocytoma

Case report

A 29 year old man was prescribed fluoxetine (selective serotonin reuptake inhibitor) 20 mg/day for depression. In view of his poor response the fluoxetine dose was doubled to 40 mg/day. A few days later he presented with paroxysmal attacks of palpitations, nausea, headache, pallor, perspiration, and headache. His other medication was diazepam. On examination the patient was agitated, apprehensive, and had marked peripheral vasoconstriction. His blood pressure varied between 250/140 and 80/30 mm Hg. There was no postural hypotension. Phaeochromocytoma was considered in view of paroxysmal nature of symptoms and fluctuations of blood pressure. Blood pressure recorded earlier was normal. Twenty four hour excretion of noradrenaline was 10.3 nmol/day (normal range 0.06–0.47), adrenaline 32 nmol/day (normal <0.016), and vanillylmandelic acid 134 µmol/day (normal <30).

Magnetic resonance imaging of the abdomen for a suspected pheochromocytoma revealed a 3 cm diameter mass in the right adrenal gland. After surgical removal of the right adrenal gland, histological examination confirmed the presence of a phaeochromocytoma. The patient has been normotensive since then, and has no symptoms.

Discussion

Tricyclic antidepressant drugs lead to increased concentrations of noradrenaline due to inhibited presynaptic reuptake of noradrenaline. Although this effect is beneficial, it can lead to haemodynamic abnormalities, particularly when used with monoamine oxidase

Learning point

Phaeochromocytoma or drug interactions should be suspected when hypertension is detected during treatment with fluoxetine.

inhibitors or in a patient with phaeochromocytoma.¹ Similar haemodynamic effects are seen when selective serotonin reuptake inhibitors are used along with a monoamine oxidase inhibitor.²

A difference in selectivity has been seen in animal studies between various serotonin reuptake inhibitors, regarding dose dependent inhibition of noradrenaline uptake. In humans, such inhibition in therapeutic dosage has not been shown.³

Activity of cytochrome *P*-450 (CYP2D6) determines the rate of fluoxetine metabolism; this differs between poor and prolific metaboliser patients.⁴ Non-specific noradrenaline reuptake inhibition by high dose serotonin reuptake inhibitors, along with catecholamine release from phaeochromocytoma, may explain the haemodynamic abnormalities seen in this patient. Inhibition of serotonin reuptake by platelets may result in increased plasma serotonin concentrations. This in turn leads to higher sensitivity of noradrenaline receptor, thus providing an alternative explanation for paroxysms of haemodynamic abnormalities.⁵

Paroxetine has been implicated in such adverse effects in a patient with pheochromocytoma.⁶ There is no report of fluoxetine leading to such effects until now. Clinicians should suspect phaeochromocytoma or drug interactions when hypertension is detected during treatment with selective serotonin reuptake inhibitors.

- Kaufmann JS. Phaeochromocytoma and tricyclic antidepressants (letter). *JAMA* 1974;229:1282.
- Montastruc JL, Chamontin B, Senard JM, *et al.* Pseudo-phaeochromocytoma in a parkinsonian patient treated with fluoxetine plus selegiline (letter). *Lancet* 1993;341:555.
- Magnussen I, Tonder K, Engbaek F. Paroxetine a potent selective long-acting inhibitor of synaptosomal 5-HT reuptake in mice. *J Neural Trans* 1982;55:217–26.
- Sindrup SH, Brosen K, Gram LF, *et al.* The relationship between paroxetine and sparteine oxidation polymorphism. *Clin Pharmacol Ther* 1992;51:278–87.
- Prichard BN, Smith CC. Serotonin: receptor and antagonist. Summary of symposium. *Clin Physiol Biochem* 1990; 8(suppl 13):120–8.
- Seelen M, de Meijer P, Meinders AE. Serotonin reuptake inhibitor unmasks a phaeochromocytoma. *Ann Intern Med* 1997;126:333.

Department of
Medicine, Armed
Forces Medical
College, Pune, India

Correspondence to:
Dr A S Kashyap, 3-B
Wanowrie Road, Pune
411040, India

Submitted 23 April 1999
Accepted 8 October 1999

Reversible sensorineural hearing loss after non-otological surgery under general anaesthetic

H Pau, D Selvadurai, G E Murty

Abstract

Acute sensorineural hearing loss can occur after both otolaryngological and non-otolaryngological procedures. The mechanism of such hearing loss remains unproved; but nitrous oxide has been implicated and where used, attendants should be aware of its potential damage to hearing. It is essential that patients with sudden hearing loss are identified as soon as possible as the recovery rate had been shown to be higher in those who presented early; and as our case demonstrates, complete recovery is possible. Anaesthetists, non-otolaryngological surgeons, and ward nurses must be aware of this early postoperative complication if appropriate treatment is to be instituted.

(*Postgrad Med J* 2000;76:304–306)

Keywords: surgery; sensorineural hearing loss

Cases of sudden sensorineural hearing loss after non-otological surgical procedures are rare. Most of these were surgical complications after cardiopulmonary bypass, and to date there have been only 29 cases (table 1) of sensorineural hearing loss after non-otological and non-cardiopulmonary surgery. We present a patient who suffered unilateral sensorineural hearing loss after varicose vein surgery under general anaesthetic.

Case report

A 29 year old male smoker presented to the ear, nose and throat department two days after undergoing long saphenous vein stripping and avulsions under general anaesthetic. The general anaesthetic involved induction with intravenous propofol, droperidol, fentanyl, and atropine. Ventilation was via a laryngeal mask airway size 4. Maintenance was achieved by spontaneous ventilation with a gas mixture of 40% oxygen in nitrous oxide and isoflurane vapour. Postoperative pain was controlled by a diclofenac suppository and by infiltrating a solution of 0.5% bupivacaine with adrenaline (epinephrine) to the wounds.

On awakening, he complained of sudden deafness in the right ear and described right sided tinnitus. He was otherwise healthy with no significant past medical history and on no medications. On physical examination he was apyrexial; the cardiovascular system was normal with no carotid bruits and examination of the remaining cranial nerves and peripheral nervous system revealed no abnormalities. The appearance of the pinna, the external acoustic meati, and the tympanic membrane was unremarkable. Rinne's test produced a false negative in the right ear and Weber's test lateralised to the left. A pure tone audiogram showed profound sensorineural hearing deficit in the right ear (fig 1). A full blood count, plasma viscosity, clinical chemistry, and autoantibody screen

Table 1 Twenty nine cases of sensorineural hearing loss after general anaesthetic after distant site surgery and non-cardiopulmonary surgery

Study	No	Surgery	Nitrous oxide used ?	Hearing improved ?
Patterson and Barlett (1979) ⁹	1	Bunionectomy and arthroplasty	Yes	Yes
Tonkin and Fagan (1975) ²²	2	Pyloroplasty and vagotomy	N/A	No
Hockermann and Reimer (1989) ¹⁷	3	Rectal prolapse	Yes	Yes
Journeaux <i>et al</i> (1990) ⁷	4	Adrenalectomy	Yes	N/A
Millen <i>et al</i> (1982) ⁵	5	Mastectomy	N/A	Yes
Millen <i>et al</i> (1982) ⁵	6	Cholecystectomy	N/A	Yes
Millen <i>et al</i> (1982) ⁵	7	Pupilloplasty	N/A	N/A
Jaffe (1967) ²³	8	Thyroidectomy	N/A	N/A
Jaffe (1967) ²³	9	Lysis of small bowel adhesions	N/A	N/A
Jaffe (1967) ²³	10	Cardiac pacemaker implantation	N/A	N/A
Jaffe (1967) ²³	11	Abdominal (unknown)	N/A	N/A
Segal <i>et al</i> (1984) ¹²	12	Vagotomy and pyloroplasty	Yes	Yes
Segal <i>et al</i> (1984) ¹²	13	Inguinal hernia	Yes	Yes
Segal <i>et al</i> (1984) ¹²	14	Lumbar discectomy	Yes	N/A
Velazquez (1992) ²⁶	15	Small bowel resection	No	N/A
Evan <i>et al</i> (1997) ¹⁸	16	Hemithyroidectomy	Yes	No
Evan <i>et al</i> (1997) ¹⁸	17	Total abdominal hysterectomy	Yes	No
Davis <i>et al</i> (1979) ²⁴	18	N/A	Yes	N/A
Man <i>et al</i> (1980) ²⁵	19	Cholecystectomy	Yes	Yes
Guillemin <i>et al</i> (1988) ⁶	20	Urethrotomy	No	No
Guillemin <i>et al</i> (1988) ⁶	21	Bilateral hernia	Yes	No
Guillemin <i>et al</i> (1988) ⁶	22	Gynaecological	Yes	No
Guillemin <i>et al</i> (1988) ⁶	23	Gynaecological	Yes	No
Cox III <i>et al</i> (1997) ¹⁹	24	Nasal	Yes	Yes
Cox III <i>et al</i> (1997) ¹⁹	25	Spinal	No	No
Cox III <i>et al</i> (1997) ¹⁹	26	Spinal	Yes	No
De la Cruz <i>et al</i> (1998) ²⁰	27	Orthopaedic	Yes	No
Belan <i>et al</i> (1994) ²¹	28	Appendicectomy	No	Yes
Present case (1999)	29	Varicose vein surgery	Yes	Yes

N/A = not available.

Department of
Otolaryngology,
Leicester Royal
Infirmary, Leicester,
UK
H Pau
D Selvadurai
G E Murty

Correspondence to:
Mr H Pau, Countess of
Chester Hospital, Health
Park, Liverpool Road,
Chester CH2 1UL, UK
(e-mail: hpau@
globalnet.co.uk)

Submitted 1 June 1999
Accepted 8 October 1999

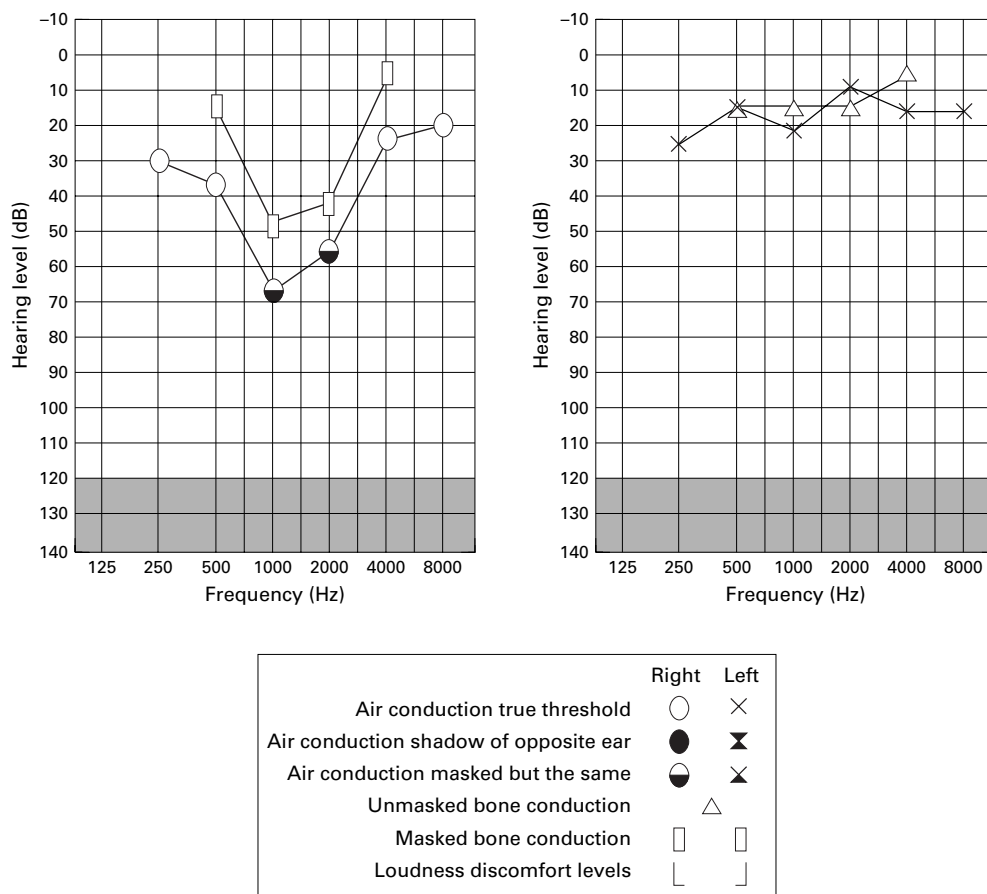


Figure 1 Pure tone audiogram showing profound sensorineural hearing deficit in the right ear.

were normal. Magnetic resonance imaging of the posterior cranial fossa showed no evidence of an acoustic neuroma.

He was admitted for regular carbogen (a mixture of 95% oxygen and 5% carbon dioxide) inhalation hourly for the first 24 hours, intravenous infusion of Dextran 70 solution at a rate of one litre every 12 hours for the first four days, oral flucloxacillin 250 mg four times daily for five days, and oral prednisolone treatment, starting with 60 mg once daily which was later reduced gradually and eventually stopped on the 11th day. Pure tone audiograms were repeated at daily intervals and gradually returned to normal by day 5. He was then discharged from the ward and his follow up pure tone audiogram at six weeks was normal.

Discussion

Box 1 shows a list of some common causes of acute sensorineural hearing loss. However in some cases, the aetiology remains unknown.¹ Idiopathic acute sensorineural hearing loss has been reported to have an incidence of between five to 20 new cases per 100 000 population per year.² Several theories including viral, autoimmune, vascular, embolism, and inner ear membrane rupture have been postulated.

Sensorineural hearing loss has been reported in several specialties after surgery: (1) local surgery including neuro-otological and dental;

(2) cardiopulmonary; and (3) distant site surgery including ophthalmic, gastrointestinal, gynaecological, urological, orthopaedic, and endocrine (table 1).

In neuro-otological surgery, local trauma in acoustic neuroma resection can lead to sudden sensorineural hearing loss.³ In dental procedures, local factors including opening the jaw widely, and the noise intensity and duration of drilling were thought to be responsible.² There have also been a number of cases of sudden hearing loss after cardiopulmonary bypass surgery.⁴⁻⁸

Twenty nine cases of sudden sensorineural hearing loss after distant site surgery including our case are listed in table 1. There were five orthopaedic, one ophthalmic, one cardiac pacemaker implantation, 13 general surgical, one nasal, one urological, three endocrine, and three gynaecological operations. The type of operation in one case was not recorded. Nitrous oxide was administered in 17 of the cases but information regarding the length of the operations were not available. Hearing

Box 1: Common causes of acute sensorineural hearing loss

- Trauma (direct, surgical, barotrauma, or noise)
- Ototoxic drugs
- Acoustic neuromas
- Meniere’s disease
- Multiple sclerosis

improvements were noted in 10 patients, but whether complete reversibility was achieved in these patients was not clearly demonstrated.

The type of anaesthetic has been postulated to have a causative role in these patients. It is well known that nitrous oxide can affect middle ear pressures⁹ and sensorineural hearing loss can be caused by a formation of a perilymph fistula secondary to a ruptured round window. Goodhill¹⁰ and Goodhill *et al*¹¹ postulated an “implosive” and an “explosive” route for rupture of the round window membrane. The former creates rupture by increased pressure in the middle ear and the latter by an increase in the cerebrospinal fluid. Segal *et al* stated that a rupture of the round window by the “implosive” route can take place during induction of anaesthesia with nitrous oxide by outward movement of the tympanic membrane and thus the stapes.¹² However, four of the cases shown in table 1 certainly did not receive nitrous oxide during their operations. The other anaesthetic agents used may act indirectly on the auditory system by altering the general haemodynamics—for example, isoflurane will increase intracranial pressure, propofol at therapeutic dose increases cerebral vascular resistance by 50% and decreases systolic blood pressure by 20%–30%, and fentanyl causes bradycardia and hypotension.¹³ Direct neurotoxic effect on the auditory nerve of any anaesthetic agent has not been reported.

Byl reported on prognostic indicators for sudden hearing loss including age, time from onset to initial presentation, severity of initial hearing loss, the hearing in the opposite ear, tinnitus, and erythrocyte sedimentation rate (ESR).¹ He found that patients under the age of 15 years and over the age of 60 years did not recover as well as the other age groups. He hypothesised that the body’s immune defence mechanisms were not yet developed in the young and, in the aged, were deteriorating. His study confirmed that the sooner a patient is seen, the better the recovery; and a direct relationship between the severity of the initial hearing loss and potential recovery was demonstrated. Patients with below normal pure tone audiogram in the opposite ear proved to have only partial or no recovery. Tinnitus and ESR were regarded to have little prognostic value.

The treatment of acute sensorineural hearing loss is largely empirical due to the number of potential causes. The use of systemic steroids, for example, prednisolone, to combat the inflammatory effect of any viral infection and inhaled carbogen to improve the oxygen tension in the perilymph has been advocated by Fisch,¹⁴ and the management of our case was a modification of this. Dextran 70 has been used as a plasma expander to improve the cochlear circulation.¹⁵ In our case, flucloxacillin was given prophylactically against possible secondary bacterial labyrinthitis. However it is difficult to judge whether a suggested treatment

Learning points

- Acute sensorineural hearing loss can occur after both otolaryngological and non-otolaryngological procedures.
- Patients with sudden hearing loss postoperatively should be identified as soon as possible as the recovery rate had been shown to be higher in those who presented early.

would result in a higher recovery rate than a spontaneous recovery. Wilkins *et al* showed that there was no statistically significant difference between the patients who received treatment and those who did not.¹⁶ Further evaluation of our current methods of treatment is important.

- 1 Byl FM. Sudden hearing loss: eight years’ experience and suggested prognostic table. *Laryngoscope* 1984;94:647–61.
- 2 Farrell RWR, Pemberton MN, Parker AJ, *et al*. Sudden deafness after dental surgery. *BMJ* 1991;303:1034.
- 3 Walsh RM, Murty GE, Punt JAG, *et al*. Sudden contralateral deafness following cerebellopontin angle tumour surgery. *Am J Otol* 1994;15:244–6.
- 4 Arenberg, IK, Allen GW, DeBoer A. Sudden deafness immediately following cardiopulmonary bypass. *J Laryngol Otol* 1972;86:73–6.
- 5 Millen SJ, Toohill RJ, Lehman RH. Sudden sensorineural hearing loss: operative complication in non-otological surgery. *Laryngoscope* 1982;92:613–17.
- 6 Guillemain P, Hausler R, Tassonyi E. Sudden deafness after general surgery. *Schweiz Rundsch Med Prax* 1988;73:578–81.
- 7 Journeaux SF, Greenhalgh, Bull TR. Sudden sensorineural hearing loss as a complication of non-otological surgery. *J Laryngol Otol* 1990;104:711–12.
- 8 Dutton RC, Edmund LH. Measurement of emboli in extracorporeal perfusion systems. *J Thorac Surg* 1973;65:523–30.
- 9 Patterson ME, Barlett PC. Hearing impairment caused by intratympanic pressure changes during general anaesthesia. *Laryngoscope* 1976;86:399–404.
- 10 Goodhill V. Sudden deafness and round window rupture. *Laryngoscope* 1971;81:1462–74.
- 11 Goodhill V, Harris I, Brockman SJ, *et al*. Sudden deafness and labyrinthine window rupture. *Ann Otol Rhinol Laryngol* 1973;82:2–12.
- 12 Segal S, Man A, Winerman I. Labyrinthine membrane rupture caused by elevated intratympanic pressure during general anaesthesia. *Am J Otol* 1984;5:308–10.
- 13 Kaufman L, Taberner PV. *Pharmacology in the practice of anaesthesia*. London: Arnold, 1996: 71, 420–2.
- 14 Fisch U. Management of sudden deafness. *Otolaryngol Head Neck Surg* 1983;91:3–8.
- 15 Hughes GB, Freedman MA, Haberkamp TJ, *et al*. Sudden sensorineural hearing loss. *Update on Otolology and Neurootology, Part II* 1996;29:393–405.
- 16 Wilkins SA, Mattox DE, Lyles A. Evaluation of a “shotgun” regimen for sudden hearing loss. *Otolaryngol Head Neck Surg* 1987;91:653–8.
- 17 Hoehermann M, Reimer A. Hearing loss after general anaesthesia. (A case report and review of literature.) *J Laryngol Otol* 1987;101:1079–82.
- 18 Evan KE, Tavill MA, Goldberg AN, *et al*. Sudden sensorineural hearing loss after general anaesthesia for nonotological surgery. *Laryngoscope* 1997;107:747–52.
- 19 Cox III AJ, Sargent EW. Sudden sensorineural hearing loss following nonotological, noncardiopulmonary bypass surgery. *Arch Otolaryngol Head Neck Surg* 1997;123:994–8.
- 20 De La Cruz M, Bance M. Bilateral sudden sensorineural hearing loss following non-otologic surgery. *J Laryngol Otol* 1998;112:769–71.
- 21 Belan A, Rida A, Hamoud N, *et al*. Bilateral sensorineural hearing loss after general anaesthesia. *Ann Fr Anesth Reanim* 1994;13:400–2.
- 22 Tomkin JP, Fagan P. Rupture of the round window membrane. *J Laryngol Otol* 1975;89:733–56.
- 23 Jaffe BF. Sudden deafness. An otologic emergency. *Archives of Otolaryngology* 1967;86:55–60.
- 24 Davis I, Moore JRM, Lahiri SK. Nitrous oxide and the middle ear. *Anaesthesia* 1979;34:147–51.
- 25 Man A, Segal S, Ezra S. Ear injury caused by elevated intratympanic pressure during general anaesthesia. *Acta Anaesthesiol Scand* 1980;24:224–6.
- 26 Velazquez FZ. Hearing loss after general anaesthesia for cecectomy and small bowel resection. *J Am Assoc Nurse Anesthetist* 1992;60:553–5.