

SHORT REPORTS

A new cause of 'non-responsiveness' in coeliac disease?

J S R Jennings, J I Wyatt, P D Howdle

Abstract

A 42 year old man presented with gluten-responsive coeliac disease and secondary pancreatic insufficiency. Subsequently his symptoms relapsed and repeat small intestinal biopsy showed villous atrophy and infiltration by leukaemic cells, despite continuation of a gluten-free diet. Serious causes of relapse and non-responsiveness in coeliac disease include enteropathy-associated T-cell lymphoma, ulcerative jejunitis and an end-stage hypoplastic mucosa. This is the first report of non-responsiveness due to infiltration by leukaemia.

(*Postgrad Med J* 2000;76:227-229)

Keywords: coeliac disease; villous atrophy; gluten sensitivity; leukaemia

Most patients with coeliac disease respond satisfactorily to a gluten-free diet. A small number fail to respond, either initially or after a period of treatment. There are many causes for this.¹⁻³ In such a situation the diagnosis should be carefully reviewed and a search made for serious causes of the non-responsiveness.

Case report

A 42 year old man presented with a 6-month history of severe watery diarrhoea, dehydration and weight loss of 6.4 kg. He had previously been well, although had always had loose stools since childhood. Investigation revealed a macrocytic anaemia with a low serum folate, and

subtotal villous atrophy on duodenal biopsy (figure, A). Coeliac disease was diagnosed and a gluten-free diet (GFD) was started.

Seven months later a repeat duodenal biopsy showed significant histological improvement (figure, B), suggesting mucosal gluten-responsiveness and supporting the diagnosis of coeliac disease. However, the diarrhoea was still present and failed to improve, despite the subsequent addition of a lactose-free diet, prednisolone and metronidazole. The macrocytic anaemia had progressed, despite folic acid replacement, and splenomegaly had developed. Bone marrow examination revealed chronic myelomonocytic leukaemia (CMML). He required monthly blood transfusions.

At that stage, 18 months after his initial symptoms and 11 months after starting a GFD, he was referred to us for further assessment of his diarrhoea. He still had watery diarrhoea up to 10 times per day. He was lethargic and had lost a further 6.4 kg in weight. There was no rectal bleeding or abdominal pain. On examination he was thin and wasted, with splenomegaly and mild peripheral oedema.

Investigations directed towards finding the cause of his diarrhoea included: haemoglobin 10.6 g/dl, white cell count $34 \times 10^9/l$, platelets $46 \times 10^9/l$, mean corpuscular volume 108 fl, monocytosis and leucoerythroblastic blood film; prothrombin time 23.8 s, albumin 22 g/l, alkaline phosphatase 679 IU/l, vitamins A and E decreased, ferritin 2310 $\mu\text{g/l}$, IgA anti gliadin positive.

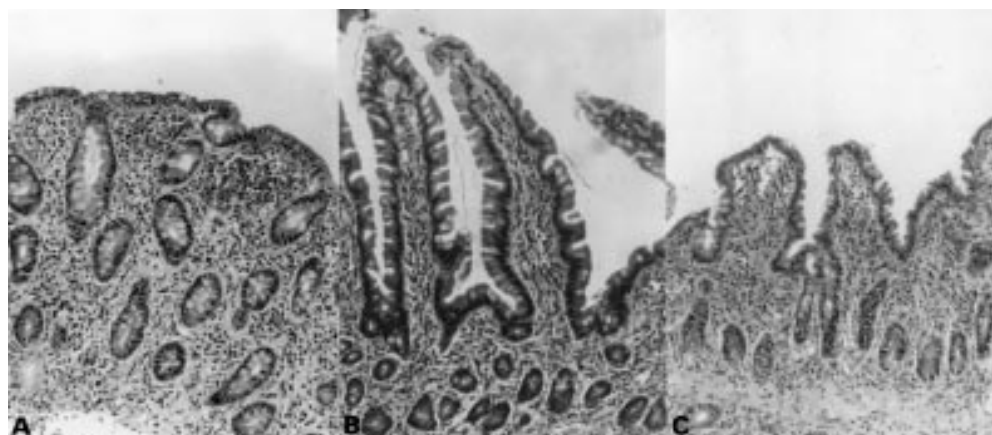


Figure 1 A: original duodenal biopsy illustrating subtotal villous atrophy; B: following a gluten-free diet, small bowel morphology improved to near normal appearance; C: mucosal relapse showing partial villous atrophy with normal enterocytes but an increase in lamina propria cellularity due to involvement with CMML (H + E stain, orig magnification $\times 32$).

St James's University
Hospital, Leeds, UK
Division of Medicine
J S R Jennings
P D Howdle

Department of
Pathology
J I Wyatt

Correspondence to:
Professor P D Howdle,
Division of Medicine,
Clinical Sciences Building, St
James's University Hospital,
Leeds LS9 7TF, UK

Submitted 29 March 1999
Accepted 6 September 1999

Enteroscopy showed ulceration in the second and third parts of the duodenum. Colonoscopy and small bowel enema were normal. Abdominal computed tomography (CT) scan revealed hepatosplenomegaly and low volume inguinal lymphadenopathy. Pancreolauryl test was low at 18.5% (normal >30%). A SeHCAT scan showed severe bile salt malabsorption.

The histology was reviewed. The initial small intestinal biopsy revealed villous atrophy, crypt hyperplasia and increased numbers of lamina propria and intra-epithelial lymphocytes (figure, A). These changes had improved after 7 months on a GFD (figure, B). The current duodenal and jejunal biopsies (18 months after the initial presentation and after 11 months on a GFD) show a relapse in the mucosal injury (figure, C). Infiltrating lymphocytes were seen but appeared atypical. On immunostaining they were confirmed as large monocytes. This suggested early infiltration by CMML cells. Such cells were not found on earlier slides, and these inflammatory changes were not typical of those seen in coeliac mucosa.

Treatment continued with a GFD and vitamin supplements. Pancreatic replacement therapy was commenced.

At 3-month review his symptoms had improved, with considerable resolution of his diarrhoea, and his weight had increased. However, he now required more frequent transfusions and commenced chemotherapy for his CMML.

Eight months later he was re-admitted with further weight loss and malnutrition. He remained IgA anti gliadin positive. Enteroscopy revealed disease progression of the CMML in the intestinal mucosa. One month later total parenteral nutrition was commenced prior to a proposed bone marrow transplant. Unfortunately, he died from a septic episode.

The diagnosis in this case was considered to be:

- Coeliac disease with secondary pancreatic insufficiency
- CMML with subsequent small bowel infiltration
- Consequential mucosal damage and bile salt malabsorption.

Discussion

In the majority of cases of coeliac disease there is an adequate clinical and histological response to a GFD.¹ However, a small proportion of patients (7–8%)² fail to respond to a GFD and the mucosa remains abnormal. Non-responsiveness may be primary, ie, failure to respond from the outset to a GFD, or secondary, when previous response to gluten exclusion relapses.

The commonest cause of failure to respond to a GFD is non-compliance or inadvertent gluten intake. Once the GFD has been formally assessed and a strict diet followed with no histological improvement, other causes should be sought and the diagnosis reviewed.^{3–5}

Serious causes of non-responsiveness should always be considered: a complicating enteropathy-associated T-cell lymphoma, an associated ulcerative jejunitis and an end-stage hypoplastic mucosa.⁶

Learning points

- Coeliac disease is a common cause of malabsorption
- Villous atrophy, crypt hyperplasia and lymphocytic infiltration of the small intestinal mucosa are characteristic
- At least 90% of patients respond clinically and histologically to a gluten-free diet
- Non-response to the diet, either initially or later, may be due to poor dietary compliance, incorrect diagnosis, or a serious complication
- Serious complications include enteropathy-associated T cell lymphoma, ulcerative jejunitis or mucosal hypoplasia

This case raises several important questions. First, what was the evidence for coeliac disease? There was a suggestive history of loose stools from childhood. His symptoms certainly suggested malabsorption and he had a small intestinal mucosal abnormality compatible with coeliac disease. On gluten withdrawal the mucosa had improved considerably by 7 months, but he remained symptomatic. In an adult patient this suggests mucosal gluten-responsiveness and would normally be diagnostic of coeliac disease. This would be compatible with the definition based on small bowel pathology proposed by Booth in 1974⁷ and now generally accepted by gastroenterologists.⁸ However, this patient did not initially improve clinically, he remained IgA anti gliadin positive and therefore did not fulfil the revised ESPGAN criteria⁹ for the diagnosis of coeliac disease, albeit in children. In such cases a clinical remission is required, together with the disappearance of circulating anti gliadin antibodies. If the diagnosis is in doubt, a gluten challenge is recommended. In this case, the patient was too ill to consider a gluten challenge, but also symptomatic improvement did occur with pancreatic replacement therapy. Secondary pancreatic insufficiency in coeliac disease is well-described^{1–3} and therefore we feel that once this had been corrected, together with the initial mucosal response to a GFD, there is good evidence for a diagnosis of coeliac disease, even though by this stage the mucosa was becoming involved by early infiltration with CMML. The persistently positive IgA anti gliadin antibody would not be inconsistent with a diagnosis of coeliac disease. It can take months or even years for the titre to become negative after institution of a GFD and a remaining mucosal abnormality, whatever the cause, is likely to permit continuing excess IgA production.

The second question revolves around the subsequent mucosal relapse with recurrence of weight loss and malabsorption. This was due to the progressive involvement with CMML. It is rare for CMML to involve the gastrointestinal tract.¹⁰ We suggest that the intestinal mucosa was predisposed by coeliac disease to subsequent involvement by CMML. The bile

salt malabsorption suggested extensive mucosal involvement distally by the CMML.

Thus this was a case of coeliac disease with secondary pancreatic insufficiency, where a second mucosal pathology caused further mucosal damage and apparent non-responsiveness.

- 1 Howdle PD, Losowsky MS. Coeliac disease in adults. In: Marsh MN, ed. *Coeliac disease*. Oxford: Blackwell Scientific Publications, 1992; pp49–80.
- 2 Howdle PD. Coeliac disease: therapeutic choices in non-responders to conventional therapy. In: Dobrillo G, Bardhan KD, Stiel A, eds. *Non-responders in gastroenterology*. Verona: Cortina International, 1991; pp129–39.
- 3 O'Mahony S, Howdle PD, Losowsky MS. Management of patients with non-responsive coeliac disease. *Aliment Pharmacol Therapeut* 1996;10:671–8.

- 4 Fine KD, Meyer RL, Lee EL. The prevalence and causes of chronic diarrhoea in patients with coeliac sprue treated with a gluten-free diet. *Gastroenterology* 1997;112:1830–8.
- 5 Gray GM. Persistence of diarrhoea in treated coeliac sprue: refractory disease or another organ's malfunction? *Gastroenterology* 1997;112:2146–7.
- 6 Marsh MN. Gluten, major histocompatibility complex and the small intestine: a molecular and immunobiologic approach to the spectrum of gluten-sensitivity ('celiac sprue'). *Gastroenterology* 1992;102:330–54.
- 7 Booth CC. Definition of adult coeliac disease. In: Hekkens WTJM, Pena AS, eds. *Coeliac disease*. Leiden: Stenfert Kroese, 1974; pp 17–22.
- 8 Ferguson A. Coeliac disease research and clinical practice: maintaining momentum into the twenty first century. *Bailliere's Clin Gastroenterol* 1995;9:395–412.
- 9 Walker-Smith JA, Guandalini S, Schmitz J, et al. Revised criteria for the diagnosis of coeliac disease. *Arch Dis Child* 1990;65:909–11.
- 10 Cornes JS, Jones TG. Leukaemic lesions of the gastrointestinal tract. *J Clin Pathol* 1962;15:305–13.

Sweet's syndrome and subacute thyroiditis

Yoav Kalmus, Susy Kovatz, Lotan Shilo, Gazi Ganem, Louis Shenkman

Abstract

A 63 year old woman developed biopsy documented lesions of acute febrile neutrophilic dermatosis (Sweet's syndrome) one week after the onset of subacute thyroiditis. This is only the second reported case of such an association. The role of cytokines in the development of both subacute thyroiditis and Sweet's syndrome may be the link between these two conditions.

(*Postgrad Med J* 2000;76:229–230)

Keywords: Sweet's syndrome; thyroiditis; cytokines; thyroid

Sweet's syndrome, or acute febrile neutrophilic dermatosis, is a unique dermatological disorder characterised by tender erythematous or violaceous nodules or plaques on the extremities, trunk, and face. Associated signs and symptoms may include fever, leucocytosis, and a raised erythrocyte sedimentation rate. Originally described by the English dermatologist R D Sweet,¹ the disorder was initially considered rare, but with increasing awareness in the past 10 years over 500 cases have been described.

Sweet's syndrome may be the harbinger of malignancy, and many cases have been accompanied or followed by the development of a lymphoproliferative disorder or a solid tumour. While some cases are idiopathic, others have been associated with a variety of disorders. In this report we describe the occurrence of Sweet's syndrome with subacute thyroiditis. This is, to our knowledge, only the second case report of this association. The possible relationship between Sweet's syndrome and subacute thyroiditis is discussed.

Case report

A 63 year old woman was referred to the endocrine clinic because of 10 days of severe neck pain radiating to her ears. She had an unremarkable medical history and had been

healthy until this hospitalisation. On admission her blood pressure was 126/68 mm Hg, pulse 100 beats/min, and temperature 38.7°C. The thyroid gland was enlarged and tender. The remainder of the physical examination was normal, and no signs of hyperthyroidism were present. Aside from a raised erythrocyte sedimentation rate of 140 mm/hour, complete blood count, electrolytes, liver function studies, and urinalysis were all normal. Laboratory evidence of hyperthyroidism was present, with a free thyroxine of 35.28 pmol/l (normal range 13–23) and total triiodothyronine of 2.73 nmol/l (1.3–3.1). The thyroid stimulating hormone concentration was low, <0.005 mIU/ml (0.27–4.2). A technetium scan of the thyroid revealed no uptake of the isotope, and ultrasound examination of the thyroid showed an enlarged gland. These findings were consistent with a diagnosis of subacute thyroiditis, and the patient was treated with aspirin. Seven days later, reddish oedematous papules developed over her forearms, right elbow, and legs. The lesions gradually coalesced to form plaques with delicate scales in the margins.

A skin biopsy was performed, revealing infiltration of the dermis by neutrophils with no evidence of vasculitis, consistent with the diagnosis of acute febrile neutrophilic dermatosis. One week after the initiation of treatment with aspirin the fever resolved, with gradual improvement of both the skin lesions and the subacute thyroiditis. One month after the onset of her symptoms, all lesions had resolved and laboratory studies returned to normal.

Discussion

Sweet's syndrome has been associated with a variety of systemic disorders including haematological malignancies as well as solid tumours. Non-malignant disorders associated with this syndrome include Crohn's disease, ulcerative colitis,² and sarcoidosis.³ In addition, Sweet's syndrome has been seen in association with

Department of
Medicine C, Meir
Hospital, Sapir
Medical Center, Kfar
Saba, and the Sackler
Faculty of Medicine,
Tel Aviv University,
Israel

Y Kalmus
S Kovatz
L Shilo
G Ganem
L Shenkman

Correspondence to:
Dr Y Kalmus, Department
of Medicine C, Meir
Hospital, Kfar Saba 44281,
Israel (e-mail: lsheink@
post.tau.ac.il)

Submitted 18 June 1999
Accepted 6 September 1999

Learning points

- Sweet's syndrome is acute febrile neutrophilic dermatosis.
- Sweet's syndrome is characterised by tender, erythematous, or violaceous nodules or plaques.
- It may be a harbinger of malignancy, either solid tumours or lymphoproliferative disorders.
- It may be seen in a variety of other conditions, including inflammatory bowel disease, sarcoidosis, and infections.
- It may be seen with subacute thyroiditis, possibly as a result of immune mediated cytokine expression.

infectious agents, such as chlamydia, atypical mycobacteria, and *Yersinia enterocolitica*.⁴ Several cases of Sweet's syndrome have resulted from exogenous causes, including exposure to hydralazine and jalapeno peppers.⁵

The association of thyroid disorders and Sweet's syndrome has been reported. Alcalay *et al* first reported the simultaneous occurrence of Sweet's syndrome and subacute thyroiditis in a 63 year old woman, and suggested that both disorders had a possible identical viral aetiology.⁶ Of interest is the fact that the first report, as ours, came from Israel. O'Brien and Darling described a 33 year old woman with hypothyroidism and Sweet's syndrome,⁷ and Nakayama and colleagues documented the

interesting occurrence of Sweet's syndrome with Takayasu's arteritis and Hashimoto's thyroiditis in a 39 year old woman.⁸

The patient described in this report developed classical lesions of Sweet's syndrome one week after the onset of subacute thyroiditis. Although the relationship between these two disorders may have been fortuitous, it is tempting to consider a possible pathogenetic connection. The effect of treatment with interferon alfa on the occurrence of thyroiditis⁹ and the development of dermatological inflammatory disorders, including Sweet's syndrome,¹⁰ hints towards a possible connection via immune mediated side effects of cytokines. However, further cases will have to be reported in order to establish this observation.

- 1 Sweet RD. An acute febrile neutrophilic dermatosis. *Br J Dermatol* 1964;74:349-56.
- 2 Travis S, Innes N, Davies MG, *et al*. Sweet's syndrome: an unusual cutaneous feature of Crohn's disease or ulcerative colitis. The South West Gastroenterology Group. *Eur J Gastroenterol Hepatol* 1997;9:715-20.
- 3 Wilkinson SM, Heagarty AH, English JS. Acute febrile neutrophilic dermatosis in association with erythema nodosum and sarcoidosis. *Clin Exp Dermatol* 1993;18:47-9.
- 4 Von den Driesch P. Sweet's syndrome. *J Am Acad Dermatol* 1994;31:535-56.
- 5 Greer JM, Rosen T, Tschien JA. Sweet's syndrome with an exogenous cause. *Cutis* 1993;51:112-4.
- 6 Alcalay J, Filhaber A, David M, *et al*. Sweet's syndrome and subacute thyroiditis. *Dermatologica* 1987;174:28-9.
- 7 O'Brien TJ, Darling JA. Sweet's syndrome and hypothyroidism. *Australas J Dermatol* 1994;35:91-2.
- 8 Nakayama H, Shimao S, Hamamoto T, *et al*. Neutrophilic dermatosis of the face associated with aortitis and Hashimoto's thyroiditis. *Acta Derm Venereol* 1993;73:380-1.
- 9 Scalzo S, Gengaro A, Boccoli G, *et al*. Primary hypothyroidism associated with interleukin-2 and interferon alpha-2 therapy of melanoma and renal carcinoma. *Eur J Cancer* 1990;26:1152-6.
- 10 Vial T, Descotes J. Immune-mediated side-effects of cytokines in humans. *Toxicology* 1995;105:31-57.

Addison's disease in type 1 diabetes presenting with recurrent hypoglycaemia

Vincent McAulay, Brian M Frier

Abstract

Primary adrenal insufficiency (Addison's disease) often develops insidiously. Although a rare disorder, it is more common in type 1 diabetes mellitus. A 19 year old male with type 1 diabetes and autoimmune hypothyroidism experienced recurrent severe hypoglycaemia over several months, despite a reduction in insulin dose, culminating in an adrenal crisis. Recurrent severe hypoglycaemia resolved after identification and treatment of the adrenocortical insufficiency. In type 1 diabetes, undiagnosed Addison's disease can influence glycaemic control and induce severe hypoglycaemia.

(*Postgrad Med J* 2000;76:230-232)

Keywords: type 1 diabetes; Addison's disease; hypoglycaemia; cortisol

Hypoglycaemia is a common side effect of insulin treatment for type 1 diabetes. However, people with diabetes are susceptible to other causes of spontaneous hypoglycaemia that can affect the non-diabetic population. A patient is described who developed recurrent severe hypoglycaemia associated with underlying glucocorticoid deficiency from undiagnosed Addison's disease.

Case report

A 19 year old male who had developed type 1 diabetes when aged 7 years, was treated with twice daily soluble and isophane insulins. Thyroid microsomal antibodies were present at diagnosis and at the age of 11 years he had developed hypothyroidism requiring thyroxine. There was no family history of autoimmune disease. As a teenager his attendance at the diabetic clinic was erratic and he seldom monitored his

Department of
Diabetes, Royal
Infirmery, Lauriston
Place, Edinburgh
EH3 9YW
V McAulay
B M Frier

Correspondence to:
Dr Frier

Submitted 1 June 1999
Accepted 6 September 1999

Table 1 Features and treatment of Addison's disease

Common symptoms and signs	Laboratory features
Anorexia	Hyponatraemia
Weakness	Hyperkalaemia
Fatigue	Uraemia
Nausea and vomiting	Metabolic acidosis
Postural dizziness	Hypercalcaemia
Weight loss	Normochromic normocytic anaemia
Hypotension	Eosinophilia
Pigmentation	Lymphocytosis
Emergency treatment	Maintenance therapy
Measure plasma cortisol	Primary adrenal failure:
Intravenous hydrocortisone 100 mg with 0.9% saline	Hydrocortisone 15–20 mg am, 5–10 mg at 4 pm <i>or</i>
	Hydrocortisone 15–20 mg am, 5 mg at noon, 5 mg at 4 pm
	<i>and</i>
	Fludrocortisone 0.05–2 mg am
	Secondary adrenal failure:
	Hydrocortisone as above

blood glucose. His overall glycaemic control was poor, with total HbA1c 10.3% in February 1992 (non-diabetic range 5%–8%). Body mass index (BMI) was 19 kg/m² with blood pressure of 120/70 mm Hg (seated). In May 1994, a hypoglycaemia induced seizure followed excessive consumption of alcohol, and 14 days later hypoglycaemic coma, the cause of which was not identified, was treated in hospital. In July 1994, he was detained and charged by the police after driving erratically and dangerously for four miles on the city bypass. In custody he was drowsy, incoherent, and verbally abusive. A venepuncture wound in the antecubital fossa of his right arm raised the suspicion that he may have injected drugs despite a drug screen being negative. However, after four hours his father arrived and immediately recognised that his son's aberrant behaviour was attributable to severe hypoglycaemia; complete recovery occurred rapidly after the ingestion of oral carbohydrate.

At outpatient review later that month, he reported experiencing twice weekly episodes of severe hypoglycaemia despite having reduced his insulin dose. HbA1c was 6.2% (non-diabetic range 4.0%–5.8%). His skin was mildly pigmented, his blood pressure (seated) was 98/58 mm Hg and BMI was 24 kg/m². Although plasma electrolytes were normal, a Synacthen test (intramuscular synthetic adrenocorticotrophic hormone (ACTH), 250 µg) was performed. The basal plasma cortisol concentration was 172 nmol/l but unfortunately the second sample was discarded by the laboratory. The patient did not attend for a repeat Synacthen test and was not seen until November 1994, when he was readmitted with acute vomiting. He was afebrile with a sinus tachycardia and blood pressure was 130/90 mm Hg. Although dizzy on standing, no postural hypotension was demonstrable. Truncal pigmentation and vitiligo on the arms were observed. Hyponatraemia (sodium 129 mmol/l), hyperkalaemia (potassium 5.2 mmol/l), and a modest metabolic acidosis (bicarbonate 14 mmol/l; hydrogen ion 49 nmol/l) were present, random blood glucose concentration was 11.7 mmol/l, and he had ketonuria. Intramuscular synthetic ACTH did not stimulate a rise in plasma cortisol (baseline 253 nmol/l; 30 minutes after injection, 265 nmol/l). Adrenal antibodies were positive. He recovered after intravenous administration of

Learning points

- In patients with type 1 diabetes who develop unexplained recurrent hypoglycaemia, the development of an associated endocrinopathy, such as Addison's disease, should be considered.
- An unexplained reduction of total insulin requirement of more than 15%–20% (in response to recording frequent low blood glucose values) should arouse suspicion of adrenocortical insufficiency. This may precede the clinical features.
- The development of abnormal pigmentation in a patient with type 1 diabetes merits investigation of adrenocortical function with dynamic tests.
- In children or teenagers with type 1 diabetes a clue to underlying Addison's disease is a decline in normal growth velocity.
- The diagnosis of adrenocortical insufficiency in a patient with type 1 diabetes requires simultaneous investigation of thyroid function and thyroid autoantibodies; biochemical evidence of hypothyroidism may resolve after glucocorticoid replacement.
- Plasma electrolyte abnormalities are not invariable in adrenal insufficiency until an advanced stage; 20%–30% of patients do not have hyponatraemia or hyperkalaemia at any time.

saline and hydrocortisone and was treated thereafter with oral hydrocortisone and fludrocortisone. His insulin dose returned to the pre-morbid level and no further severe hypoglycaemia occurred. At a subsequent court hearing, the driving charges were dismissed after presentation of medical evidence that unpredictable hypoglycaemia may be associated with undiagnosed Addison's disease.

Discussion

This patient with insulin dependent diabetes, who previously had prolonged suboptimal glycaemic control, developed recurrent severe hypoglycaemia without any change in treatment or physical activity. He was presumed to have increased insulin sensitivity secondary to underlying glucocorticoid deficiency, the treatment of which restored his usual total insulin requirement and abolished the hypoglycaemia.

Addison's disease is rare, with a reported incidence in the UK of about 5 cases/million population/year¹ and a prevalence of 110 per million, although it is at least five times more common in the diabetic population.² It often presents with non-specific features (see table 1), making the diagnosis elusive. An association with type 1 diabetes is well recognised with 10%–18% of patients with Addison's disease also having insulin dependent diabetes.^{3,4} However, the prevalence of Addison's disease in type 1 diabetes is reported to be lower at 1.2%.⁵ Diabetes precedes the development of adrenocortical insufficiency in most patients,

and often presents at a young age.⁶ Addison's disease in patients with type 1 diabetes usually has an autoimmune aetiology, and the present patient had pluriglandular endocrine deficiencies. The association of Addison's disease with thyroiditis is known as Schmidt's syndrome and is a common manifestation of type 2 polyglandular autoimmune syndromes.⁷

Hypoglycaemia is not a common presenting feature of Addison's disease, either in patients with type 1 diabetes or in the non-diabetic population, although it has been reported to be associated both with primary and secondary glucocorticoid deficiencies,^{8,9} and is considered to be caused by enhanced insulin sensitivity. Diminished secretion of other counter-regulatory hormones may also contribute and a combination of cortisol and growth hormone deficiencies has been associated with profound hypoglycaemia in diabetic patients treated with insulin.^{8,9}

The much more common factors of excessive insulin, insufficient carbohydrate, and exercise that precipitate or predispose to acute hypoglycaemia in patients with type 1 diabetes, must not be overlooked despite evidence of glucocorticoid deficiency. Although in the present case contributory factors such as excessive alcohol consumption and delayed ingestion of meals could be identified in a few of the episodes of severe hypoglycaemia, the recurrence of severe hypoglycaemia in conjunction with a decline in total insulin dosage was suggestive of another underlying pathogenetic problem, unassociated with the patient's self management of his diabetes.

The classical features of adrenal failure such as anorexia, lethargy, and weight loss with deranged plasma electrolytes, were not prominent in the present case until the patient presented in adrenal crisis, although signs of hypotension, hyperpigmentation and vitiligo (which occurs in 4%–17% of patients with autoimmune Addison's disease) had been

noted. The decreasing insulin requirement with a concomitant, but unexplained, improvement in glycaemic control heralded the change in endocrine status. This highlights the importance of maintaining an awareness that patients with established autoimmune disorders are at risk of developing other endocrinopathies.

A defence of automatism associated with insulin induced hypoglycaemia in people with insulin treated diabetes is usually not accepted by the courts, although evidence of contemporaneous hypoglycaemia may mitigate any penalty imposed. The law considers that the individual is responsible for allowing hypoglycaemia to occur (through careless or reckless behaviour),¹⁰ even though many episodes of hypoglycaemia have no obvious precipitating factor. However, in the present case the hypoglycaemia could be considered to be truly "spontaneous" as it resulted from an unrecognised underlying endocrine disorder which directly influenced insulin sensitivity and blood glucose concentrations, and driving charges were dismissed.

- 1 Kong M-F, Jeffcoate W. Eighty-six cases of Addison's disease. *Clin Endocrinol (Oxf)* 1994;41:757–61.
- 2 MacCuish AC, Irvine WJ. Autoimmunological aspects of diabetes mellitus. *Clin Endocrinol Metab* 1975;4:435–71.
- 3 Nerup J. Addison's disease. Clinical studies: a report of 108 cases. *Acta Endocrinol (Copenh)* 1974;76:127–41.
- 4 Irvine WJ, Barnes EW. Adrenal insufficiency. *Clin Endocrinol Metab* 1972;1:549–94.
- 5 Zelissen PM, Bast EJ, Croughs RJ. Associated autoimmunity in Addison's disease. *J Autoimmun* 1995;8:121–30.
- 6 Papadopoulos KI, Hallengren B. Polyglandular autoimmune syndrome type II in patients with idiopathic Addison's disease. *Acta Endocrinol (Copenh)* 1990;122:472–8.
- 7 Carpenter CCJ, Solomon N, Silverberg SG, et al. Schmidt's syndrome (thyroid and adrenal insufficiency): a review of the literature and a report of fifteen new cases including ten instances of coexistent diabetes mellitus. *Medicine* 1964;43:153–80.
- 8 Sakane N, Yoshida T, Yoshioka K, et al. Severe hypoglycaemia and type 1 diabetes with isolated ACTH deficiency. *Diabetes Care* 1995;18:1621–2.
- 9 Hardy K, Burge MR, Boyle PJ, et al. A treatable cause of severe hypoglycaemia. *Diabetes Care* 1994;17:722–4.
- 10 Maher G, Frier BM. Hypoglycaemia and criminal responsibility. In: Frier BM, Fisher BM, eds. *Hypoglycaemia and diabetes: clinical and physiological aspects*. London: Edward Arnold, 1993: 380–6.

Galactorrhoea and pituitary mass: a typical prolactinoma?

Michael Brändle, Christoph Schmid

Abstract

A 21 year old woman presenting with galactorrhoea, hyperprolactinaemia, and a pituitary mass on magnetic resonance imaging (MRI) is described who was referred to us before planned pituitary surgery. Although a thorough history did not suggest hypothyroidism, laboratory studies revealed profound primary hypothyroidism. At that time, pituitary MRI showed homogeneous enlargement of the pituitary gland consistent with pituitary hyperplasia due to primary hypothyroidism. With thyroid hormone replacement

therapy the galactorrhoea resolved, concentrations of prolactin and thyroid hormones returned to normal, and the pituitary shrunk to normal size within two months. This case illustrates that primary hypothyroidism can present only with galactorrhoea and pituitary mass, and should therefore be considered in the differential diagnosis of hyperprolactinaemia and pituitary enlargement.

(*Postgrad Med J* 2000;76:232–234)

Keywords: primary hypothyroidism; galactorrhoea; pituitary mass

Division of Endocrinology and Diabetes, Department of Internal Medicine, University Hospital Zürich, 8091 Zürich, Switzerland
M Brändle
C Schmid

Correspondence to:
Dr Brändle (e-mail:
ndobraem@usz.unizh.ch)

Submitted 27 April 1999
Accepted 27 September 1999

Galactorrhoea is a common symptom of hyperprolactinaemia in premenopausal women. The most frequent causes of pathological hyperprolactinaemia are pituitary tumours and drugs with dopamine antagonist properties, whereas less common aetiologies include hypothalamic disease, chronic renal failure, liver cirrhosis, breast disease, chest wall trauma, spinal cord lesion, and primary hypothyroidism.

However, in patients with primary hypothyroidism galactorrhoea is a rare feature compared with the typical symptoms such as fatigue, weight gain, cold intolerance, constipation, dry skin, and myopathy.

We describe a patient initially presenting with galactorrhoea and pituitary enlargement, but without any other characteristic symptoms suggesting primary hypothyroidism.

Case report

A 21 year old woman (born in 1977) had a two year history of increasing galactorrhoea. Six months earlier, she had started a hormonal contraception with a triphasic combination of oestrogens (ethinyloestradiol) and progestins (gestodene). In the past, her menstrual cycle had been normal and regular, since menarche at the age of 13 (in 1990). In October 1997 mild hyperprolactinaemia (prolactin 37.7 µg/l) was found and magnetic resonance imaging (MRI) revealed a 8 mm sized pituitary tumour.

In January 1998, she was admitted to our outpatient endocrinology division for preoperative evaluation of the pituitary tumour and galactorrhoea. She complained of galactorrhoea cyclically increasing before menstrual bleeding. She did not suffer any other symptoms nor take any medication except for the oral contraceptive. She went to a teacher training college and was fit. Physical examination revealed a healthy appearing woman of normal weight (59.5 kg) and height (169 cm) with a regular heart rate of

64 beats/min, a blood pressure of 132/88 mm Hg, normal voice, skin, hair, nails, and thyroid gland. Bilateral expressible galactorrhoea was present. The ankle jerks showed a markedly delayed relaxation phase. Haematological tests revealed a low haemoglobin of 113 g/l (normal range 123–158 g/l) and packed cell volume of 0.353 (0.37–0.47). Blood chemistry showed raised concentrations of total cholesterol of 9.3 mmol/l and total creatine kinase activity of 917 U/l (<150 U/l). The endocrinological tests confirmed hyperprolactinaemia (prolactin 118 µg/l, normal range 2–20) and disclosed primary hypothyroidism with low free thyroxine (5.1 pmol/l, normal range 8.5–19.0), low free triiodothyronine (1.5 pmol/l, normal range 3.5–6.2), and markedly increased thyroid stimulating hormone (TSH) (506.75 mU/l, normal range 0.1–4.0). Thyroglobulin and thyroid peroxidase antibodies were raised, suggesting autoimmune thyroid disease.

Pituitary MRI performed at that time showed homogeneous enlargement of the pituitary gland (12 × 10 mm in diameter) with a convex suprasellar expansion and without any signs of a focal lesion, consistent with pituitary hyperplasia due to primary hypothyroidism (fig 1A).

The patient was advised to stop taking the oral contraceptive, and thyroxine replacement was initiated with 50 µg levothyroxine daily for two weeks and then increased to 100 µg daily. One month later the galactorrhoea resolved, and spontaneous regular menstrual bleeding returned after six weeks. In April 1998, upon two months of thyroxine substitution, free thyroxine (16.4 pmol/l), free triiodothyronine (4.4 pmol/l) and prolactin (12.7 µg/l) concentrations were normal, and TSH was only slightly raised (7.66 mU/l). On repeat MRI of the sellar region, the volume of the pituitary had shrunk to normal size (8.5 × 9 mm in diameter; fig 1B).

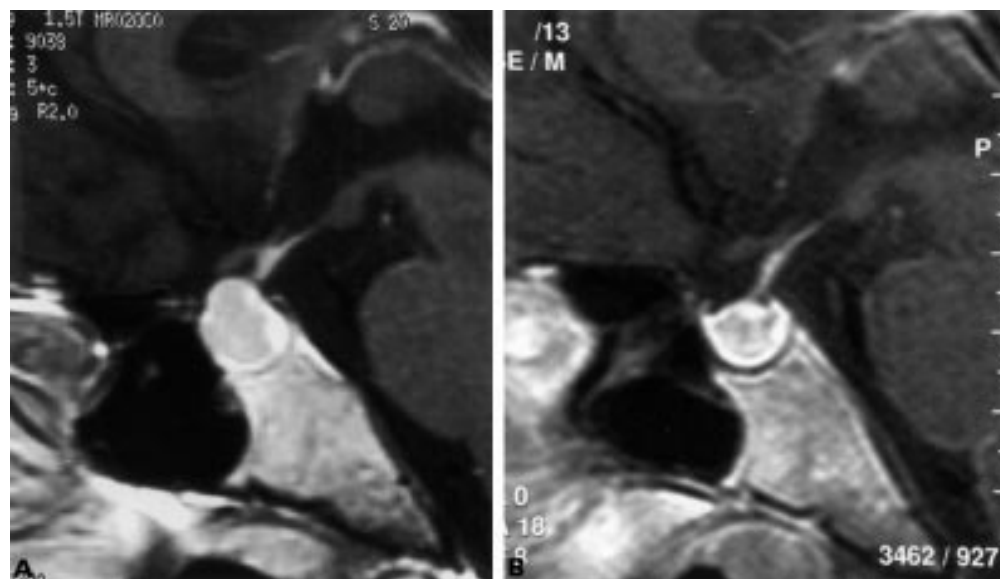


Figure 1 Mid-sagittal T1 weighted magnetic resonance imaging of the sellar region: (A) on 12 February 1998, showing homogeneous enlargement of the pituitary gland with convex suprasellar expansion, measuring 12 mm in height, without any signs of a focal lesion and (B) on 14 April after two months of thyroxine replacement showing significant shrinkage of the pituitary gland to normal configuration and height, 8.5 mm.

Discussion

The presentation of our patient with galactorrhoea, hyperprolactinaemia, and a pituitary mass suggested, at first glance, the diagnosis of prolactinoma rather than primary hypothyroidism. Hypothyroidism can cause a broad range of signs and symptoms. Manifestation with galactorrhoea is rare, but well known.¹⁻³ Prolactin concentrations greater than 25 µg/l were found in about 10% of patients with hypothyroidism.⁴ Hyperprolactinaemia results from increased thyrotrophin releasing hormone (TRH) production and increased sensitivity of lactotrophs to TRH.⁵

Exogenous oestrogen supply by oral contraceptives may favour hyperprolactinaemia as well as galactorrhoea by actions at both the pituitary and the breast level.^{5,6} In addition, hypothyroidism slows the metabolism of oestrogen and thereby may further increase the effect of ethinyloestradiol. Profound hypothyroidism often causes hypogonadism with amenorrhoea. In states of oestrogen deficiency, hyperprolactinaemia rarely causes galactorrhoea. Galactorrhoea typically occurs in hypothyroid patients with hyperprolactinaemia and normal or high concentrations of oestrogens, especially during hormonal contraception and after pregnancy.⁷

It is known that patients with longstanding primary hypothyroidism may have pituitary enlargement visible on MRI or computed tomography.⁸ This enlargement is related to chronically decreased circulating thyroid hormones and subsequent hypersecretion of TSH and thyrotroph cell hyperplasia. The pituitary hyperplasia could be mistaken for a pituitary tumour, especially prolactinoma, and patients could undergo unnecessary operation with considerable complications.^{3,9}

Thyroxine replacement for primary hypothyroidism resolves galactorrhoea and amenorrhoea, causes the prolactin concentrations to return to normal, and results in rapid

Learning points

- Profound biochemical hypothyroidism may exist in apparently healthy individuals with minimal clinical evidence of hypothyroidism.
- Not every patient with galactorrhoea, hyperprolactinaemia, and a pituitary mass has a prolactinoma.
- Hypothyroidism should always be considered in the differential diagnosis of hyperprolactinaemia and in the differential diagnosis of pituitary enlargement.

regression of pituitary size (fig 1B).^{5,8,10} Thus, it is important to check thyroid function in all patients with hyperprolactinaemia as well as in patients with pituitary enlargement before the diagnosis of prolactinoma is made. Other secondary causes of hyperprolactinaemia should also be excluded.

- 1 Lindsay RS, Toft AD. Hypothyroidism. *Lancet* 1997; **349**:413-7.
- 2 Edwards CR, Forsyth IA, Besser GM. Amenorrhoea, galactorrhoea, and primary hypothyroidism with high circulating levels of prolactin. *BMJ* 1971; **iii**:462-4.
- 3 Levine M, Koppelman MC, Patronas N, et al. Amenorrhoea-galactorrhoea due to occult hypothyroidism. *South Med J* 1986; **79**:183-4.
- 4 Honbo KS, van-Herle AJ, Kellett KA. Serum prolactin levels in untreated primary hypothyroidism. *Am J Med* 1978; **64**:782-7.
- 5 Molitch ME. Pathologic hyperprolactinemia. *Endocrinol Metab Clin North Am* 1992; **21**:877-901.
- 6 Luciano AA, Sherman BM, Chapler FK, et al. Hyperprolactinemia and contraception: a prospective study. *Obstet Gynecol* 1985; **65**:506-10.
- 7 Bayliss PF, Hoff W van't. Amenorrhoea and galactorrhoea associated with hypothyroidism. *Lancet* 1969; **ii**:1399-400.
- 8 Wolansky LJ, Leavitt GD, Elias BJ, et al. MRI of pituitary hyperplasia in hypothyroidism. *Neuroradiology* 1996; **38**:50-2.
- 9 Khalil A, Kovacs K, Sima AA, et al. Pituitary thyrotroph hyperplasia mimicking prolactin-secreting adenoma. *J Endocrinol Invest* 1984; **7**:399-404.
- 10 Sarlis NJ, Brucker-Davis F, Doppman JL, et al. MRI-demonstrable regression of a pituitary mass in a case of primary hypothyroidism after a week of acute thyroid hormone therapy. *J Clin Endocrinol Metab* 1997; **82**:808-11.

Advanced testicular cancer presenting with phlegmasia cerulea dolens

C Mulatero, G Brogan, R T D Oliver

Abstract

A case of fulminating deep venous thrombosis secondary to invasion of the inferior vena cava is described in a 45 year old man presenting with a germ cell tumour. Despite aggressive supportive care and emergency chemotherapy his late presentation caused his death. The case highlights the necessity for increased public education of the attendant risks in delayed presentation with a testicular lump.

(*Postgrad Med J* 2000; **76**:234-236)

Keywords: phlegmasia cerulea dolens; testicular carcinoma

Medical Oncology
Department,
St Bartholomew's
Hospital, London, UK
C Mulatero
G Brogan
R T D Oliver

Correspondence to: Dr Clive Mulatero, Department of Medical Oncology, Christie Hospital and Holt Radium Institute, Wilmslow Road, Manchester M20 4BX, UK

Submitted 8 January 1999
Accepted 6 September 1999

The results of treating germ cell cancer continue to improve. A recent review at the Men's Cancer Unit at the Royal Hospitals Trust showed 97% overall survival in a cohort treated from 1989 to 1994.¹ There was a lack of major impact of delay on survival in this cohort. In patients delaying initial presentation by less than three months survival was 98% and in those who delayed for greater than 12 months 94% still survived. This leads some to question the current practice requiring all testicular masses to be considered as an emergency. As two thirds present with delay of more than two months there is disagreement

over the necessity for surgery on the next operating list. It is obvious in the minority of patients with choriocarcinoma, a condition that can be screened for on the basis of a positive urinary pregnancy test,² that delay should be avoided as it can double every six days and kill in six weeks. However, experiencing a patient who died within a week of first presentation with venous infarction induced gangrene and rhabdomyolysis induced renal failure is a reminder of the fatal problems that can develop from delay in less malignant cases.

Case report

A 45 year old man presented to the casualty department describing a two week history of painless left testicular swelling and a two day history of leg muscle cramp, weakness, stiffness, and oedema. He had attended his general practitioner the previous day but he had not performed a general or testicular examination. The patient had no past history of hypertension, renal disease, scrotal surgery, or testicular trauma. He lived in a separate unit within a house with his uncle. Three years previously he had lost both parents and shortly afterwards he was made redundant from work as a security guard. He had become moderately reclusive but did not drink alcohol.

On examination he was drowsy but rousable. He was afebrile and had no palpable lymphadenopathy. There was a large indistinct central mass in his abdomen and a 10 cm² firm, non-tender scrotal swelling. Both legs were grossly oedematous with peripheral discoloration, reduced capillary refill, and impalpable peripheral pulses.

A urinary pregnancy test was positive. Ultrasound examination revealed a right hydronephrotic kidney, and bilateral femoral vein thromboses secondary to the large abdominal mass. After resuscitation the patient was transferred for urgent right nephrostomy as his serum urea concentration measured 15.4 mmol/l with a creatinine of 419 mol/l. Overnight he became oliguric and his temperature rose to 38°C.

The next morning blood investigations showed a rising urea concentration of 21.3 mmol/l and creatinine 541 mol/l, with urate 902 mmol/l, lactate dehydrogenase 1642 IU/l, creatine kinase 53 IU/l, and β human chorionic gonadotrophin 530 U/l. Doppler pulses were absent in the lower limbs and a diagnosis of phlegmasia cerulea dolens was made: a fulminating form of deep vein thrombosis.³ Computed tomography revealed no abnormalities within the chest, liver, or spleen. A small left kidney was noted. The right kidney was atrophic and compatible with obstruction. There was a large heterogeneous mass measuring 10 cm² overlying the bifurcation of the inferior vena cava extending into the right pelvis, infiltrating the left iliac vein and inferior vena cava (fig 1). The venous thrombosis was secondary to venous compression and invasion.

The patient became hypotensive and anuric despite insertion of a right nephrostomy tube. His renal failure was initially treated medically with dopamine. The sepsis was treated with intravenous antibiotics. An intravenous heparin infusion was started in view of the venous thrombosis. He received high dose dexamethasone to reduce peritumoral inflammation and allopurinol to counteract potential tumour lysis syndrome. Emergency chemotherapy was given in an attempt to shrink the tumour mass and relieve pressure on the inferior vena cava. Because of the poor renal function he received a small dose of carboplatin (100 mg), etoposide (250 mg), and subcutaneous bleomycin (15 units).

His condition deteriorated progressively and haemodialysis started on the third day. Despite these measures ischaemia and gangrene progressed rendering surgical salvage impossible.⁴ Further dialysis was withheld and he died six days after his initial presentation.

Discussion

This patient's reclusive personality undoubtedly resulted in delayed presentation. He consulted his general practitioner on the day before presenting to hospital, and had he been diagnosed his life might have been saved as renal failure due to rhabdomyolysis is reversible if the cause is resolved.

Vena caval invasion is a well recognised but relatively rare complication of testicular tumours. Vena caval invasion more frequently occurs with right sided tumours, as the sentinel lymph node on this side is usually the intercaval node at the level of the right renal artery.⁵ Such patients may present with pulmonary emboli, although thrombus in the vena cava can extend and cause the Budd-Chiari syndrome with hepatorenal failure. The iliac node involvement in this patient is more commonly seen after scrotal surgery. Literature review failed to identify a report of phlegmasia cerulea dolens in testis cancer patients. In our records of more than 300 cases with metastatic testis cancer there are six cases with vena caval invasion and one with Budd-Chiari syndrome. Despite hepatorenal failure that patient responded to low dose chemotherapy similar to that given in this case and proceeded

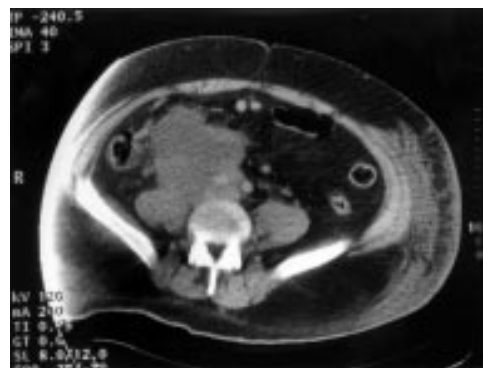

Figure 1 Contrast enhanced computed tomography immediately caudal to the aortic bifurcation.

Learning points

- Phlegmasia cerulea dolens is a rare complication of testicular carcinoma.
- Continued patient education of the need for early presentation with testicular masses is necessary.

to conventional treatment two weeks after resolution of the thrombus.² He is alive at 10 year follow up.

This case illustrates that there is still a need for public education about testis cancer as late presentation may reduce survival. A critical

lesson for all health care professionals is to be vigilant for testicular cancer in men with non-specific symptoms.

- 1 Oliver RT, Ong J, Blandy JP, *et al*. Testis conservation studies in germ cell cancer justified by improved primary chemotherapy response and reduced delay, 1978–1994. *Br J Urol* 1996;**78**:119–24.
- 2 Caulfield MJ, Dilkes MG, Iles RK, *et al*. Rapid diagnosis of testicular choriocarcinoma by urinary pregnancy tests [letter]. *Lancet* 1990;**335**:1230.
- 3 Mahorner H. Diagnosis and treatment of phlegmasia alba dolens and phlegmasia cerulea dolens. *Am Surg* 1968;**34**:210–2.
- 4 Hood DB, Weaver FA, Modrall JG, *et al*. Advances in the treatment of phlegmasia cerulea dolens. *Am J Surg* 1993;**166**:206–10.
- 5 Husband JE, Bellamy EA. Unusual thoracoabdominal sites of metastases in testicular tumors. *AJR Am J Roentgenol* 1985;**145**:1165–71.