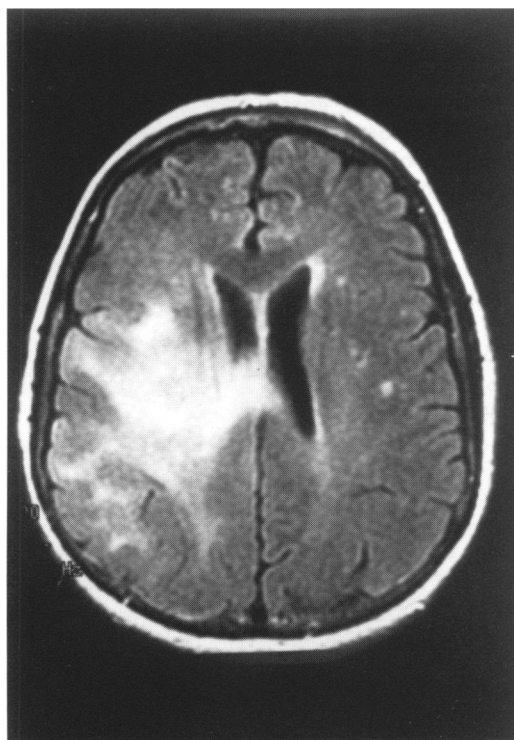


Hemiparesis following influenza vaccination

Nithianandam Selvaraj, Majaz Moonis, Paula Ravin

A 72-year-old woman presented with subacute, non-progressive weakness of her left hand 2 weeks after receiving an influenza vaccination. Her spouse had noticed that she was walking unsteadily, with a tendency to fall to the left side. She also drooled from the left angle of the mouth. She denied any headache, fever, neck pain, alteration in consciousness or seizures. She had no other medical illnesses. She worked as a hair stylist and had stopped smoking 27 years ago. She took no medications.

On clinical examination, she was afebrile. Her higher mental functions including speech and language were normal. Her left lower face was weak. Other cranial nerves were normal. Her left arm strength was (MRC) 4-/5 with her left leg being 4+/5. She had normal strength in her right side. Deep tendon reflexes were 3+ in her left arm and leg, and 2+ on the right side. Babinski's sign was present on the left side. She had no sensory loss and her cerebellar functions were intact. There were no signs of meningeal irritation. Her other systems examination was normal. Brain magnetic resonance imaging (MRI) was carried out (figure 1).



Questions

- 1 What is the clinical diagnosis?
- 2 What is the differential diagnosis after the initial MRI?
- 3 What is the management?

Department of
Neurology, University
of Massachusetts
Medical Center, 55
Lake Avenue North,
Worcester, MA
01655-0318, USA
N Selvaraj
M Moonis
P Ravin

Accepted 10 March 1998

Figure 1 Brain MRI on admission

Answers

QUESTION 1

The subacute onset of left hemiparesis with face = arm > leg weakness points to a lesion involving the right cerebral cortex in the distribution of the middle cerebral artery. The subacute onset of symptoms points to an aetiology other than a stroke. The symptoms appeared to be non-progressive and hence do not suggest a progressive lesion-like tumour.

QUESTION 2

The MRI obtained on admission (figure 1) shows widespread areas of T2 hyperintensity in the right temporal and parietal lobes. There is a mild degree of associated mass effect and this extends into the basal ganglia and the corpus callosum. The lesion does not enhance with gadolinium.

A cerebrovascular event is unlikely, as the lesion involves two vascular territories. The posterior cerebral arteries and the middle cerebral arteries supply the temporal lobes and the parietal lobes, respectively. Although embolic strokes can affect more than one vascular territory, this patient does not have any risk factors for embolic strokes. Moreover, the mode onset of symptoms does not suggest a vascular event.

The nonenhancement of this lesion goes against a tumour, although low-grade glioma can, on occasion, have a preserved blood-brain barrier. The corpus callosal involvement is more suggestive of a demyelinating disease, although 'butterfly' gliomas can involve the corpus callosum. The nonprogressive clinical course and the relatively preserved neurological status make herpes encephalitis very unlikely. A demyelinating disease should also be considered in this patient, particularly with the history of an influenza vaccination preceding the onset of symptoms.

QUESTION 3

Cerebrospinal fluid analysis showed no white cells or red cells. The protein and sugar levels were also normal. The cytology was negative for abnormal or malignant cells. The myelin basic protein level was normal. Cultures for bacteria, fungi and viruses were negative. Other laboratory investigations, including serum chemistry and a complete blood count, were all normal. The chest X-ray did not reveal any abnormalities.

The patient's motor strength improved on steroids. She did not develop any new neurological signs during her hospital stay. A repeat brain MRI was scheduled and she was followed closely as an outpatient.

Two weeks later, her right arm strength deteriorated and her arm became completely weak. The repeat MRI (figure 2) showed extensive oedema throughout the right temporal and parietal lobes. There was a well-defined, round mass, measuring about 3 cm, centered in the white matter adjoining the right lateral ventricle. There was nonhomogenous enhancement throughout this mass, which extended into the lateral corpus callosum. This

Learning points

- post-influenza vaccine encephalomyelitis is rare and the association of acute disseminated encephalomyelitis with influenza vaccine is controversial
- both demyelinating disease and 'butterfly glioma' can involve the corpus callosum
- non-enhancement on MRI may be seen with a low-grade glioma and in steroid-treated patients with glioblastoma, giving a falsely benign appearance

MRI was highly suggestive of a tumour. A stereotactic brain biopsy confirmed the diagnosis of glioblastoma.

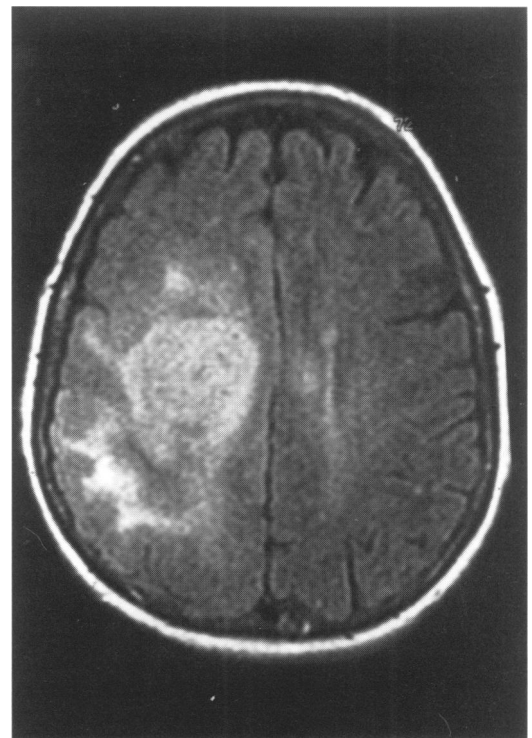


Figure 2 Repeat brain MRI

Discussion

Post-vaccination encephalomyelitis has been well described with rabies vaccine.¹ Case reports of encephalomyelitis following other vaccines such as pertussis, rubella, diphtheria and measles are also known. Randomised, placebo-controlled trials have shown that severe side-effects due to influenza vaccine are rare and that it is quite safe for use in the elderly population.^{2,3}

This patient was particularly interesting as the initial MRI was not quite consistent with a tumour. The nonenhancement of the lesion, along with other features such as involvement of the corpus callosum in the setting of a preceding vaccination, made it difficult to justify

an invasive diagnostic procedure. The patient is currently undergoing radiation therapy and chemotherapy is planned.

Final diagnosis

Glioblastoma multiforme.

Keywords: glioblastoma multiforme; influenza vaccine

- 1 Swamy HS, Shankar SK, Chandra PS, *et al.* Neurological complications due to beta-propiolactone (BPL)-inactivated antirabies vaccination. *J Neurol Sci* 1984;63:111–28.
- 2 Nichol KL, Margolis KL, Lind A, *et al.* Side effects associated with influenza vaccination in healthy working adults: A randomized, placebo-controlled trial. *Arch Intern Med* 1996;156:1546–50.

- 3 Govaert TM, Dinant GJ, Aretz K, *et al.* Adverse reactions to influenza vaccine in elderly people: randomized double blind controlled trial. *BMJ* 1993;307:1213–4.

Acute testicular pain

**Department of
Surgery, Wrexham
Maelor Hospital,
Wrexham LL13 7TD,
UK**

N Kumar
M K H Crumplin

Correspondence to
Dr N Kumar, Clinical Fellow
in Transplantation, London
Health Sciences Center, PO
Box 5339, 339 Windermere
Road, London, Ontario N6A
5A5, Canada

Accepted 23 April 1998

N Kumar, M K H Crumplin

A 15-year-old boy presented with history of acute pain in the left side of the scrotum radiating to the lower abdomen. He had no history of trauma, urinary symptoms or vomiting. On examination he was afebrile and the left side of the scrotum was red, swollen and tender. There was no tenderness on the right testis or epididymis. There was mild left iliac fossa tenderness with no rebound tenderness or guarding. His bowel sounds were normal.

Questions

- 1 What is the differential diagnosis?
- 2 How would you manage the patient?