

Classic diseases revisited

Langerhans cell histiocytosis (histiocytosis X)

King-Yin Lam

Summary

There has been a renewed interest in Langerhans cell histiocytosis in recent years due both to advances in basic research and to improvements in diagnostic and treatment approaches. In this article, we review the various aspects of the disease and the potential implications of these recent scientific researches for our understanding and management of the disorder.

Keywords: Langerhans cell histiocytosis, histiocytosis X

Classification of histiocytoses

- Class I Langerhans cell histiocytosis (LCH)
- Class II haemophagocytic lymphohistiocytosis
- Class III malignant disorders of histiocytes:
 - acute monocytic leukaemia (French–American–British classification M5)
 - malignant histiocytosis
- Class IV other histiocytosis (sinus histiocytosis, massive lymphadenopathy, xantho-granuloma, reticulohistiocytoma)

Box 1

Pathogenesis of LCH

- a lack of viral aetiology
- various cytokines involved
- cellular adhesion molecules play a role
- rare familial cases
- monoclonality demonstrated
- aberrant immunophenotypes and expression of proliferative markers

Box 2

In 1953, Lichtenstein introduced the unifying term ‘histiocytosis X’ to embrace several previous eponyms, including eosinophilic granuloma, Letterer-Siwe disease and Hand-Schuller-Christian disease.¹ In 1987, a more prominent designation, Langerhans cell histiocytosis (LCH), was recommended to replace histiocytosis X.² The term is more appropriate as it reflects the fact that the Langerhans cell is the main cell involved in these several diseases. The Langerhans cell is a subtype of histiocyte first described by Dr Paul Langerhans in 1868.³ LCH is a rare disease arising from pathological proliferation of Langerhans histiocytes.

Histiocytes are formed in the bone marrow from a pluripotent self-renewing haemopoietic stem cell.^{4,5} They consist of two groups, namely mononuclear phagocytes (ordinary histiocytes) and antigen-presenting histiocytes. The former group includes the migratory blood monocyte and the fixed tissue macrophage (such as the hepatic Kuffer cell, pulmonary alveolar macrophage, brain microglia and splenic sinusoidal histiocyte). The latter group has a dendritic morphology which comprises the lymph nodal interdigitating reticulum cell and dendritic reticulum cell, the lymphoid dendritic cells of the blood and the Langerhans cell. The Langerhans cell is normally found in the skin. It can also occasionally be identified in many tissues such as in the bronchi, oral mucosa, oesophagus, thymus, etc. They are the most potent antigen-presenting cells in the body.

In 1987, the Histiocyte Society proposed three main classes as the working classification for histiocytoses,⁶ which gained widespread acceptance until 1994, when Pritchard and Broadbent put forward a modified version of the classification, dividing histiocytoses into four main classes (box 1).⁵

Pathogenesis

The nature of LCH is not completely understood, despite numerous studies of the disease in recent years. Various factors eg, viruses, the immune system (including lymphocytes and cytokines), cellular adhesion molecules, hereditary as well as neoplastic mechanisms, working alone or in combination, have been considered by different groups of workers to explain the pathogenesis of the disease (box 2).^{7–19}

The disease has been suspected to be due to an aberrant immunity precipitated by certain viruses. Both LCH and viral infections are prevalent among young people. However, meticulous investigations employing ultra-structural, serological and molecular (*in-situ* hybridisation, polymerase chain reaction) means have still failed to demonstrate any of the many common viruses in patients with LCH.^{7,8} One could therefore argue that other less common viruses may be the cause of LCH. Recently, herpes virus type 6 has been found in lesions of LCH⁹ but these findings have been seriously questioned by other investigators.⁸

Cytokines are protein hormones produced by cells of the immune and inflammatory systems. Their principal functions are to mediate and regulate cells in the above-mentioned systems. Various cytokines have already been demonstrated in LCH lesions using immunoassays, *in-situ* hybridisation and reverse transcription polymerase chain reaction.¹⁰ The patterns of cytokines detected are consistent with local activation of T lymphocytes and other inflammatory cells. In addition, abnormalities of T helper and suppressor ratios of the lymphocyte subpopulation have been documented. These findings merely illustrate the pathogenesis of LCH at a particular point in time but do not explain the diverse and changing presentation of patients with the disease.

Cellular adhesion molecules mediate cell–cell and cell–matrix adhesion and play important roles in many cell functions. Several articles have indicated the expression of cellular adhesion molecules in specimens from patients with LCH.^{11–13} It can be concluded that the abnormal cells in LCH not only share

Department of Pathology, University of Hong Kong, Queen Mary Hospital, Hong Kong
K-Y Lam

Accepted 29 March 1996

characteristics with normal Langerhans cells, but also have additional abnormal expression of cellular adhesion molecules. These features may contribute to migration of the Langerhans cells to abnormal sites, to an arrested state of activation and/or differentiation, and to the abnormal persistence and proliferation of these cells. The underlying stimulus causing this aberrant expression of cellular adhesion molecules is currently unknown.

The role of heredity in the transmission of LCH is also unknown. Katz and colleagues have reported LCH in monozygotic twins.¹⁴ There have been no reports of cases in which only one twin has LCH. The rare occurrence of familial LCH might suggest that a genetic mechanism is not likely to be crucial in triggering the onset of LCH.

One of the striking breakthroughs in the investigation of LCH is the recent demonstration of monoclonality in the disease. Clonality was demonstrated using X-linked polymorphic DNA probes by Willman and colleagues in female patients with either multifocal or solitary LCH.¹⁵ Yu *et al* reported similar findings in tissues enriched by flow sorting of CD1a positive cells.¹⁶ Furthermore, aberrant immunophenotypes (such as expression of CD68, lysosome, CD2, CD3, CD14, placental alkaline phosphatase, peanut agglutinin antigen) and proliferative markers (Ki-67, PCNA, Ki-S1 and DNA aneuploidy) have been detected in LCH.^{17,18} These imply that LCH is more likely to be a clonal neoplastic disease than a reactive one, with highly variable biological behaviour and clinical severity.

The aberrant immunophenotypes and proliferative markers are by no means specific markers of malignancy. Monoclonality is necessary but not sufficient to predict neoplasia. Whether a group of clonal cells exhibits benign or malignant behaviour depends upon additional factors like tissue micro-environment, host responses and constellation of genetic mutations. It is also worth noting that there is no evidence of clonal T-cell receptor gene rearrangements in cells involved in LCH.¹⁹ The definite proof of neoplastic aetiology thus must await the identification of potential somatic genetic mutations by the powerful cytogenetic and molecular techniques now available.

Clinical presentation

LCH can occur in patients of any age, with a peak incidence between one and three years old.²⁰ So far, limited data are available regarding the epidemiology of LCH because of its relatively low incidence. Nevertheless, epidemiologic investigations have already been undertaken in many different localities. It is anticipated that the prospective outcome of these studies will aid our understanding of the pathogenesis of this disorder. From available information,²⁰ LCH seems to be more common in males and there is no definite evidence of a racial difference in incidence.

The presentation of LCH is different in different age groups (box 3).²⁰⁻²³ Paraneoplastic syndrome (progressive spinocerebellar degeneration) has often been reported in patients with LCH.²⁴ Death may be related to severe insufficiency of several organs or to complications of treatment. Splenic rupture as a fatal cause has also been reported in a child.²⁵ Most patients have solitary LCH in the bone, although cases of LCH confined to the skin, lymph node, lung, brain and thyroid have also been reported.²⁶⁻²⁸ Recently the author and colleagues documented a unique case of solitary LCH in the spleen of a 29-year-old Chinese man, which was discovered incidentally at autopsy.²⁹

Almost any organ in the body can be involved with multifocal LCH (box 4).²⁰ Rarer sites like the female genital tract and central nervous system (including the eye) may also be occasionally infiltrated by LCH.^{30,31} In adults, there is a higher incidence of lung involvement.²⁰ The proposed explanation for this is the association of pulmonary LCH with an abnormal response to smoking.³²

Recent advances in the treatment of LCH have seen improvements in morbidity and mortality. Some patients have even become pregnant. A review of the literature reveals that the symptoms and signs of patients with LCH were either worsened or had a transient remission during pregnancy.^{33,34} All the pregnancies nevertheless resulted in live births.

Owing to the possibility of systematic manifestations, the minimum investigations in suspected cases of LCH include a complete history and physical examination, blood count, liver function tests, chest X-rays and skeletal survey.³⁵ Special investigations like bone marrow aspirate, enhanced computed tomography/magnetic resonance imaging, urine osmolality after water deprivation, etc, should also be employed if indicated after preliminary clinical assessments.³⁵

Clinical presentation of LCH in different age groups

Congenital

- often restricted to the skin and undergoes spontaneous involution

Young children

- multi-focal involvement with profound constitutional symptoms: (fever, rash, lymphadenopathy, ear discharge, dyspnoea, anaemia, polydipsia, jaundice, hepatosplenomegaly, etc)
- organ failure because of direct infiltration of Langerhans cells
- fluctuating course: requires systemic treatment and lesions may gradually regress; high morbidity and mortality in cases with organ failure; death may be related to severe insufficiency of several organs or complications of treatment

Older children and adults

- usually confined to a single organ
- localised swelling or pain
- may be asymptomatic and spontaneously regress

Box 3

Organs involved in LCH

In descending order of frequency

- bone
- skin
- lymph node/thymus
- ear
- bone marrow/peripheral blood
- liver/spleen
- lung
- endocrine system
- gastrointestinal tract

Box 4

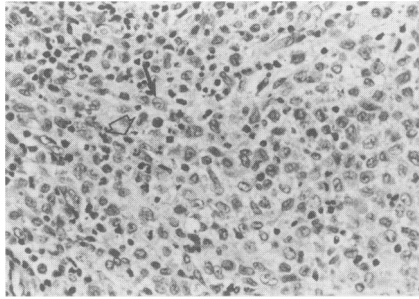


Figure 1 Histological section showing Langerhans cell histiocytosis. Note the characteristic grooved nuclei (solid arrow) admixed with eosinophils (empty arrow) (haematoxylin and eosin; orig $\times 500$)

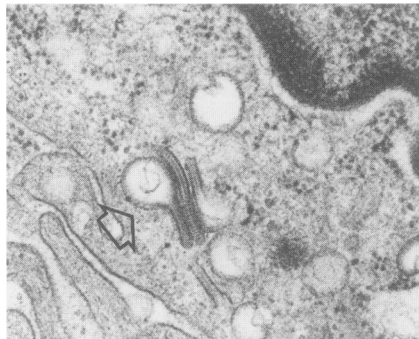


Figure 2 Electron micrograph of a Langerhans cell showing characteristic intra-cytoplasmic Birbeck's granules. Note the zipper-like periodic core of the granules with terminal expansion (uranyl acetate-lead citrate; orig $\times 52000$)

Pathology and associated tumours

- Langerhans cells with characteristic grooved nuclei intermixed with eosinophils and other inflammatory cells
- diagnosis dependent on either the detection of CD1a by immunohistochemistry or Birbeck's granules by electron microscopy
- often associated with other tumours (lymphoid malignancies most common)

Box 5

Pathology

Routine diagnosis is usually made on the basis of histological examination and the demonstration of S-100 by immunohistochemistry in biopsied materials, although some groups have made the diagnosis on fine-needle aspiration specimens.³⁶ On microscopic examination, the disease shows a collection of Langerhans cells intermixed with eosinophils and other inflammatory cells.³⁷ The nuclei of the Langerhans cells are often lobulated with a 'coffee bean' appearance (figure 1). Nevertheless, histological findings of LCH cannot predict the outcome of the disease.³⁸

A definite diagnosis of LCH necessitates either the detection of Birbeck's granules (Langerhans cell granules) by electron microscopy or the finding of CD1a expression by immunohistochemistry in the tumour cells (box 5).⁵ The finding of Birbeck's granules is more specific because they are found only in Langerhans cells. However, their identification is time-consuming and heavily dependent on tissue preservation and the experience of the pathologist.

Birbeck's granules are cytoplasmic granules which may be rod-, flask- or tennis-racket-shaped (figure 2).³⁹ They are usually regarded as a special type of endocytotic structure (which probably engulfs antigenic materials). However, there is also a belief that the granules arise from the Golgi apparatus and will eventually migrate to the cell membrane (ie, they probably have a secretory function).³⁹

CD1a has only been found in the cortical thymocyte and the Langerhans cell. In the past, the demonstration of CD1a (using the murine OKT6 monoclonal antibody) needed to be done on fresh/frozen tissues but recently, a mouse monoclonal antibody (Mab O10) has been found to recognise a formalin-resistant epitope of CD1a after microwave pretreatment of the de-paraffinized slides.⁴⁰

Association with tumours

Neoplasms occur in patients with LCH more frequently than would be expected by chance alone (box 5). The subject was extensively investigated by Egler *et al* who presented four such cases and reviewed 87 previously published cases.⁴¹ Neoplasms were detected in 3.5% of their patients with LCH. The intimate and simultaneous association of LCH with some tumours suggests that the process leading to the association may be a reactive one. On the other hand, the long latency between the appearance of the other tumours and LCH implies a therapy-related process.

More than half of the published cases have described and suggested an association between LCH and lymphoid malignancies (lymphomas and leukaemia).⁴¹ Amongst these, Hodgkin's lymphoma is more common than non-Hodgkin's lymphoma, whilst acute non-lymphoblastic leukaemia is the most common type of leukaemia. Other tumours reported to be associated with LCH include carcinomas (lung, thyroid, breast, liver, skin [basal cell carcinoma] and stomach), sarcomas (chondrosarcoma and osteosarcoma), tumours of central nervous system (astrocytoma, glioblastoma, medulloblastoma, ependymoma, retinoblastoma), apudoma and hepatoma. It is also worth noting that coexistence of various tumours, eg, osteosarcoma, lymphoma or medulloblastoma, and LCH may occur in the same patient, as described by Camargo *et al*.⁴² Recently, the author and colleagues have reported a unique case of LCH in a 35-year-old woman 15 years after the diagnosis of ovarian dysgerminoma.⁴³

Treatment

The optimal treatment for patients with LCH remains problematic. Difficulties lie primarily in the absence of controlled studies (due to the rarity of the disease) and the previous lack of standardised diagnostic criteria. The obscure understanding of the pathogenesis of LCH and the heterogeneity of clinical presentation have also precluded a definite treatment. Nevertheless, lately, systemic approaches have been made to the management of patients with LCH and an international randomised co-operative treatment trial has started.⁴⁴ These, together with the development of new forms of therapies, should lead to a better outcome for patients with LCH.

In patients with LCH, the aim of treatment is to relieve clinical symptoms and signs and prevent complications. Current treatment strategies depend on the presentation of the disease.⁴⁴ For single system disease, the lesion can be left alone after confirmation of diagnosis by biopsy, although local treatment may be necessary in certain circumstances to prevent dysfunction or deformity. This

may include surgical excision, local application of corticosteroids, nitrogen mustard and low-dose radiotherapy. On the other hand, there are two approaches for multisystem LCH, conservative minimal therapy or intensive chemotherapy treatment. Both forms of treatment involve systemic chemotherapy. The former approach involves close follow-up with short-term treatment to relieve signs and symptoms or disease progression. The latter approach involves rapid initiation of intensive chemotherapy. Recent findings suggest that combination chemotherapy is beneficial and that etoposide (VP-16) is a useful new monotherapy. In addition, the effectiveness of other experimental therapies (eg, cyclosporin, thalidomide, transplantations and monoclonal antibody) is being studied.⁴⁵⁻⁴⁹

The author would like to thank Dr ACL Chan for the photos and Miss Boney Lam for helping to prepare the manuscript.

- 1 Lichtenstein L. Histiocytosis X: integration of eosinophilic granuloma of bone, Letterer-Siwe disease and Schuller-Christian disease as related manifestations of a single nosologic entity. *Arch Pathol* 1953; **56**: 84-102.
- 2 Osband MF. Histiocytosis X, Langerhans' cell histiocytosis. *Hematol Oncol North Am* 1987; **1**: 737-51.
- 3 Langerhans P. Über die Nerven der menschlichen Haut. *Virch Archiv Pathol Anat* 1868; **44**: 325-7.
- 4 Cline MJ. Histiocytes and histiocytosis. *Blood* 1994; **84**: 2840-53.
- 5 Pritchard J, Broadbent V. Histiocytosis - an introduction. *Br J Cancer* 1994; **79**: S1-3.
- 6 The Histiocyte Society. Histiocytosis syndromes in childhood. *Lancet* 1987; **1**: 208-9.
- 7 Mierau GW, Wills EJ, Steele PO. Ultrastructural studies in Langerhans cell histiocytosis: a search for evidence of viral etiology. *Pediatr Pathol* 1994; **14**: 895-904.
- 8 McClain K, Jin H, Gresik V, Favara B, Baroni CD. Expression of adhesion molecules in Langerhans cell histiocytosis. *Am J Hematol* 1994; **47**: 16-20.
- 9 Leahy MA, Krejci SM, Friednash M, et al. Human herpesvirus 6 is present in lesions of Langerhans cell histiocytosis. *J Invest Dermatol* 1993; **101**: 642-5.
- 10 Kannourakis G, Abbas A. The role of cytokines in the pathogenesis of Langerhans cell histiocytosis. *Br J Cancer* 1994; **70**: S37-40.
- 11 Ruco LP, Stoppacciaro A, Vitolo D, Uccini S, Baroni CD. Expression of adhesion molecules in Langerhans' cell histiocytosis. *Histopathology* 1993; **23**: 29-37.
- 12 De Graaf JH, Tamminga RYJ, Kamps WA, Timens W. Langerhans' cell histiocytosis: expression of leukocyte cellular adhesion molecules suggests abnormal homing and differentiation. *Am J Pathol* 1994; **144**: 466-72.
- 13 De Graaf JH, Tamminga RYJ, Kamps WA, Timens W. Expression of cellular adhesion molecules in Langerhans cell histiocytosis and normal Langerhans cells. *Am J Pathol* 1995; **147**: 1161-71.
- 14 Katz AM, Rosenthal D, Jakubovic HR, Mohan Pai RK, Quinonez GE, Sauder DN. Langerhans cell histiocytosis in monozygotic twins. *J Am Acad Dermatol* 1991; **24**: 32-7.
- 15 Willman CL, Busque L, Griffith BB, et al. Langerhans' cell histiocytosis (Histiocytosis X) - a clonal proliferative disease. *N Engl J Med* 1994; **331**: 154-60.
- 16 Yu RC, Chu C, Buluwela L, Chu AC. Clonal proliferation of Langerhans cells in Langerhans cell histiocytosis. *Lancet* 1994; **343**: 767-8.
- 17 Hage C, Willman CL, Favara BE, Isaacson PG. Langerhans' cell histiocytosis (Histiocytosis X): immunophenotype and growth fraction. *Hum Pathol* 1993; **24**: 840-5.
- 18 Ornvold K, Carstensen H, Larsen JK, Christensen IJ, Ralfkiaer E. Flow cytometric DNA analysis of lesions from 18 children with Langerhans cell histiocytosis (Histiocytosis X). *Am J Pathol* 1990; **136**: 1301-7.
- 19 Yu RC, Chu AC. Lack of T-cell receptor gene rearrangements in cells involved in Langerhans cell histiocytosis. *Cancer* 1995; **75**: 1162-6.
- 20 Broadbent V, Egeler RM, Nesbit ME. Langerhans cell histiocytosis - clinical and epidemiological aspects. *Br J Cancer* 1994; **70**: S11-6.
- 21 Leavey P, Varughese M, Breatnach F, O'Meara A. Langerhans cell histiocytosis - a 31 year review. *Ir J Med Sci* 1991; **160**: 271-4.
- 22 Chen BR, Liang DC. A clinicopathological study of Langerhans cell histiocytosis. *Chin Med J* 1994; **54**: 116-21.
- 23 Longaker MA, Frieden IJ, LeBoit PE, Sherertz EF. Congenital 'self-healing' Langerhans cell histiocytosis: the need for long-term follow-up. *J Am Acad Dermatol* 1994; **31**: 910-6.
- 24 Goldberg-Stern H, Weitz R, Zaizov R, Gornish M, Godoth N. Progressive spinocerebellar degeneration 'plus' associated with Langerhans cell histiocytosis: a new paraneoplastic syndrome? *J Neurol Neurosurg Psychiatry* 1995; **58**: 180-3.
- 25 Broadbent V, Williams M, Dossetor J. Ruptured spleen as a cause of death in an infant with Langerhans cell histiocytosis (Histiocytosis X). *Pediatr Hematol Oncol* 1990; **7**: 297-9.
- 26 Henry K. Lymph nodes, Langerhans cell histiocytosis. In: Henry K, Symmers WStC, eds, *Systemic pathology, vol 7. Thymus, lymph nodes, spleen and lymphatics*, 3rd edn. Edinburgh: Churchill Livingstone, 1992; pp 297-308.
- 27 Tsang WYW, Lau MF, Chan JKC. Incidental Langerhans' cell histiocytosis of the thyroid. *Histopathology* 1994; **24**: 397-9.
- 28 Montine TJ, Hollensead SC, Ellis WG, Martin JS, Moffat EJ, Burger PC. Solitary eosinophilic granuloma of the temporal lobe: a case report and long-term follow-up of previously reported cases. *Clin Neuropathol* 1994; **13**: 225-8.
- 29 Lam KY, Chan ACL, Wat MS. Langerhans' cell histiocytosis forming an asymptomatic solitary nodule in the spleen. *J Clin Pathol* 1996; **49**: 262-4.
- 30 Axiotis CA, Merino MJ, Duray PH. Langerhans cell histiocytosis of the female genital tract. *Cancer* 1991; **67**: 1650-60.
- 31 Grois N, Tsunematsu Y, Barkovich AJ, Favara BE. Central nervous system disease in Langerhans cell histiocytosis. *Br J Cancer* 1994; **70**: S24-8.
- 32 Travis WD, Borok Z, Roum JH, et al. Pulmonary Langerhans cell granulomatosis (histiocytosis X). A clinicopathologic study of 48 cases. *Am J Surg Pathol* 1993; **17**: 971-86.
- 33 DiMaggio LA, Lippes HA, Lee RV. Histiocytosis X and pregnancy. *Obstet Gynecol* 1995; **85**: 806-9.
- 34 Scherbaum WA, Seif FJ. Spontaneous transient remission of disseminated histiocytosis X during pregnancy. *J Cancer Res Clin Oncol* 1995; **121**: 57-60.
- 35 Broadbent V, Gardner H, Komp DM, Ladisch S. Histiocytosis syndromes in children: II. Approach to the clinical and laboratory evaluation of children with Langerhans cell histiocytosis. *Med Pediatr Oncol* 1989; **17**: 492-5.
- 36 Akhtar M, Ali MA, Bakry M, Sackey K, Sabbah R. Fine needle aspiration biopsy of Langerhans histiocytosis (Histiocytosis). *Diagn Cytopathol* 1993; **9**: 527-33.
- 37 Favara BE, Jaffe R. The histopathology of Langerhans cell histiocytosis. *Br J Cancer* 1994; **70**: S17-23.
- 38 Ben-ezra JM, Koo CH. Langerhans' cell histiocytosis and malignancies of the M-PIRE system. *Am J Clin Pathol* 1993; **99**: 464-71.
- 39 Chu T, Jaffe R. The normal Langerhans cell and the LCH cell. *Br J Cancer* 1994; **70**: S4-10.
- 40 Emile JF, Wechsler J, Brousse N, et al. Langerhans' cell histiocytosis: definitive diagnosis with the use of monoclonal antibody O10 on routinely paraffin-embedded samples. *Am J Surg Pathol* 1995; **19**: 636-41.
- 41 Egeler RM, Neglia JP, Puccetti DM, Brennan CA, Nesbit ME. Association of Langerhans cell histiocytosis with malignant neoplasms. *Cancer* 1993; **71**: 865-73.
- 42 De Camargo B, Alves AC, Gorender EF, Bianchi A. Association of malignancy and Langerhans' cell histiocytosis. Report of three cases. *Med Pediatr Oncol* 1993; **21**: 451-3.
- 43 Ng WK, Lam KY, Ng IOL. Langerhans' cell histiocytosis: possible association with malignant germ cell tumour. *J Clin Pathol* 1995; **48**: 963-5.
- 44 Ladisch S, Gardner H. Treatment of Langerhans cell histiocytosis - evolution and current approaches. *Br J Cancer* 1994; **70**: S41-6.
- 45 Arico M, Colella R, Counter V, et al. Cyclosporine therapy for refractory Langerhans cell histiocytosis. *Med Pediatr Oncol* 1995; **25**: 12-6.
- 46 Thomas L, Ducros B, Secchi T, Balme B, Moulin G. Successful treatment of adult's Langerhans cell histiocytosis with thalidomide: report of two cases and literature review. *Arch Dermatol* 1993; **129**: 1261-4.
- 47 Zandi P, Panis Y, Debray D, Bernard O, Houssin D. Pediatric liver transplantation for Langerhans' cell histiocytosis. *Hepatology* 1995; **21**: 129-33.
- 48 Morgan G. Myeloablative therapy and bone marrow transplantation for Langerhans cell histiocytosis. *Br J Cancer* 1994; **70**: S52-3.
- 49 Kelly KM, Pritchard J. Monoclonal antibody therapy in Langerhans cell histiocytosis - feasible and reasonable? *Br J Cancer* 1994; **70**: S54-5.