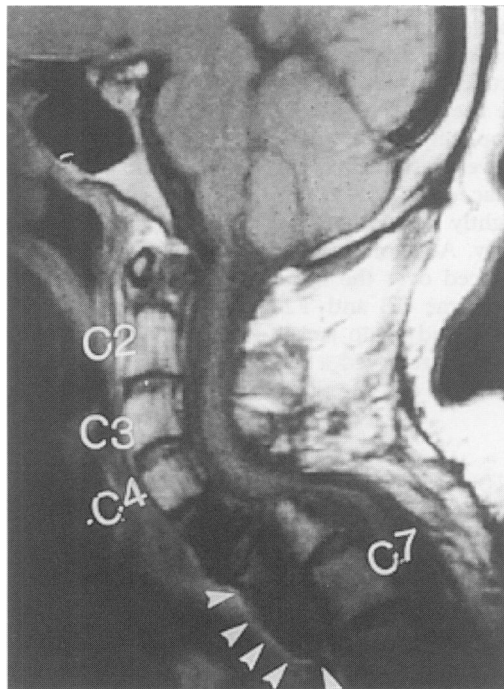


# Quadriplegia with cervical cord compression

Ahmed Tammam, H Alan Crockard

A 36-year-old man was admitted to this unit with almost complete quadriplegia with no sensory level. The bladder and bowel functions had remained intact. When he was a 20-year-old student he had presented with brachialgia and neck swelling, which had been aspirated percutaneously in India in 1980; the fluid was discovered to contain protoscolices and he was given a full course of mebendazole. Two years later he developed spinal cord compression. He had posterior exploration and cervical laminectomy in the Middle East in 1982 followed by another three surgical attempts posteriorly with further laminectomies in the Middle East in 1983, India in 1985, and USSR in 1989. Each attempt was followed by a course of mebendazole and resulted in a minimal degree of improvement for a short period of time.

Plain X-ray of the cervical spine showed a swan neck deformity. Magnetic resonance imaging (MRI) was performed (figure).



### Questions

- 1 What does the MRI scan show?
- 2 What are the most probable causes of these changes?
- 3 How should such a case be treated?

Department of  
Surgical Neurology,  
The National  
Hospital For  
Neurology and  
Neurosurgery,  
Queen Square,  
London WC1N 3BG,  
UK  
A Tammam  
HA Crockard

Correspondence to  
HA Crockard

Accepted 17 July 1996

**Figure** MRI scan (sagittal view)

## Answers

### QUESTION 1

The MRI scan shows the 'swan neck' deformity and the kyphotic deformity of the spinal cord. The C5 vertebra has been completely eroded by the hydatid cyst (arrow). There are no posterior bone elements below C3 and thus the whole vertebral column has slipped forward.

### QUESTION 2

The most probable causes of these changes are the recurrence of the hydatid disease with destruction of the body of the C5 vertebra, added to the non-indicated previous laminectomies which led to these deformities and compression of the cord.

### QUESTION 3

This case was treated by excision of the hydatid cyst with removal of all the necrotic bone from C4 to C6, including the discs, through an anterior approach. A wide channel of decompression was carried out to correct the kyphosis, and the dura all along the area was exposed but left intact. Hypertonic saline, betadine and alcohol were used to soak all the surrounding tissues. Completely new instruments, gloves and gowns were used to obtain a bone graft from the iliac crest which was carefully shaped to be slightly larger than the defect and thus to fit tightly. A titanium plate of sufficient length was placed over the bone graft and the adjacent vertebrae C3 and T2. The patient was placed in a body halo jacket for six months during which he received a full course of mebendazole and an intensive course of physiotherapy.

## Discussion

Hydatid disease may be found in various sites in the human body and is localised in bone in about 1% of cases, half of these in the spine.<sup>1,2</sup> Involvement of the cervical spine is very rare as most of the literature describes cases in the thoracic, lumbar and sacral regions caused by direct extension from pulmonary and abdominal lesions, respectively.<sup>3-6</sup> It is assumed that the cervical involvement is haematogenous,

although in this particular case spread via the lymphatic duct is a possibility.

The disease is characterised by multivesicular infiltration of the spongy bone<sup>1,2,6</sup> so it mainly involves the vertebral bodies and to a lesser extent the pedicles and the laminae. The dura usually remains intact.<sup>7</sup>

The condition should be suspected on radiology with plain X-rays showing moth-eaten areas of vertebrae surrounded by sclerosis. CT scans are of great value in demonstrating bony erosions and cystic cavities.<sup>3</sup> MRI is very useful in showing the parasitic cysts within the spinal canal and in the paraspinal tissues and in determining the degree of spinal cord compression.<sup>7,8</sup>

Aspiration biopsy has no place, as diagnosis of the disease can be made radiologically or by special laboratory tests such as Casoni and Weinberg tests, especially when there is soft tissue involvement.<sup>3,9,10</sup> The first procedure may have encouraged local spread. While mebendazole can control soft tissue hydatid infection there is little evidence that it is successful with bony lesion. In this patient, five courses of this very expensive drug seem to have had little effect.

Radical surgical excision of the affected vertebrae and soft tissues with proper stabilisation of the spine is the ideal treatment of the disease. Although all surgical options are difficult, laminectomy is considered the worst as it is a potentially destabilising procedure and removes the only section of the vertebra which is not involved and will not remove a significant amount of the lesion; further local spread would have been encouraged by this manoeuvre.

Cervical stabilisation with bone graft and titanium locking plates may be a more radical approach and ideally would be a recommended first line of attack. Even this would be difficult, however.

## Final diagnosis

Recurrent cervical spine hydatid disease with spinal cord compression.

**Keywords:** hydatid disease, cervical spine, cervical stabilisation

- 1 Baysefer A, Gonul E, Canakci Z, Erdogan E, Aydogan N, Kayali H. Hydatid disease of the spine. *Spinal Cord* 1996; 34: 297-300.
- 2 Morris DL. Diagnosis of hydatid disease. In: Morris DL, Richards KS, eds. *Hydatid disease*, 1st edn. Oxford: Butterworth-Heinemann, 1992; pp 25-56.
- 3 Ozer AF, Ozek MM, Pamir MN, Erzen C. Magnetic resonance imaging in the diagnosis of spinal hydatid disease: a case report. *Paraplegia* 1993; 31: 338-40.
- 4 Pamir MN, Akalan N, Ozgen T, Erben A. Spinal hydatid cysts. *J Surg Neurol* 1984; 21: 53-7.
- 5 Kaypot M, Wiscoff HS, Zaiman H. Vertebral echinococcosis. *J Neurosurg* 1964; 21: 647-59.
- 6 Yegen C, Ozer AF, Aktan AO, Yalin R. Sacrococcygeal hydatid cyst: another entity in the differential diagnosis of sacrococcygeal chordoma: case report. *Paraplegia* 1993; 31: 479-81.

- 7 Tekkol IH. Primary spinal extradural hydatid disease: report of a case with MRI characteristics and pathological correlation. *Neurosurgery* 1993; 33: 320-2.
- 8 Turtas S, Sehrbunt E, Pau A. Long-term results of surgery for hydatid disease of the spine. *Surg Neurol* 1980; 13: 468-70.
- 9 Apt WL, Fierro JR, Calderon C, Perez C, Mujica. Vertebral hydatid disease, clinical experience with 27 cases. *J Neurosurg* 1976; 44: 72-6.
- 10 Arana IR, Fernandez LR. Parasitosis of the nervous system, with special reference to echinococcosis. *Clin Neurosurg* 1967; 14: 123-44.