

# Acute renal failure with chronic lymphocytic leukaemia

A Martínez-Vea, MJ Herranz, A Llorente, M Carrera, C García, S Razquín, JA Oliver

**Nephrology, Hematology and Pathology Services, Hospital Universitari de Tarragona Joan XXIII, Universitat Rovira i Virgili, Tarragona, Spain**

A Martínez-Vea  
MJ Herranz  
A Llorente  
C García  
S Razquín  
JA Oliver

**Department of Pathology, Hospital Princeps d'Espanya, L'Hopitalet de Llobregat, Barcelona, Spain**  
M Carrera

Correspondence to A Martínez-Vea, Apartado de Correos 12, 43080 Tarragona, Spain

Accepted 16 October 1995

A 70-year-old man was admitted with a two-week history of weakness, tiredness, severe anaemia, thrombocytopenia and advanced renal failure. A chronic lymphocytic leukaemia, stage B of Binet's classification, had been diagnosed in 1985. He had received intermittent treatment with chlorambucil, prednisone and allopurinol. The last course of these drugs was completed two weeks before admission. Serum creatinine at this time was 97.2  $\mu\text{mol/l}$ . Physical examination revealed an afebrile man with a blood pressure of 130/80 mmHg, generalised lymphadenopathy and hepatosplenomegaly.

The white blood cell count was  $110 \times 10^9/\text{l}$  with 98% mature lymphocytes, the haematocrit was 16% and the platelet count  $320 \times 10^9/\text{l}$ . The Coombs test was negative. Serum creatinine was 512.7  $\mu\text{mol/l}$ , calcium 2.35 mmol/l, uric acid 529  $\mu\text{mol/l}$ . Urine protein excretion was 0.54 g/day. The sediment contained 10 erythrocytes/hpf. The urine was free of Bence Jones proteins. Serologic tests for B and C hepatitis, human immunodeficiency virus, cryoglobulins, anti-DNA and anti-GMB antibodies, ANCA and complement studies were all within the normal range or negative. Serum M component was not evident.

Computed tomography (CT) of the abdomen and a renal sonogram revealed retroperitoneal lymphadenopathy, enlargement of the liver and spleen, and normal kidneys with no evidence of hydronephrosis. A bone marrow biopsy revealed a hypercellular marrow with diffuse lymphocytic infiltration. Bone marrow aspiration showed 98% lymphocytes. Cell marker studies demonstrated a monoclonal B cell population in the blood and marrow. Serum creatinine rose to 884  $\mu\text{mol/l}$  requiring haemodialysis.

## Questions

- 1 Suggest three possible causes for his acute renal failure
- 2 What diagnostic test should be performed?

## Answers

### QUESTION 1

Chronic lymphocytic leukaemia may be associated with a number of complications<sup>1-3</sup> which can cause renal failure (box 1). In our patient there was no evidence of obstruction due to uric acid stones or enlarged lymph nodes, no Bence-Jones proteinuria, no cryoglobulinaemia, no evidence of haemolysis-induced tubular necrosis, and no hyperuricaemia or hyperphosphataemia as a part of tumour lysis syndrome. Renal leukaemic infiltration is frequent in chronic lymphocytic leukaemia, although it rarely leads to significant impairment of renal function. The absence of heavy proteinuria and red blood cell casts argued against the possibility of chronic lymphocytic leukaemia-associated glomerulonephritis.

### QUESTION 2

As no definitive cause of renal failure was found, an open renal biopsy was performed. The biopsy specimen revealed approximately 30 glomeruli, of which five were globally sclerosed. The rest of the glomeruli showed no significant abnormalities. There was a marked interstitial inflammatory cell infiltrate composed predominantly of lymphocytes, monocytes and some eosinophils; tubular damage of varying severity was also evident. Numerous noncaseating granulomas consisting of epithelioid cells and multinucleated giant cells were identified in the interstitium (figure). Stains for acid-fast bacilli and fungi were negative. Occasionally, peritubular granulomas invading and destroying the tubules were also found. Immunoperoxidase examination revealed no deposits of IgG, IgA, IgM, C3 or fibrinogen. The lymphocytes showed strong staining with the T-cell-specific UCHL-1 antibody and weak staining with the B-cell-specific CD 20 antibody.

On the basis of the renal biopsy, an extensive search of causes of granulomatous interstitial nephritis (box 2) was made. Serologic tests for Brucella, Toxoplasma, and Epstein-Barr virus were negative. Optic fundi were nearly normal and slit lamp examination of the eyes disclosed no abnormalities. Serum angiotensin-converting enzyme was normal. Chest X-ray and pulmonary function test were not suggestive of sarcoidosis. The existence of recent treatment with allopurinol and the

#### Renal failure associated with chronic lymphocytic leukaemia

- obstructive uropathy
- leukaemic infiltration of the kidney (unusual)
- acute uric acid nephropathy/tumour lysis syndrome
- haemolysis
- glomerulopathy: most common: membranoproliferative glomerulonephritis (with cryoglobulins); less common: focal or diffuse proliferative glomerulonephritis, light-chain nephropathy, primary (AL-type) amyloidosis

#### Box 1

absence of other known causes of granulomatous interstitial nephritis<sup>4</sup> make it highly likely that this drug was the cause of this unusual renal lesion in our patient. Treatment with prednisone 70 mg/day and a subsequent course of CHOP (cyclophosphamide, doxorubicin, vincristine and prednisone) was started. Renal function improved gradually reaching a serum creatinine of 212  $\mu\text{mol/l}$  during the following month.

### Discussion

Acute granulomatous interstitial nephritis is associated fundamentally with drugs. The most common drugs implicated are antibiotics, analgesics/nonsteroidal anti-inflammatory drugs and diuretics. Allopurinol has also been implicated in the development of granulomatous interstitial nephritis and granulomatous hepatitis. Nevertheless, renal interstitial granulomas are extremely uncommon. To our

#### Causes of granulomatous interstitial nephritis

- infections
- drugs
- vasculitis (Wegener's granulomatosis)
- metabolic disease (gout, oxalosis)
- idiopathic
- others (sarcoidosis, interstitial nephritis with uveitis)

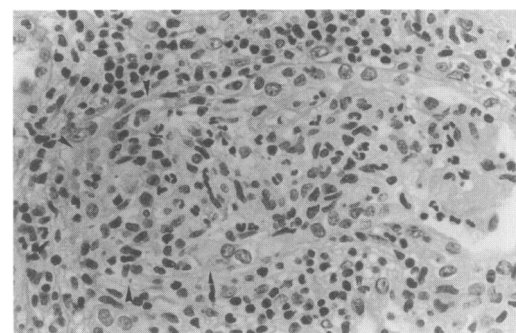
#### Box 2

#### Clinical findings in drug-related acute interstitial nephritis

- fever, skin rash, arthralgias (variable)
- eosinophilia (variable)
- acute renal failure (fractional excretion of filtered sodium usually > 1)
- urinalysis
  - microscopic or macroscopic haematuria
  - mild proteinuria (usually < 1 g/day\*)
  - leucocyturia without pyuria
  - eosinophiluria (occasionally)

\*rarely > 1 g/day (nonsteroidal anti-inflammatory drugs)

#### Box 3



**Figure** Acute interstitial nephritis. A well-developed noncaseating granuloma (arrows) is present in the interstitium (Hematoxylin-eosin stain original  $\times 16$ )

knowledge, there are only three reports of granulomatous interstitial nephritis following allopurinol therapy.<sup>5-7</sup>

Clinical findings in drug-related acute interstitial nephritis may be characteristic (box 3). Nevertheless, drug-induced granulomatous interstitial nephritis seems to have less incidence of clinical manifestations of hypersensitivity than nongranulomatous forms.<sup>8</sup> Our patient did not show any of the systemic manifestations that typically accompany an allergic process, such as fever, arthralgias, skin rash or eosinophilia.

The benefit of steroid therapy in acute interstitial nephritis remains a matter of debate. For some authors drug-induced granulomatous interstitial nephritis is an indication for treatment with corticosteroids since patients with interstitial granulomas have a greater risk of permanent renal damage than those without.<sup>8</sup>

Chronic lymphocytic leukaemia may have played a role in the development of granulo-

matous interstitial nephritis in the present case. The worsening of chronic lymphocytic leukaemia and the presence of granulomatous interstitial nephritis occurred simultaneously. The abnormal T-cell function commonly seen in chronic lymphocytic leukaemia<sup>9</sup> could have increased the patient's susceptibility to exogenous antigens, in this case, allopurinol. Recently, an acute granulomatous interstitial nephritis due to nitrofurantoin has been described in a patient suffering from chronic lymphocytic leukaemia.<sup>10</sup>

### Final diagnosis

Acute granulomatous interstitial nephritis associated with allopurinol therapy.

**Keywords:** granulomatous interstitial nephritis, allopurinol, chronic lymphocytic leukaemia, renal failure

- 1 Dabbs DJ, Morel-Maroger Striker L, Mignon F, Striker G. Glomerular lesions in lymphomas and leukemias. *Am J Med* 1986; 80: 63-70.
- 2 Morse BM, Shattil SJ. Metabolic complications of aggressive therapy of chronic lymphocytic leukemia. *Am J Med Sci* 1974; 267: 311-4.
- 3 Moulin B, Ronco PM, Mougnot B, Francois A, Fillastre JP, Mignon F. Glomerulonephritis in chronic lymphocytic leukemia and related B-cell lymphomas. *Kidney Int* 1992; 42: 127-35.
- 4 Colvin RB, Fang LST. Interstitial nephritis. In: Tisher CC, Brenner BM, eds. *Renal pathology*. Philadelphia: JB Lippincott, 1989; pp 760-4.
- 5 Magnier P, Sweet J, Bear RA. Granulomatous interstitial nephritis associated with allopurinol therapy. *Can Med Assoc J* 1986; 135: 496-7.
- 6 Mousson C, Justrabo E, Tanter Y, Chalopin JM, Riffle G. Néphrite interstitielle et hépatite aiguës granulomateuses d'origine médicamenteuse. Rôle possible de l'association allopurinol-furosémide. *Néphrologie* 1986; 5: 199-203.
- 7 Parra E, Gota R, Gamen A, Moros M, Azuara M. Granulomatous interstitial nephritis secondary to allopurinol therapy. *Clin Nephrol* 1995; 43: 350.
- 8 Kleinknecht D, Vanhille Ph, Druet Ph. Néphrites interstitielles aiguës granulomateuses d'origine médicamenteuse. *Presse Méd* 1988; 17: 201-5.
- 9 Freeman AS. Immunobiology of chronic lymphocytic leukemia. *Hematol Oncol Clin North Am* 1990; 4: 405-29.
- 10 Korzets Z, Elis A, Bernheim J, Bernheim J. Acute granulomatous interstitial nephritis due to nitrofurantoin. *Nephrol Dial Transplant* 1994; 9: 713-5.