

Sternal mass and fever

TC Mineo, F Biancari

A 28-year-old Somali man presented with a painful non-tender swelling over the manubrium of 7 cm in diameter, and a three-month history of remittent fever. No peripheral lymphadenopathies were present. The white cell count was $8.4 \times 10^9/l$ and the erythrocyte sedimentation rate 78 mm/h. The human immunodeficiency virus (HIV) screen was negative. A chest X-ray showed clear lung fields, mediastinal widening and a retrosternal mass. A computed tomography (CT) scan revealed para-aortic, subcarinal and paratracheal lymphadenopathy invading the manubrium (figure).

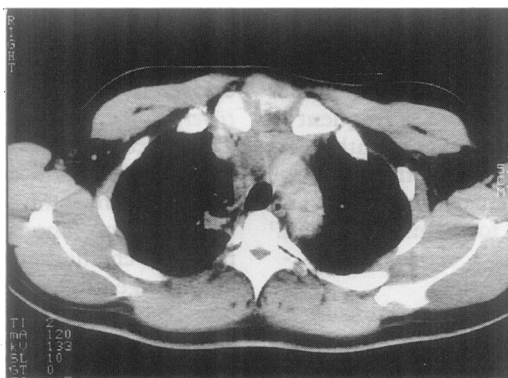


Figure CT scan of the chest shows a retrosternal mass invading and causing lytic defects in the manubrium

**Department of
Thoracic Surgery,
University Tor
Vergata of Rome,
Rome, Italy**
TC Mineo
F Biancari

Correspondence to
Prof TC Mineo, Cattedra di
Chirurgia Toracica,
Università Tor Vergata di
Roma, Ospedale S Eugenio,
Piazzale dell'Umanesimo 10,
00144 - Rome, Italy

Accepted 2 March 1994

Questions

- 1 Suggest three causes of mediastinal lymph node enlargement in this case.
- 2 What further investigations should be performed?

Answers

QUESTION 1

Mediastinal lymph node enlargement can be due to three general categories of disease processes (box). Tuberculosis, histoplasmosis and sarcoidosis are granulomatous diseases that commonly involve mediastinal lymph nodes, with or without pulmonary parenchymal involvement. Granulomatous mediastinitis and mediastinal fibrosis are also caused by these disorders.¹ Lymphoma is a common mass of the anterior mediastinum and hilar area. Of all cases of mediastinal lymphoma, Hodgkin's disease accounts for only a third, the majority being histiocytic, lymphocytic and undifferentiated lymphomas. Nodular sclerosing type is the presenting histologic type in 67% to 84% of patients with intrathoracic Hodgkin's disease.² The lesions are commonly found on a routine chest X-ray in asymptomatic patients, although many patients have systemic symptoms such as fever, night sweats, and weight loss. Lymphatic spread to nodes of the hilum and the mediastinum is frequent in carcinoma of the lung. However, nonthoracic tumors, such as malignancies of the head, the neck, the genitourinary tract, the breast, and the skin also metastasize to the mediastinum.¹

QUESTION 2

Tuberculin skin test and sputum smears for *Mycobacteria*. A bone marrow biopsy can rule out malignancy or granulomatous inflammation.

Although mediastinal lymphadenopathies can be detected accurately by CT and other imaging procedures, these cannot separate malignant from benign causes.³ Therefore, for the large majority of mediastinal lymphadenopathies, diagnostic evaluation must include examination of tissue obtained from the lesions. Transbronchial needle aspiration through the rigid or flexible fiber-optic bronchoscope can yield tissue for cultures and cytologic examination.⁴ Percutaneous needle aspiration biopsy under fluoroscopic or CT guidance can be done with acceptable morbidity.⁴ As with transbronchial needle aspiration, serious bleeding is seldom encountered, presumably because the elasticity of lymph nodal and other tissues causes the puncture hole to seal.² Mediastinoscopy is a procedure allowing direct inspection and biopsy of lymph nodes in the superior portion of the anterior mediastinum.² Although more invasive than the techniques previously discussed, mediastinoscopy provides histologic specimens rather than individual cells for cytologic study. Anterior mediastinotomy, thoracotomy, and thoracoscopy allow exploration of most lymph node locations than cannot be reached via the mediastinoscope.

In our patient, fine needle aspiration of the sternal lesion was easily performed but no significant findings resulted. Surgical biopsy of the swelling was finally performed and allowed

Causes of mediastinal lymph node enlargement

- granulomatous diseases: tuberculosis, histoplasmosis, sarcoidosis
- lymphomas: Hodgkin's disease, histiocytic, lymphocytic and undifferentiated tumours
- metastatic tumours

adequate tissue for diagnostic smears and cultures.

Discussion

Surgical exploration revealed an abscess cavity, necrotic tissue and signs of osteolysis in the manubrium. Smears from the specimens showed well-formed epithelioid cell granulomas, giant cells and caseation necrosis. Ziehl-Neelsen stain was positive. Cultures of excised tissue were positive for *Mycobacterium tuberculosis*.

In recent years the increased number of immigrants from developing countries and immunocompromised patients as a result of acquired immunodeficiency diseases, malignancies, chemotherapy, or systemic illnesses has changed the pattern of tuberculosis in that non-respiratory disease appears to be more common, leading to a great variety of clinical presentations.⁵

Sternal tuberculosis is a very rare disease⁶ and it is commonly not considered in the initial differential diagnosis of sternal mass.⁷ Tuberculous lymphadenitis without pulmonary infiltrations, in adults, is an uncommon cause of mediastinal enlargement.⁵ This pattern is frequently interpreted as a malignancy, especially lymphoma⁵⁻⁷ demonstrating that tuberculosis remains the 'Great Masquerader'. It is uncertain whether it represents a primary infection or a reactivation of a latent nodal focus.

Recent reports, because of the occasional tragic outcome due to delayed appropriate treatment, suggested a high degree of suspicion in high-risk patients to establish an early diagnosis of atypical presenting forms of tuberculosis.⁴ Hanania and Hoffstein⁵ emphasized that a presumptive diagnosis of tuberculosis may be established on clinical grounds alone and an empiric antituberculous therapy may be commenced, while awaiting culture results. The diagnosis may be confirmed by response to antituberculous drugs avoiding expensive and invasive investigations.

Final diagnosis

Sternal osteomyelitis as presenting manifestation of mediastinal tuberculous lymphadenopathy.

Keywords: mediastinal lymphadenopathy, mycobacterium tuberculosis, sternal mass

- 1 DJ Pierson. Tumors and cysts of the mediastinum. In: Murray JF, Nadel JA, eds. *Textbook of respiratory medicine*. Philadelphia: WB Saunders Company, 1994; pp 2278–89.
- 2 DJ Pierson. Disorders of the mediastinum. General principles and diagnostic approach. In: Murray JF, Nadel JA, eds. *Textbook of respiratory medicine*. Philadelphia: WB Saunders Company, 1994; pp 2235–49.
- 3 Dooms GC, Hricak H. Radiologic imaging modalities, including magnetic resonance, for evaluating lymph nodes. *West J Med* 1986; 114: 49–57.
- 4 Khan J, Akhtar M, von Simmer WN, Bouchama A, Bazarbashi M. CT-guided fine needle aspiration biopsy in the diagnosis of mediastinal tuberculosis. *Chest* 1994; 106: 1329–32.
- 5 Hanania N, Hoffstein V. Tuberculosis presenting with generalized lymphadenopathy, pulmonary infiltrates and bone destruction in a young man. *Arch Intern Med* 1993; 153: 1265–7.
- 6 Watts RA, Paice EW, White AG. Spontaneous fracture of the sternum and sternal tuberculosis. *Thorax* 1987; 42: 984–5.
- 7 Kaplan G, De Gennes C, Le Charpentier Y. Tuméfaction sternale douloureuse et fébrile chez une martiniquaise. *Ann Med Intern* 1990; 141: 71–6.

Acute pulmonary oedema in late pregnancy

D O'Mahony, G Hendry, P Strube, M Jonas, D Sumner

Case history

An 18-year-old Asian primigravida, 34 weeks pregnant, presented to hospital with mild-to-moderate pregnancy-induced hypertension (blood pressure 160/105 mmHg) and 1+ proteinuria on urinalysis. Antenatal assessments had been hitherto normal. She was treated with intravenous hydralazine without success. Methyldopa was added to her therapy, but her blood pressure remained elevated and proteinuria deteriorated to 2+. On the third hospital day, the patient became severely breathless over a period of four hours. On examination, she was moderately distressed and tachypnoeic (34 beats/min) and had a gallop rhythm with diffuse fine inspiratory crackles in both lung bases. A chest radiograph confirmed appearances of pulmonary oedema.

Investigation results

- arterial blood gas analysis on room air: pO₂ 9.3 kPa, pCO₂ 4.1 kPa, pH 7.46, actual HCO₃ 22.1 mmol/l, O₂ saturation 94.9%
- ECG: sinus tachycardia only
- chest radiograph: normal cardiac size and contour, signs of bilateral lower zone parenchymal soft tissue shadowing and Kerley B lines consistent with pulmonary oedema
- plasma creatinine 66 µmol/l, sodium 140 mmol/l, potassium 3.9 mmol/l, serum albumin 29 g/l, total serum protein 53 g/l
- echocardiography (M-mode and 2-D); hyperdynamic left ventricle not hypertrophied or dilated. Left atrium slightly dilated (3.4 cm). No evidence of valvular disease or septal defect. Mild mitral regurgitation noted on colour flow and Doppler flow analysis
- Free T3 6.1 pmol/l (normal 4.3–7.6 pmol/l); TSH 0.14 mIU/l (normal 0.14–3.45 mIU/l)

Questions

- 1 Suggest three cardiovascular causes of acute pulmonary oedema in late pregnancy?
- 2 What is the most likely cause of pulmonary oedema?
- 3 What is the recommended management?
- 4 What is the prognosis?

Wycombe General Hospital, Queen Alexandra Rd, High Wycombe, Bucks, HP11 2TT, UK
Department of Medicine
 D O'Mahony
 G Hendry
Department of Anaesthetics
 P Strube
 M Jonas
Department of Obstetrics and Gynaecology
 D Sumner

Accepted 29 March 1995