

Review Article

Neurogenic thoracic outlet syndromes

John D. Urschel, S. Morad Hameed and Raji P. Grewal

Department of Surgery, State University of New York at Buffalo, Buffalo, New York and The Neurological Institute, Columbia University, New York, New York, USA

Introduction

‘Neurogenic thoracic outlet syndrome’ is a poorly defined and controversial term for a group of upper extremity nerve compression disorders.¹ The objective of this article is to summarize current knowledge, review controversies, and formulate a rational management plan for neurogenic thoracic outlet syndromes (NTOS). We will present a balanced perspective that considers thoracic surgical and neurological viewpoints.

Thoracic outlet syndromes can be divided into four groups: arterial, venous, classic neurogenic, and non-specific neurogenic.^{2,3} The diagnosis of arterial and venous thoracic outlet syndromes is straightforward since characteristic clinical and radiographic findings are present. Classic NTOS is a diagnosis based on objective diagnostic features. Non-specific NTOS is a diagnosis based on suggestive symptomatology and exclusion of other entities. Vascular thoracic outlet syndromes are not discussed. Classic and non-specific NTOS will be reviewed separately.

Classic neurogenic thoracic outlet syndrome

Classic NTOS (true NTOS, cervical rib syndrome) is a universally accepted neurological entity (Table I). Its incidence is approximately one per million.⁴ A cervical rib, abnormal C7 transverse process, or abnormal cervical band is usually present. Compression of the lower brachial plexus by the abnormal rib or band produces characteristic neurological deficits. Patients complain of pain and paraesthesiae of the medial forearm and hand. On examination, sensory loss is detectable along the medial forearm and over the fourth and fifth fingers. Intrinsic hand muscles are weak and muscle wasting is often apparent. The lateral thenar

muscles are the most severely affected muscles. Electromyographic examination shows evidence of chronic lower trunk, axon-loss brachial plexopathy.^{4,5} A particular combination of nerve conduction study findings is characteristic. Median nerve motor amplitudes are very low, ulnar sensory amplitudes are low, ulnar motor amplitudes are equivocally low, and median sensory amplitudes are normal.^{4,6,7} Cervical spine radiographs usually show a cervical rib or elongated C7 transverse process. After exclusion of other entrapment neuropathies and cervical radiculopathy, the above noted physical findings and electrophysiological abnormalities are virtually diagnostic of classic NTOS.

The treatment of classic NTOS is not controversial.⁸ Through a neck incision, the cervical rib is removed or the abnormal cervical band is divided. Adjunctive operative procedures, such as scalenotomy, scalenectomy or first rib resection, are probably not required. Relief of sensory symptoms and arrest of progressive muscle weakness can be anticipated after surgical therapy. However, intrinsic hand muscle wasting usually does not improve.

Non-specific neurogenic thoracic outlet syndrome

Non-specific NTOS (disputed NTOS) is distinguished from classic NTOS by a lack of objective findings on neurological examination and elec-

Table I Classic neurogenic thoracic outlet syndrome

Diagnosis
Examination
Sensory loss, wasting of small muscles of hand
Nerve conduction
Reduced median motor and ulnar sensory amplitudes
Radiograph
Cervical rib or abnormal C7 transverse process
Treatment
Excision cervical rib and/or bands

Correspondence: J.D. Urschel, M.D., F.R.C.S.Ed., Division of Thoracic Surgery, Roswell Park Cancer Institute, Elm and Carlton Streets, Buffalo, New York 14263-0001, USA.

Accepted: 25 April 1994

trophysiological testing (Table II). The diagnosis and treatment of non-specific NTOS are the subject of extensive debate. There are no standard diagnostic criteria. Some investigators doubt its very existence,⁹ while others believe it to be a common cause of upper extremity complaints.²

Presumed pathogenesis of non-specific NTOS

The pathogenesis of non-specific NTOS is presumably related to compression of the brachial plexus across the 'thoracic outlet'.² Compression can occur in three areas of the thoracic outlet: interscalene triangle, costoclavicular space, and subcoracoid space (Figure 1). The first rib is common to both the interscalene triangle and costoclavicular space. Investigators have proposed a variety of pathophysiological theories to explain brachial plexus compression across the thoracic outlet. These theories fall into three major groups: congenital anomalies, postural factors and sequelae of trauma.

Congenital anomalies, such as cervical ribs and cervical bands, are essential pathophysiological features of classic NTOS. It seems plausible that these same anomalies can cause symptoms of nerve compression without necessarily producing objective neurological findings. Non-specific NTOS may share a common pathophysiology with classic NTOS but be less severe. Unlike classic NTOS, most patients with non-specific NTOS do not have cervical ribs or abnormal C7 transverse processes. Anomalous fibromuscular bands have reportedly been found in many surgical patients with a diagnosis of non-specific NTOS.¹⁰⁻¹² Congenital anomalies of the scalene muscles also may contribute to brachial plexus compression.^{13,14}

Postural factors, such as descent of the shoulder girdle in middle-aged adults, have been implicated in the pathophysiology of non-specific NTOS.¹⁵ Normal rib and muscle structures presumably cause brachial plexus compression in these cir-

cumstances. Proponents of therapeutic neck and shoulder girdle strengthening exercises support this aetiological theory.^{1,16}

Several authors have implicated 'whiplash' neck injuries in the aetiology of non-specific NTOS.^{17,18} Trauma-induced chronic muscle spasm allegedly causes brachial plexus compression. Histochemical and morphometric abnormalities consistent with chronic spasm have been found in scalenus anticus muscles removed from non-specific NTOS patients.^{19,20} The relationship between neck trauma and upper extremity symptoms may be complicated by issues of litigation and secondary gain.

Clinical presentation and investigation of non-specific NTOS

As with classic NTOS, patients with non-specific NTOS complain of pain and paraesthesiae along the medial forearm and hand. Some authors have attributed headache, neck pain, chest pain and almost any upper extremity complaint to non-specific NTOS. Neurological examination is unremarkable but other indicators of possible neurovascular thoracic outlet compression may be present.²¹ These physical examination tests may be grouped into three broad categories: shoulder girdle mani-

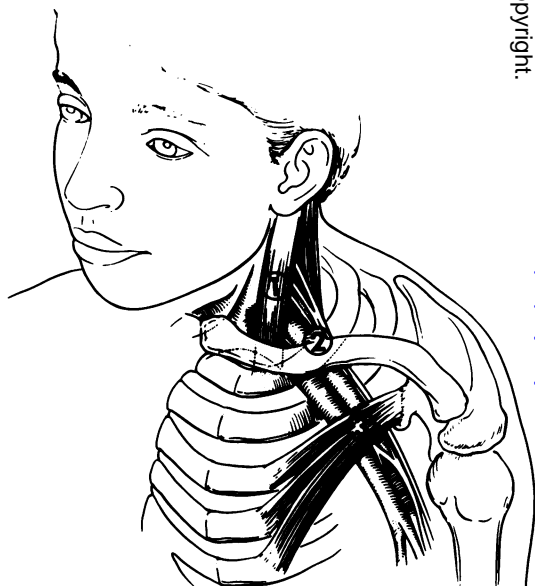


Figure 1 Three sites of possible nerve compression in non-specific neurogenic thoracic outlet syndrome: 1 = interscalene triangle – triangle of anterior scalene muscle, middle scalene muscle, and first rib; 2 = costoclavicular space – space between clavicle and first rib; 3 = subcoracoid space – space beneath pectoralis minor tendon. (Reproduced from Dyck, P.J. (ed.) *Peripheral Neuropathy*, 3rd edn, with permission of W.B. Saunders Company and Dr A.J. Wilbourn.)

Table II Non-specific neurogenic thoracic outlet syndrome

Diagnosis

Suggestive symptoms

Exclusion of other diagnoses

Normal neurological and electrophysiological examinations

Treatment

1. Conservative (most patients)

Reassurance

Physiotherapy

2. Surgery (selected patients)

Cervical rib excision (if present)

First rib resection (if no cervical rib)

Scalenectomy (an alternative to first rib resection)

pulations with decrease in radial artery pulse (Adson's test, hyperabduction test, military position test),²²⁻²⁴ exercise tests that reproduce symptoms (elevated arm stress test of Roos)¹⁰ and direct brachial plexus palpation that provokes symptoms (Spurling's sign).^{25,26} These physical examination manoeuvres lack specificity; they may be 'positive' in many normal subjects.²⁷ Approximately 50% of asymptomatic subjects have pulse deficits if provocative manoeuvres are vigorously performed.^{28,29}

Electrophysiological testing is critical to the diagnosis of most nerve entrapment syndromes, including classic NTOS, but electrophysiological testing is not diagnostic in non-specific NTOS. Ulnar nerve conduction velocity was promoted as a reliable diagnostic test^{2,30} but most investigators have had difficulty confirming its validity.^{4,31-33} Other electrophysiological tests, such as F-wave response latency,³⁴ somatosensory evoked potentials³⁴⁻³⁶ and dynamic positioning electrophysiological testing,³⁷ are not sufficiently useful to warrant routine use.³

Because of the difficulties with electrophysiological diagnosis of non-specific NTOS, vascular assessment has been advocated as an indirect indicator of general neurovascular compression across the thoracic outlet. Angiography,³⁷ photoplethysmography³⁸ and Doppler flow studies have been used.^{39,40} These investigations are of limited value in non-specific NTOS. As with the simpler Adson's test, many normal subjects show evidence of arterial compression with provocative arm positioning.³⁸

Radiographs of the neck may show cervical ribs in patients with non-specific NTOS. Cervical ribs are found in 1.5% of the general population⁴¹ but their presence in a patient with upper extremity symptoms supports a diagnosis of non-specific NTOS. Better delineation of subtle cervical transverse process abnormalities is possible with computed tomography but this modality has not been widely used.⁴² Early experience with magnetic resonance imaging (MRI) in various thoracic outlet syndromes is promising.⁴³ Fibrous bands and brachial plexus deviation have been shown in patients without cervical ribs. Further reports of the role of MRI in thoracic outlet syndrome investigation are awaited.

Psychological assessment is a neglected aspect of investigation.²¹ When compensation and litigation issues are present, secondary gain may influence severity and chronicity of symptoms.^{15,44} The Minnesota Multiphasic Personality Inventory has been used to assess non-specific NTOS patients.^{45,46} Personality abnormalities have been detected but the test has not consistently predicted response to surgical therapy.⁴⁶ Some investigators have reported a high incidence of somatization disorders in non-specific NTOS patients.^{44,47}

Investigation of non-specific NTOS is essentially a process of excluding other causes of upper extremity neurological symptoms.⁴⁰ Diagnoses such as cervical radiculopathy, carpal tunnel syndrome and musculoskeletal conditions must be excluded by appropriate history, examination, electrophysiological testing and radiographic investigation. Neurology consultation is mandatory, since most thoracic surgeons lack the necessary expertise to exclude subtle neurological abnormalities. In one series of carefully investigated subjects, 65% of patients with a presumptive diagnosis of non-specific NTOS who were referred to a thoracic surgery clinic were found to have other neurological or musculoskeletal conditions.⁴⁰

Treatment of non-specific NTOS

Considering the problems of defining and diagnosing non-specific NTOS, it is not surprising that treatment of this condition is controversial. Treatment should be as conservative as possible (Table II). Simple explanation of the syndrome and reassurance satisfies many patients. Shoulder girdle strengthening exercises may be prescribed; improvement is reported in 50-90% of patients.^{1,16,48,49} Surgery is reserved for failures of conservative management. Surgical approaches are directed towards a variety of normal and abnormal structures that are presumably important in nerve compression. Operations can be categorized into three major groups: cervical rib resection,²¹ first rib resection^{2,50} and scalenectomy (excision of scalenus anticus and medius muscles).¹⁷ These operations are sometimes combined, either through the same operative incision or, less commonly, through two separate incisions.^{13,51,52} Scalenotomy (simple division of scalenus anticus)^{22,53} may be a useful adjunctive procedure when done with other operations, but it has otherwise been abandoned as a NTOS operation.

If a cervical rib is present in a patient with non-specific NTOS, it is reasonable to presume that the pathophysiological processes that characterize classic NTOS are present, although to a lesser degree. The logical operation in this setting is cervical rib removal through a supraclavicular approach.²¹ Abnormal bands are also divided. In the absence of a cervical rib, first rib resection is a logical operation for non-specific NTOS.^{2,21} First rib resection decompresses both the interscalene and costoclavicular spaces. In addition, most anomalous compressive soft tissue structures arise or attach to the first rib. First rib resection is usually done through a transaxillary incision,^{2,50} but supraclavicular⁵⁴ and posterior approaches^{55,56} have proponents. Scalenectomy for non-specific NTOS is based on the trauma-scalene spasm aetiological

theory.¹⁷ The operation is done through a supraclavicular approach.

Brachial plexus injury is a rare, but extremely serious, complication of NTOS operations.⁵⁷⁻⁶² The intrinsic safety of the various operations is frequently debated.^{51,57,58} Most reported brachial plexus injuries have complicated transaxillary first rib resection, but this operation is also the most commonly performed procedure.⁶⁰⁻⁶² Nerve traction, from excessive arm retraction, is the usual mechanism of plexus injury. Traction injury is unique to the transaxillary approach; direct operative trauma is the mechanism of brachial plexus injury in the other thoracic outlet syndrome operations. The skill of the surgeon is probably more important in preventing plexus injuries than the operative approach.

The reported results of surgical treatment for non-specific NTOS are often difficult to interpret. Follow-up is usually short and assessment of treatment efficacy is subjective. Review of the surgical literature suggests that good results are obtained in approximately 75% of patients, irrespective of the operative approach used.^{13,46,51,63}

References

1. Peet, R.M., Henriksen, J.D., Anderson, T.P. & Martin, G.M. Thoracic-outlet syndrome: evaluation of a therapeutic exercise program. *Proc Mayo Clin* 1956, **31**: 281-287.
2. Urschel, H.C. Jr & Razzuk, M.A. Management of the thoracic-outlet syndrome. *N Engl J Med* 1972, **286**: 1140-1143.
3. Cuether, A.C. & Bartoszek, D.M. The thoracic outlet syndrome: controversies, overdiagnosis, overtreatment, and recommendations for management. *Muscle Nerve* 1989, **12**: 410-419.
4. Smith, T. & Trojaborg, W. Diagnosis of thoracic outlet syndrome: value of sensory and motor conduction studies and quantitative electromyography. *Arch Neurol* 1987, **44**: 1161-1163.
5. Gilliatt, R.W., Le Quesne, P.M., Logue, V. & Sumner, A.J. Wasting of the hand associated with a cervical rib or band. *J Neurol Neurosurg Psychiatry* 1970, **33**: 615-624.
6. Gilliatt, R.W., Willison, R.G., Dietz, V. & Williams, I.R. Peripheral nerve conduction in patients with a cervical rib and band. *Ann Neurol* 1978, **4**: 124-129.
7. Wilbourn, A.J. & Porter, J.M. Thoracic outlet syndromes. In: Weiner, M.A. (ed.) *Spine: State of the Art Reviews*. Hanley and Belfus, Philadelphia, 1988, pp. 597-626.
8. Hardy, R.W., Jr, Wilbourn, A. & Hanson, M. Surgical treatment of compressive cervical band. *Neurosurgery* 1980, **7**: 10-13.
9. Wilbourn, A.J. The thoracic outlet syndrome is overdiagnosed. *Arch Neurol* 1990, **47**: 328-330.
10. Roos, D.B. Congenital anomalies associated with thoracic outlet syndrome. Anatomy, symptoms, diagnosis, and treatment. *Am J Surg* 1976, **132**: 771-778.
11. Roos, D.B. New concepts of thoracic outlet syndrome that explain etiology, symptoms, diagnosis and treatment. *Vasc Surg* 1979, **13**: 313-321.
12. Pang, D. & Wessel, H.B. Thoracic outlet syndrome. *Neurosurgery* 1988, **22**: 105-121.
13. Roos, D.B. The place for scalenectomy and first-rib resection in thoracic outlet syndrome. *Surgery* 1982, **92**: 1077-1085.
14. Thomas, G.I., Jones, T.W., Stavney, S.L. & Manhas, D.R. The middle scalene muscle and its contribution to the thoracic outlet syndrome. *Am J Surg* 1983, **145**: 589-592.
15. Lord, J.W. Jr & Rosati, L.M. Thoracic-outlet syndromes. *Clin Symp* 1972, **24**: 1-32.
16. Kenny, R.A., Traynor, G.B., Withington, D. & Keegan, D.J. Thoracic outlet syndrome: a useful exercise treatment option. *Am J Surg* 1993, **165**: 282-284.
17. Sanders, R.J., Monsour, J.W., Gerber, W.F., Adams, W.R. & Thompson, N. Scalenectomy versus first rib resection for treatment of the thoracic outlet syndrome. *Surgery* 1979, **85**: 109-121.
18. Roos, D.B. Thoracic outlet syndromes: update 1987. *Am J Surg* 1987, **154**: 568-573.
19. Machleder, H.I., Moll, F. & Verity, M.A. The anterior scalene muscle in thoracic outlet compression syndrome. Histochemical and morphometric studies. *Arch Surg* 1986, **121**: 1141-1144.
20. Sanders, R.J., Jackson, C.G.R., Banchemo, N. & Pearce, W.H. Scalene muscle abnormalities in traumatic thoracic outlet syndrome. *Am J Surg* 1990, **159**: 231-236.
21. Luoma, A. & Nelems, B. Thoracic outlet syndrome. Thoracic surgery perspective. *Neurosurg Clin North Am* 1991, **2**: 187-226.
22. Adson, A.W. & Coffey, J.R. Cervical rib; method of anterior approach for relief of symptoms by division of scalenus anticus. *Ann Surg* 1927, **85**: 839-857.
23. Wright, I.S. Neurovascular syndrome produced by hyperabduction of the arms. *Am Heart J* 1945, **29**: 1-19.
24. Falconer, M.A. & Li, F.W.P. Resection of the first rib in costoclavicular compression of the brachial plexus. *Lancet* 1962, **i**: 59-63.
25. McGough, E.C., Pearce, M.B. & Bryne, J.P. Management of thoracic outlet syndrome. *J Thorac Cardiovasc Surg* 1979, **77**: 169-174.
26. Spurling, R.G. & Bradford, F.K. Scalenus neurocirculatory compression. *Ann Surg* 1938, **107**: 708-715.

Ten-year follow-up shows good results in approximately 65% of patients.⁵¹ Most reports of poor results are found in the neurology literature.⁵⁸⁻⁶¹ Poor outcomes are usually associated with diagnostic errors and inappropriate surgery.^{46,64}

Summary of neurogenic thoracic outlet syndromes

Classic NTOS is rare entity with specific defining electrophysiological and physical examination findings. A cervical rib or anomalous cervical band is usually present. Surgical excision of the cervical rib or band relieves symptoms and stops progressive brachial plexus injury.

Non-specific NTOS probably does exist but its incidence is much lower than some proponents report. In a patient with symptoms suggesting classic NTOS, but lacking objective evidence of classic NTOS, the diagnosis of non-specific NTOS can be made after exclusion of other conditions. Operative treatment is reserved for failures of conservative management. Good surgical results are dependent on careful patient selection.

27. Costigan, D.A. & Wilbourn, A.J. The elevated arm stress test: specificity in the diagnosis of thoracic outlet syndrome. *Neurology* 1985, **35** (Suppl 1): 74–75.
28. Telford, E.D. & Mottershead, S. Pressure at the cervico-brachial junction: an operative and anatomic study. *J Bone Joint Surg B* 1948, **30**: 249–265.
29. Warrens, A.N. & Heaton, J.M. Thoracic outlet compression syndrome: the lack of reliability of its clinical assessment. *Ann R Coll Surg Engl* 1987, **69**: 203–204.
30. Caldwell, J.W., Crane, C.R. & Krusen, E.M. Nerve conduction studies: an aid in the diagnosis of the thoracic outlet syndrome. *South Med J* 1971, **64**: 210–212.
31. Cherington, M. Ulnar conduction velocity in thoracic-outlet syndrome. *N Engl J Med* 1976, **294**: 1185–1186.
32. Shahani, B.T., Potts, F., Juguilon, A. & Young, R.R. Electrophysiological studies in 'thoracic outlet syndrome'. *Muscle Nerve* 1980, **3**: 182–183.
33. Wilbourn, A.J. & Lederman, R.J. Evidence for conduction delay in thoracic-outlet syndrome is challenged. *N Engl J Med* 1984, **310**: 1052–1053.
34. Jerrett, S.A., Cuzzone, L.J. & Pasternak, B.M. Thoracic outlet syndrome. Electrophysiologic reappraisal. *Arch Neurol* 1984, **41**: 960–963.
35. Machleder, H.I., Moll, F., Nuwer, M. & Jordan, S. Somatosensory evoked potentials in the assessment of thoracic outlet compression syndrome. *J Vasc Surg* 1987, **6**: 177–184.
36. Veilleux, M., Stevens, J.C. & Campbell, J.K. Somatosensory evoked potentials: lack of value for diagnosis of thoracic outlet syndrome. *Muscle Nerve* 1988, **11**: 571–575.
37. Sadler, T.R., Rainer, W.G. & Twombly, G. Thoracic outlet compression. Application of positional arteriographic and nerve conduction studies. *Am J Surg* 1975, **130**: 704–705.
38. Gergoudis, R. & Barnes, R.W. Thoracic outlet arterial compression: prevalence in normal persons. *Angiology* 1980, **31**: 538–541.
39. Pisko-Dubienski, Z.A. & Hollingsworth, J. Clinical application of Doppler ultrasonography in the thoracic outlet syndrome. *Can J Surg* 1978, **21**: 145–150.
40. Sobey, A.V.F., Grewal, R.P., Hutchison, K.J. & Urschel, J.D. Investigation of nonspecific neurogenic thoracic outlet syndrome. *J Cardiovasc Surg* 1993, **34**: 343–345.
41. Felson, B. A review of 30,000 normal chest roentgenograms. In: Felson, B. (ed.) *Chest Roentgenology*. W.B. Saunders, Philadelphia, 1973, p. 494.
42. Bilbey, J.H., Muller, N.L., Connell, D.G., Luoma, A.A. & Nelems, B. Thoracic outlet syndrome: evaluation with CT. *Radiology* 1989, **171**: 381–384.
43. Panegyres, P.K., Moore, N., Gibson, R., Rushworth, G. & Donaghy, M. Thoracic outlet syndromes and magnetic resonance imaging. *Brain* 1993, **116**: 823–841.
44. Youmans, C.R., Jr & Smiley, R.H. Thoracic outlet syndrome with negative Adson's and hyperabduction maneuvers. *Vasc Surg* 1980, **14**: 318–329.
45. Snider, H.C. & King, G.D. Minnesota Multiphasic Personality Inventory as a predictor of operative results in thoracic outlet syndrome. *South Med J* 1986, **79**: 1527–1530.
46. Wood, V.E., Twito, R. & Verska, J.M. Thoracic outlet syndrome. The results of first rib resection in 100 patients. *Orth Clin North Am* 1988, **19**: 131–146.
47. Nelson, D.A. TOS = TMJ: true or false? *Del Med J* 1989, **61**: 339–340.
48. Dale, W.A. & Lewis, M.R. Management of thoracic outlet syndrome. *Ann Surg* 1975, **181**: 575–585.
49. Smith, K.F. The thoracic outlet syndrome: a protocol of treatment. *J Orth Sports Phys Ther* 1979, **1**: 89–99.
50. Roos, D.B. & Owens, J.C. Thoracic outlet syndrome. *Arch Surg* 1966, **93**: 71–74.
51. Sanders, R.J. & Pearce, W.H. The treatment of thoracic outlet syndrome: a comparison of different operations. *J Vasc Surg* 1989, **10**: 626–634.
52. Qvarfordt, P.G., Ehrenfeld, W.K. & Stoney, R.J. Supraclavicular radical scalenectomy and transaxillary first rib resection for the thoracic outlet syndrome. A combined approach. *Am J Surg* 1984, **148**: 111–116.
53. Oshsner, A., Gage, M. & DeBakey, M. Scaleneus anticus (Naffziger) syndrome. *Am J Surg* 1935, **28**: 669–695.
54. Hempel, G.K., Rusher, A.H., Jr, Wheeler, C.G., Hung, D.G. & Bukhari, H.I. Supraclavicular resection of the first rib for thoracic outlet syndrome. *Am J Surg* 1981, **141**: 213–215.
55. Clagett, O.T. Research and prosearch. *J Thorac Cardiovasc Surg* 1962, **44**: 153–166.
56. Johnson, C.R. Treatment of thoracic outlet syndrome by removal of first rib and related entrapments through posterolateral approach: a 22 year experience. *J Thorac Cardiovasc Surg* 1974, **68**: 536–545.
57. Dale, W.A. Thoracic outlet compression syndrome: critique in 1982. *Arch Surg* 1982, **117**: 1437–1445.
58. Horowitz, S.H. Brachial plexus injuries with causalgia resulting from transaxillary rib resection. *Arch Surg* 1985, **120**: 1189–1191.
59. Cherington, M., Happer, I., Machanic, B. & Parry, L. Surgery for thoracic outlet syndrome may be hazardous to your health. *Muscle Nerve* 1986, **9**: 632–634.
60. Wilbourn, A.J. Thoracic outlet syndrome surgery causing severe brachial plexopathy. *Muscle Nerve* 1988, **11**: 66–74.
61. Fredericks, E.J. Brachial plexopathy complicating thoracic outlet syndrome surgery. *Muscle Nerve* 1988, **11**: 1090.
62. Ferguson, T.B. The crisis of excellence. *J Thorac Cardiovasc Surg* 1982, **84**: 161–171.
63. Sellke, F.W. & Kelly, T.R. Thoracic outlet syndrome. *Am J Surg* 1988, **156**: 54–57.
64. Lord, J.W., Jr. Critical reappraisal of diagnostic and therapeutic modalities for thoracic outlet syndromes. *Surg Gynecol Obstet* 1989, **168**: 337–340.