

# Gastric antral vascular ectasia (watermelon stomach) – therapeutic options

R.H.R. Park<sup>1</sup>, B.J.Z. Danesh<sup>1</sup>, R. Upadhyay<sup>1</sup>, A.G. Howatson<sup>2</sup>,  
F.D. Lee<sup>2</sup> and R.I. Russell<sup>1</sup>

<sup>1</sup>Gastroenterology Unit and <sup>2</sup>Department of Pathology, Royal Infirmary, Glasgow G31 2ER, UK.

**Summary:** We have encountered five cases of chronic iron deficiency anaemia due to bleeding from gastric antral vascular ectasia (watermelon stomach). Two cases were associated with a lymphoma and in three cases there was evidence of portal hypertension. Two patients were treated conservatively by blood transfusions. The other patients required either surgery or tranexamic acid or endoscopic laser therapy to control the chronic haemorrhage.

## Introduction

In recent years, gastrointestinal mucosal vascular abnormalities have been recognized as significant causes of upper gastrointestinal bleeding.<sup>1</sup> Jabbari *et al.*<sup>2</sup> coined the term 'watermelon stomach' to describe the endoscopic appearances of longitudinal antral folds containing visible columns of vessels in three patients presenting with chronic iron deficiency anaemia due to gastrointestinal haemorrhage. The histological findings included hyperplasia of the antral mucosa, dilated mucosal capillaries, focal thrombosis and fibromuscular hypertrophy of the lamina propria. Two previous reports of four cases also fulfilled this diagnosis.<sup>3,4</sup> Since then several other reports have appeared with similar clinical, endoscopic and histological findings.<sup>5–11</sup> We have recently encountered five cases of gastric antral vascular ectasia; two of these cases were associated with a lymphoma, a combination of disorders which has not previously been reported.

## Case reports

### Case 1

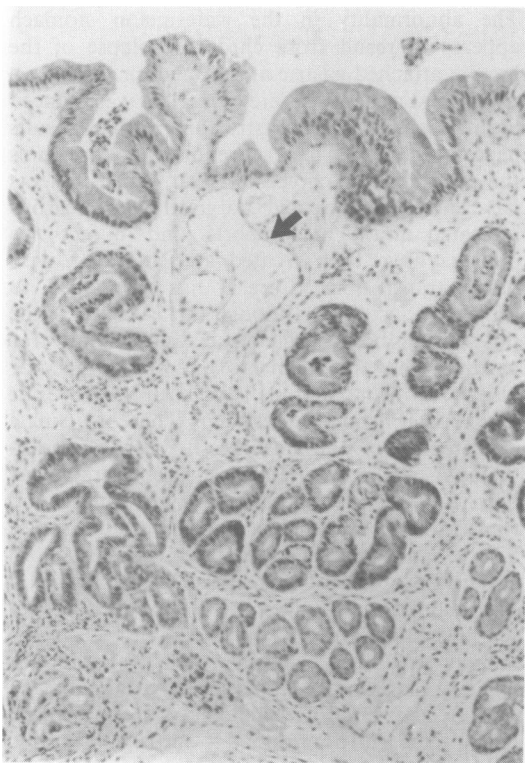
This 75 year old woman presented with a 9-month history of lethargy. She had no gastrointestinal symptoms and had not been taking any drugs. Clinical examination was normal. The haemoglobin was 9 g/dl with normal indices. Bone mar-

row examination showed absent iron stores and a lymphoid infiltrate. Multiple faecal occult blood tests were positive. Extensive investigations revealed 'slight antral gastritis' and splenomegaly. She required blood transfusions every 4 weeks. Her gastrointestinal blood loss was found to be 31.4 ml/day (<sup>51</sup>Cr method, normal range < 1 ml/day). Repeat endoscopies were described as showing 'diffuse haemorrhagic antral gastritis', and biopsies showed vascular ectasia, microthrombi, fibromuscular hyperplasia and a lymphoid infiltrate (Figure 1). A partial gastrectomy was performed as her blood loss was excessive and a gastric lymphoma was suspected. At laparotomy she had splenomegaly with enlarged splenic vessels. Histology of the resected specimen showed features of antral vascular ectasia and also a B cell low grade lymphoma. Over the next 18 months she has required only one blood transfusion.

### Case 2

This 86 year old woman presented with a 3-year history of iron deficiency anaemia requiring transfusion of 8 units of blood. She was noted to have a hard mass in the left iliac fossa. Upper gastrointestinal endoscopy showed severe haemorrhagic antral gastritis and biopsies were in keeping with a diagnosis of watermelon stomach. Barium enema and colonoscopy revealed a possible extraluminal narrowing in the sigmoid colon. Computed tomographic (CT) scan of her abdomen showed that the mass was due to mesenteric lymphadenopathy, with other intra-abdominal lymphadenopathy, suggestive of a lymphoma. The patient refused further investigation and has remained well for a year.

Correspondence: R.H.R. Park, M.R.C.P. (UK),  
1 Douglas Gardens, Glasgow G46 6NY, UK  
Accepted: 5 March 1990



**Figure 1** Gastric antral biopsy in Case 1. Superficially placed ectatic vascular channel (broad arrow). Fibromuscular thickening in the lamina propria. Haematoxylin and eosin  $\times 24$ .

### Case 3

A 49 year old woman was admitted complaining of abdominal and leg swelling, and dyspnoea. She admitted to a heavy alcohol intake for many years. She had stigmata of chronic liver disease and marked fluid overload with ascites, peripheral oedema and right pleural effusion. Laboratory

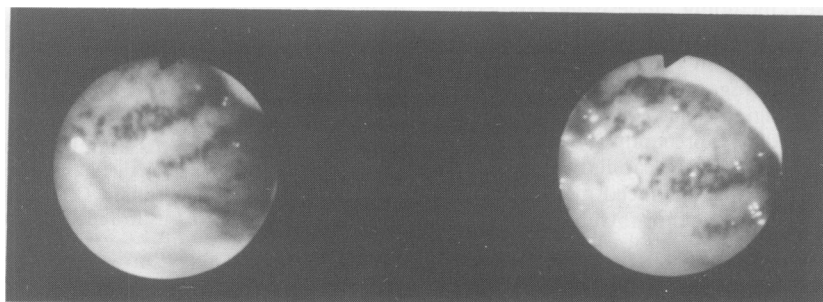blood tests and an upper abdominal ultrasound were compatible with a diagnosis of alcoholic liver disease and portal hypertension. However, a liver biopsy was contraindicated in view of a marked coagulopathy. The haemoglobin on admission was 6.3 g/dl, with iron deficiency features. Over 2 months she required 20 units of blood due to recurring gastrointestinal haemorrhage. Several endoscopies showed diffuse haemorrhagic antral mucosa and no evidence of oesophageal varices. An antral biopsy was done using diathermy, which showed dilated capillaries with microthrombi. The gastrointestinal haemorrhage has been reduced using tranexamic acid.

### Case 4

This 82 year old man presented with prostatic hypertrophy and was found to have an iron deficiency anaemia of 9.1 g/dl. He had been treated for pernicious anaemia. Endoscopy showed longitudinal folds of dilated vessels in the antrum radiating to the pylorus (Figure 2). The columns of vessels blanched on pressure with the biopsy forceps. Antral biopsy was in keeping with 'watermelon stomach'. His iron deficiency anaemia responded to oral iron. One year after presentation he has not required a blood transfusion.

### Case 5

A 42 year old woman, who had a history of primary biliary cirrhosis (PBC) was admitted for investigation of iron deficiency anaemia (haemoglobin 5.8 g/dl). Her faeces were persistently positive for occult blood. Initial endoscopy showed oesophageal varices and 'antral gastritis'. At repeat endoscopy the mucosal appearances were recognized to have typical features of antral vascular ectasia, confirmed by biopsy. The varices were injected until virtual obliteration. However, she continued to require blood transfusions of 3–4 units every



**Figure 2** Endoscopic photograph of gastric antrum showing longitudinal folds of dilated vessels radiating from the pylorus. Case 4.

3–4 weeks. Long term treatment with ranitidine and sucralfate did not influence her blood transfusion requirements nor alter the antral appearances. Antrectomy was avoided as she may be a candidate for liver transplantation. She underwent 6 sessions of Nd-YAG laser photocoagulation (Fiberlaser 100, Pilkington). At each session she received between 36–108 pulses (one second) using between 20 and 50 Watts. The vascular ectasia disappeared and she did not require blood transfusion over an 8-month follow-up period.

## Discussion

Although our first three cases had diffuse haemorrhagic antral gastritis rather than the 'watermelon stripes', previous reports have described similar appearances.<sup>2,11,12</sup> With several of our cases there was delay in reaching the diagnosis due to failure in recognizing this problem. Vascular ectasia should be suspected in cases of localized abnormality of the gastric antrum and a biopsy taken, which will demonstrate specific histological features not seen with other vascular abnormalities of the stomach and duodenum.

Watermelon stomach appears to be a distinct vascular abnormality of the gastric antrum. Several terms have been used to describe other discrete mucosal vascular abnormalities. Gilmour suggested that 'angiodyplasia' should be used, describing such a lesion as 'sharply delineated, red mucosal lesion with a flat or slightly raised surface; histological examination reveals dilated thin walled mucosal blood vessels.'<sup>13</sup> Unlike the watermelon stomach, angiodyplasia can be found throughout the upper gastrointestinal tract, although usually located in the proximal stomach or antrum.<sup>1</sup> Several conditions, including chronic renal failure, aortic stenosis and connective tissue diseases, have been associated with angiodyplasia. Similar lesions are found in hereditary haemorrhagic telangiectasia. In the majority of cases angiodyplasias appear to be acquired. Several theories have been proposed including underlying connective tissue disorder, reduced cardiac output and cholesterol emboli in aortic stenosis and degenerative thinning of the mucosa. Gilmour suggested that angiodyplasia could be produced by malfunction of the precapillary sphincters resulting in hyperfusion of the capillaries and dilatation. Bleeding could be produced by intraluminal trauma such as gastric acid or intraluminal food.<sup>13</sup>

The abnormality in the watermelon stomach appears to result from chronic prolapse of the loosely attached gastric antral mucosa.<sup>2</sup>

Our first patient's severe blood loss was reduced dramatically by partial gastrectomy. Similar results have been achieved in other reports, and it remains the treatment of choice.<sup>2,6,10</sup> Our other patients have not been treated surgically for reasons indicated in the case reports, and in fact two patients have been treated conservatively with blood transfusions. Case 3 has responded to tranexamic acid and although this is the first time this drug has been used it may be useful therapy for patients who are unable to undergo surgery or other treatment. Steroids have been used in four patients with some success.<sup>2,4,6,10</sup> There is a single case report of the unsuccessful use of radiotherapy.<sup>3</sup> Recently endoscopic laser therapy has been found to be successful in reducing blood transfusion requirements, as we found in case 5.<sup>14–16</sup> Endoscopic sclerotherapy using alcohol<sup>17</sup> and heat probe therapy have also been described.<sup>18</sup> The main disadvantages are the frequent endoscopy sessions and the likelihood of recurrence. Similar treatment options are available for angiodyplasia of the upper gastrointestinal tract. Lesions associated with hereditary haemorrhagic telangiectasia do not respond to oestrogen therapy, unlike nasal lesions.

The occurrence of two rare conditions, watermelon stomach and lymphoma, in two of our patients raises the possibility of a previously unrecognized relationship. However, there have been no other reports of gastric antral vascular ectasia and lymphoma. The histological specimens of 12 other cases of gastric lymphoma diagnosed at this hospital over the past 10 years have been reviewed but did not show any histological changes of antral vascular ectasia.

Previous reports of watermelon stomach have included patients with chronic liver disease.<sup>2,3,9–11</sup> In our series three patients had evidence of portal hypertension. Antral vascular ectasia may be another example of gastric mucosal vasculopathy in portal hypertension.<sup>19</sup>

## Acknowledgements

We would like to thank Miss Ruth Berry for secretarial assistance, Dr Eric Boyd for the management of case 3 and Dr M. Soukop, Consultant Oncologist. Dr John Davidson kindly allowed us to report case 4.

## References

- Weaver, G.A., Alpern, H.D., Davis, J.S. *et al.* Gastrointestinal angiodysplasia associated with aortic valve disease: part of a spectrum of angiodysplasia of the gut. *Gastroenterology* 1979, **77**: 1–11.
- Jabbari, M., Cherry, R., Lough, J.O. *et al.* Gastric antral vascular ectasia: the watermelon stomach. *Gastroenterology* 1984, **87**: 1165–1170.
- Wheeler, M.H., Smith, P.M., Cotton, P.B. *et al.* Abnormal blood vessels in the gastric antrum – a cause of upper gastrointestinal bleeding. *Dig Dis Sci* 1979, **24**: 155–158.
- Calam, J. & Walker, R.J. Antral vascular lesion, achlorhydria, and chronic gastrointestinal blood loss. *Dig Dis Sci* 1980, **25**: 236–239.
- Cairns, H.S., Rees, H. & Bevan, G. Iron deficiency anaemia, gastritis and antral vascular malformation. *J R Soc Med* 1986, **79**: 46–47.
- Rawlinson, W.D., Barr, G.D. & Lin, B.P.C. Antral vascular ectasia the watermelon stomach. *Med J Aust* 1986, **144**: 709–711.
- Gardiner, G.W., Murray, D. & Prokipchut, E.J. Watermelon stomach or antral gastritis. *J Clin Pathol* 1985, **38**: 1317–1318.
- Tovey, F.I. Gastric antral vascular ectasia: the watermelon stomach. *Gastroenterology* 1985, **88**: 1293.
- Hunt, R.H. Angiodysplasia of the gut. In: Bouchier, I.A.D., Allan, R.N., Hodgson, H.J.F. & Keighly, M.R.B. (eds) *Textbook of Gastroenterology*, 1st edition. Bailliere Tindall, London, 1984, p. 259.
- Kruger, R., Ryan, M.E., Dickson, K.B. & Nunez, J.F. Diffuse vascular ectasia of the gastric antrum. *Am J Gastroenterol* 1987, **82**: 421–426.
- Lee, F.I., Costello, F., Flanagan, N. & Vasudev, K.S. Diffuse antral vascular ectasia. *Gastrointest Endosc* 1984, **30**: 87–90.
- Rider, J.A., Klotz, I.A.P. & Kirsner, J.B. Gastritis with veno-capillary ectasia as a source of massive gastric haemorrhage. *Gastroenterology* 1953, **24**: 118–123.
- Gilmore, P.R. Angiodysplasia of the upper gastrointestinal tract. *J Clin Gastroenterol* 1988, **10**: 386–394.
- Wolf, D.C. & Brooks, W.S. Antral vascular ectasia of cirrhosis: endoscopic laser therapy. *Gastrointest Endosc* 1986, **32**: 139–140.
- Frager, J.D., Brandt, L.J., Frank, M.S. & Moreck, R. Treatment of a patient with watermelon stomach using transendoscopic laser photocoagulation. *Gastrointest Endosc* 1988, **34**: 134–137.
- Attar, A., Hellman, R. & Obial, G. Watermelon stomach, a true entity and a cause of gastrointestinal bleed. *Gastrointest Endosc* 1988, **34**: 172–173.
- Rose, J.D.R. Endoscopic injection of alcohol for bleeding from gastrointestinal vascular abnormalities. *Br Med J* 1987, **295**: 93–94.
- Petrini, J.L. & Johnston, J.H. Heat probe treatment for antral vascular ectasia. *Gastrointest Endosc* 1989, **35**: 324–328.
- Sarfeh, I.J. & Tarnawski, A. Gastric mucosal vasculopathy in portal hypertension. *Gastroenterology* 1987, **93**: 1129–1131.