

Difficult Decisions

Solitary thyroid nodule – what to do?

V.K Kapoor¹ and S.S. Sikora²

¹Department of Surgical Gastroenterology Sanjay Gandhi, Postgraduate Institute of Medical Sciences, Lucknow 226001 and ²Department of Surgery, All India Institute of Medical Sciences, New Delhi – 110029, India.

Solitary thyroid nodule (STN) is a common clinical entity. The majority of STNs are benign – the incidence of carcinoma being only 10–20%.^{1,2} The ideal investigation for STN should differentiate between benign and malignant nodules so that the percentage of thyroid operations for cancer increases and unnecessary surgery for benign nodules is avoided.

Clinical features of a thyroid nodule are poor predictors of malignancy. Thyroid cancers may be slow growing whereas a benign nodule may rapidly enlarge and become painful because of haemorrhage. Local obstructive symptoms are non-specific and may be associated with benign as well as malignant nodules. A thyroid nodule in an elderly male, coming from an area non-endemic for goitre, history of exposure to ionising radiation and family history of medullary carcinoma should make the clinician suspicious. Enlarged cervical lymph nodes are an important indicator of malignancy.

Biochemical tests of thyroid function have no role in the work-up of a STN except to confirm borderline hyperfunction or when the patient has obvious

hyperthyroidism, as a baseline for follow-up after treatment. Radioisotope scan visualizes the nodule as cold (no uptake of isotope by the nodule), warm (normal uptake of isotope by the nodule) or hot (increased uptake of isotope by the nodule with suppression of the surrounding normal gland). Although 90% of the malignant nodules are cold,³ 85–90% of the cold nodules are benign³ and the radioisotope scan does not differentiate between benign and malignant cold nodules. A well differentiated carcinoma may take up isotope (warm nodule) and a hot nodule does not rule out malignancy. In some cases, however, the radioisotope scan may reveal a STN to be merely the prominent nodule in a multinodular goitre in which case the incidence of carcinoma is even less. Ultrasound scan differentiates between cystic and solid nodules but a cyst does not rule out malignancy and not all solid nodules are malignant.

Fine needle aspiration cytology (FNAC) can differentiate between cystic and solid nodules. Up to 15–25% of all STNs are cysts.^{4,5} A cyst should be

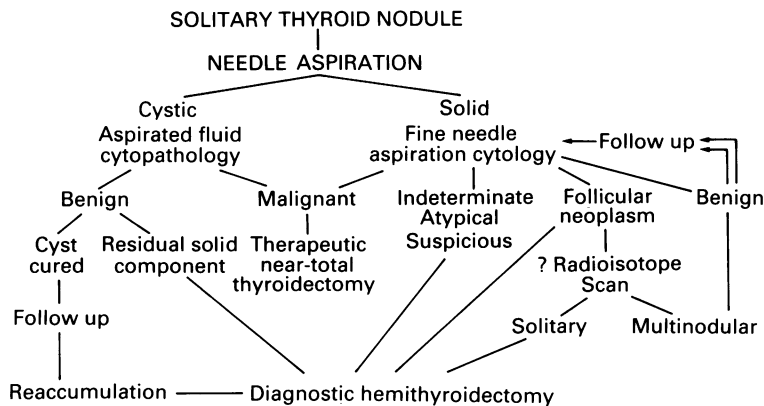


Figure 1 Solitary thyroid nodule.

Correspondence: V.K. Kapoor, M.S., D.N.B.E., M.N.A.M.S.
Accepted: 8 March 1989

aspirated and the aspirated fluid examined cytopathologically. Aspiration cures 20–70% of the cysts.^{6,7} Reaccumulations of benign cysts can be aspirated and sclerotherapy with sodium tetradecyl sulphate⁶ or tetracycline⁷ has been described but operative treatment is recommended.⁸ In mixed cystic-solid nodules (residual solid component after aspiration), the aspirated fluid is not representative of the epithelial component and incidence of malignancy is higher – surgery is therefore recommended.

More importantly, FNAC may identify a nodule as benign or malignant. The benign nodules on FNAC (adenomatous goitre, thyroiditis) may be followed-up with repeat FNACs. Treatment with replacement doses of thyroxine (0.2–0.3 mg/day) for a period of 6 months is prescribed as suppression of thyrotrophin release by thyroxine is presumed to shrink the nodule. Radioisotope scan is essential before starting suppression to rule out an autonomous nodule because administration of exogenous thyroxine in these patients may cause cardiac complications.⁹ In a prospective controlled trial comparing suppression treatment with placebo for STNs, there was however, no significant reduction in the size of the nodule.¹⁰ FNAC may identify the type of malignancy and help in planning the surgical treatment, for example near total thyroidectomy for primary thyroid carcinoma (papillary and rarely anaplastic), necessary investigations for a coexisting pheochromocytoma in medullary carcinoma or avoiding surgery e.g. in lymphoma and metastatic carcinoma. It is easy to perform and safe and is cost effective by avoiding radioisotope and ultrasound scans. A false-negative result is the major limitation of FNAC, the incidence is, however, less

than 10%.^{11,12} Also FNAC can not differentiate follicular adenoma from a follicular carcinoma because the mitotic activity of the two is similar and histopathological examination of the entire specimen for vascular and capsular invasion is essential. A necessary pre-requisite for FNAC, of course, is the availability of a highly skilled and experienced cytopathologist.

Radioisotope and ultrasound scans in a patient with STN are of not much help to the surgeon and FNAC should be the initial diagnostic step. Benign nodules are followed-up with repeat FNACs. Malignant nodules undergo therapeutic near-total thyroidectomy whereas a diagnostic hemithyroidectomy is performed for suspicious, atypical or indeterminate lesions. In patients with follicular pattern on FNAC, a radioisotope scan may show that the STN is part of a multinodular goitre in which case the patient may be followed up or else a diagnostic hemithyroidectomy is indicated. Cosmetic disfigurement, obstructive symptoms and hyperfunction may also indicate operative treatment. This approach of selective thyroid surgery increases the cancer incidence although a few cancers will be missed (false-negative FNAC). Many of these missed cancers are likely to be detected during the follow-up when repeat FNACs are performed (Figure 1). The risk of missing these cancerous STNs is also questionable considering the slow growing nature and better prognosis of solitary nodular carcinoma.¹³ The only certain way not to miss any cancer is to operate upon all STNs; this would result in unnecessary operation for the majority of the patients who have benign nodules and is neither desirable nor preferable to selective thyroid surgery.

References

- Liechty, R.D., Stoffel, P.T., Zimmerman, D.E. & Silverberg, S.G. Solitary thyroid nodules. *Arch Surg* 1977, **112**: 59–61.
- Brooks, J.R. The solitary thyroid nodule. *Am J Surg* 1973, **125**: 477–481.
- Ashcraft, M.W. & Van Herle, A.J. Management of thyroid nodules. II Scanning techniques, thyroid suppressive therapy and fine needle aspiration. *Head Neck Surg* 1981, **3**: 297–322.
- Ma, M.K.G. & Ong, G.B. Cystic thyroid nodules. *Br J Surg* 1979, **62**: 205–206.
- Walsh, P.G., Hazani, E., Strawbridge, H.T.G., Miskin, M. & Rosen, I.B. A prospective study of combined ultrasonography and needle aspiration biopsy in the assessment of the hypofunctioning thyroid nodule. *Surgery* 1977, **82**: 474–482.
- Rojeski, M.T. & Hharib, H. Nodular thyroid disease, evaluation and management. *N Engl J Med* 1985, **313**: 428–436.
- DeYoung, J.P., Kahn, A., Levman, S. & Ferenczy, A.S. Tetracycline instillation for recurrent cystic thyroid nodules. *Can J Surg* 1986, **29**: 118–119.
- Toft, A.D. Thyroid enlargement. *Br Med J* 1985, **290**: 1066–1068.
- Miller, J.M. Evaluation of thyroid nodules. Recent advances on needle biopsy. *Med Clin North Am* 1985, **69**: 1063–1077.
- Gharib, H., James, E.M., Charboneau, J.W., Naessens, J.M., Offord, K.P. & Gorman, C.A. Suppressive therapy with levothyroxine for solitary thyroid nodules. A double-blind controlled clinical study. *N Engl J Med* 1987, **317**: 30–35.

11. Lowhagen, T., Willems, J.S., Lundell, G., Sundblad, R. & Grandberg, P.O. Aspiration biopsy cytology in the diagnosis of thyroid cancer. *World J Surg* 1981, **5**: 61–73.
12. Anderson, J.B. & Webb, A.J. Fine needle aspiration biopsy and the diagnosis of thyroid cancer. *Br J Surg* 1987, **74**: 292–296.
13. Kapur, M.M., Sarda, A.K., Bal, S. & Sood, S. Carcinoma of the thyroid differential behaviour in solitary and multinodular goitres. *Br J Surg* 1986, **73**: 894–895.