

## Clinical Toxicology

# Toxic reaction to inhaled paint fumes

L. Atkinson, P. Ince, N.M. Smith and R. Taylor

Royal Victoria Infirmary, Newcastle upon Tyne NE1 4LP, UK.

**Summary:** An acute confusional state was observed to follow heavy exposure to polyurethane gloss paint fumes in a previously healthy 60 year old man. This state remitted over a 3-day period, but was followed by transient bone marrow suppression and evidence of liver cell damage. The corroborated absence of other toxins and the temporal association of exposure to paint fumes suggest that a volatile paint component was responsible. White spirit is the major volatile solvent in polyurethane gloss paint. Ingestion of related aliphatic hydrocarbons has been reported to cause nausea, drowsiness and hepatotoxicity, but these symptoms have not previously been documented following excessive inadvertent inhalation of paint fumes.

### Introduction

It is common knowledge that prolonged exposure to gloss paint fumes may induce transient nausea. There are however no well-documented cases of serious illness resulting from such exposure. We report a case of hepatotoxicity, bone marrow suppression and encephalopathy following painting in a small, non-ventilated room.

### Case report

A 60 year old man was admitted to hospital confused and pyrexial. He had been perfectly well up to 30 hours prior to admission when he had spent approximately one hour painting large surfaces with Dulux polyurethane gloss in a small, non-ventilated bathroom. Immediately afterwards he complained of malaise and anorexia and appeared pale and unwell. He retired to bed and spent a very restless night and was noted to be coughing. On rising about 19 hours later he was unsteady on his feet and returned to bed. The cough continued and he slept fitfully, often shouting in his sleep. After a further 6 hours he rose, was very uncoordinated and complained of a headache. He then fell downstairs and was unrousable for about five minutes. Thereafter he was aggressive and confused.

There was no recent drug or alcohol consumption or exposure to chemicals other than paint, but he drank 30 units of alcohol weekly.

On admission he had a temperature of 40°C, and a left periorbital haematoma. He was drowsy with no memory for recent events though was well orientated. There were no signs of chronic liver disease or jaundice, but 3 cm hepatomegaly and 2 cm splenomegaly were present. There were a few coarse crepitations in the right lung mid-zone. Cardiovascular and neurological examination was unremarkable.

Investigations showed haemoglobin 14.1 g/dl, white cells  $6.4 \times 10^9/l$  (10% lymphocytes, 90% neutrophils), platelets  $202 \times 10^9/l$ . Urea, creatinine and electrolytes, chest radiograph and electrocardiogram were normal. Blood, urine and sputum cultures were negative. Three days after admission aspartate aminotransferase was raised at 48 U/l (normal less than 37), though bilirubin, alkaline phosphatase and gamma glutamyl transferase were normal. Viral titres and cultures, hepatitis B surface antigen, hepatitis B specific immunoglobulin and autoantibodies including antinuclear factor and smooth muscle antibody, were negative.

The patient improved without specific therapy, becoming lucid and afebrile over 3 days. At this stage it was noted that the spleen was barely palpable and by the next day could not be felt. The liver remained palpable. An ultrasound scan at this time showed normal appearances of liver and spleen.

A blood count 4 days after admission showed a marked change with a white cell count of  $2.6 \times 10^9/l$  (neutrophils 52%, lymphocytes 42%, monocytes 4%, eosinophils 2%), haemoglobin 11.7 g/dl and platelets  $67 \times 10^9/l$ . Aspartate aminotransferase had risen to 72 U/l.

Histological examination of a percutaneous needle biopsy of the liver showed changes of mitotic activity and thickening of liver cell plates. Necrosis and steatosis were not observed. There was no evidence of any chronic liver disease. The appearances were consistent with the sequelae of exposure to a toxic organic solvent.<sup>1</sup>

On discharge 5 days after admission the patient was well, his liver remained palpable and spleen impalpable. At follow up one month later he was fit and well, with normal liver function tests, biochemical profile and haematological indices.

### Discussion

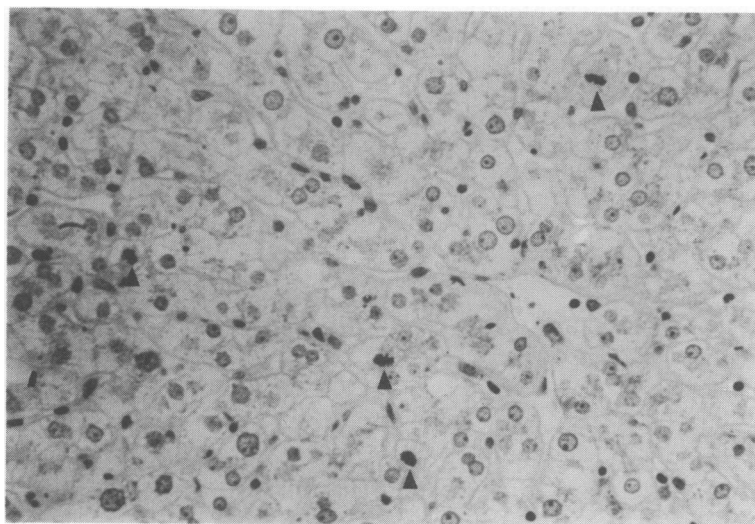
This man had an acute illness with reversible encephalopathy, bone marrow suppression and biochemical and histological evidence of a hepatocellular insult. The temporal association of heavy exposure to paint fumes and the lack of other toxins raises the possibility that some component of the paint was responsible. The patient and his wife consistently and separately denied recent alcohol or drug consumption and both appeared to be reliable witnesses. Although the fall may have contributed to his lack of short term memory on admission, it should be noted that symptoms preceeded the fall by 24 hours.

The volatile solvents present in the paint used are white spirit (35.7%), xylene (0.9%) and butyl alcohol (0.1%). White spirit (Stoddart solvent) contains aliphatic hydrocarbons and benzene derivatives. White spirit and kerosene are closely related petroleum distillates, and neither has a defined chemical composition. Nausea and drowsiness are reported to follow exposure to such aliphatic hydrocarbons in kerosene and pneumonitis and mucous membrane irritation are recognized to follow ingestion.<sup>2,3</sup> In one series of poisoned children 3 out of 36 were noted to have hepatosplenomegaly, the splenomegaly resolving rapidly.<sup>4</sup> A reaction such as we have observed following inhalation of fumes has not been reported previously, although it is common experience that transient nausea may follow such exposure.

We conclude that a reaction to inhaled paint fumes caused reversible hepatic, bone marrow and nervous system toxicity in this case. The manufacturer's recommendation that painting must be carried out with good ventilation should be observed.

### Acknowledgements

We thank Dr T.D. Browne of ICI Paints division for technical information.



**Figure 1** Mitotic activity in the hepatic parenchyma (arrows). Diastase PAS magnification  $\times 150$ .

## References

1. Read, A.E. The liver and drugs. In: Wright, R., Millward-Sadler, G.H., Alberti, K.G.M.M. & Karran, S. (eds) *The Liver and Biliary Disease*, 2nd edition. Bailliere Tindall, W.B. Saunders Co., London, 1985, p. 1022.
2. Dreisbach, R.H. & Robertson, W.O. *Handbook of Poisoning*, 12th edition, Appleton & Large, Norwalk, Connecticut, 1987, pp. 189–192.
3. Baldackin, J. & Melmod, R.N. Clinical and therapeutic aspects of kerosene poisoning. *Br Med J* 1964, 2: 28–30.
4. Steiner, M.M. Syndromes of kerosene poisoning in children. *Am J Dis Child* 1947, 74: 32–44.

This paper was referred with the agreement of Dr Taylor and his colleagues to the Safety Health and Environment Section of ICI Paints. The following communication was received:

The paper from Drs Atkinson, Ince and Taylor does not report atmospheric concentrations for the volatile components of the paint. We have simulated the conditions by painting large surfaces in a small bathroom (11.6 m<sup>3</sup>) with Dulux Polyurethane Gloss both with no ventilation and with the door and window open. With no ventilation the peak background (centre of room) level of organic vapour at one hour was 790 ppm, with an average personal exposure over the hour of 349 ppm. With the window and door open the one hour background peak was 110 ppm, and average personal exposure 28.5 ppm

The normal solvent composition of the paint is white spirit 35%, xylene 0.9%, and butyl alcohol 0.1%. The benzene content of the white spirit is below 0.1%. From this solvent composition, it may be assumed that the solvent exposure was essentially to white spirit. The occupational exposure limit for white spirit is 100 ppm time weighted average, with a short term exposure limit of 125 ppm. Thus from the above results in circumstances of no ventilation the exposure limit can be exceeded by a factor of 3 to 4, on a time weighted average basis, and a factor of 6 on a peak exposure basis.

Whether such exposure was causative in the effects described is open to debate. With regard to the nervous system effects of white spirit the most relevant papers on human exposure are those by Astrand<sup>1</sup> and Gamberale.<sup>2</sup> In 24 to 35 year old males the effects from exposure to 700 ppm during light exercise corresponded to 1100 ppm when sedentary. Effects on behavioural parameters, such as prolonged reaction time and impaired short term memory were noted after 1100 ppm for 30–40 minutes. No unequivocal symptoms, such as headache, dizziness, and nausea were noted at 1100 ppm whilst sedentary, but were noted at 700 ppm during exercise. These symptoms cleared within a few hours.

Comparing these findings to those reported, the man was approximately twice as old as the volunteers and would have been taking light exercise whilst painting. From the measurements we have made he could have absorbed sufficient solvent to cause subjective symptoms and acute memory effects. However these symptoms should have resolved within a few hours, whereas they were still present after 19 hours sleep, a further 6 hours sleep before falling, and a further 5 hours before admission to hospital, giving 30 hours in total. This prolonged period would seem to indicate a much greater exposure, or other factors. Such

other factors could include co-exposure to other solvents or drugs, exposure other than inhalation, the fall with the consequent concussion, and the reported alcohol consumption at 30 units a week.

The haematological values described on admission are within the normal range, albeit with slightly low and high lymphocyte, and neutrophil counts respectively. The changes which occurred after 4 days are qualitatively and time-wise consistent with those expected after benzene exposure, namely a reduction in platelets, haemoglobin and neutrophils. However the benzene content of the volatile components is specified to be less than 0.1%, and in practice is considerably below this.

The hepatomegaly reported on admission occurred far more quickly than would have been expected after acute exposure to organic solvents. The presence of hepatic mitotic activity is usually the sequel to overt damage, such as necrosis, and would normally be expected to take longer to develop than the reported 4 days. Liver induction due to solvent exposure would not be expected to result in hyperplasia. The aspartate aminotransferase activity increase is not particularly biologically significant, and may not be specifically associated with the liver. Overall we believe the clinical biochemistry indicates a minimal liver effect.

In general the symptomatology reported is consistent with exposure to solvent, and the experiments which we have carried out show that enough exposure could have been achieved, in circumstances of no ventilation, to cause transient symptoms. However, a variety of factors may have had an influence on the effects described. These include concussion from the fall, drug therapy and particularly alcohol intake being relatively high at the admitted 30 units per week. In addition the time scales are irregular, the nervous system effects being unexpectedly prolonged whilst the gross and microscopic liver effects appeared earlier than would be expected. We believe that it is unlikely that these effects could have been caused by inhalation of solvents from paint exposure alone, although such effects have been reported following ingestion.

Decorative paints are formulated to be safe in normal usage. They all contain volatile components, and as such should be used in circumstances of good ventilation. We therefore support the authors conclusion that the manufacturer's recommendation, that painting must be carried out with good ventilation, should be observed. In the domestic situation good ventilation means that doors and windows should be left open during application and drying of the paint.

We are grateful to the *Postgraduate Medical Journal* for the opportunity to comment on this paper.

Frank Rose  
*Medical Adviser, ICI Paints*  
Gerry J.A. Oliver  
*Head of Metabolism and Pharmacokinetics, Central Toxicology Laboratory, ICI PLC*  
John Ishmael  
*Head of Pathology, Central Toxicology Laboratory, ICI PLC*

#### References

1. Astrand, I., Kilbom, A. & Ourum, P. Exposure to white spirit. I. Concentration in alveolar air and blood during rest and exercise. *Scand J Work Environ Health* 1985, 1: 15–30.
2. Gamberale, F., Annwall, G. & Hultengren, M. Exposure to white spirit. II Psychological functions. *Scand J Work Environ Health* 1975, 1: 31–39.