

Microscopic polyarteritis: clinical features and treatment

H. Rodgers, J.A. Guthrie, A.M. Brownjohn and J.H. Turney

Regional Renal Unit, The General Infirmary at Leeds, Great George Street, Leeds LS1 3EX, UK.

Summary: The clinical features, treatment and survival of 36 patients with microscopic polyarteritis diagnosed between 1957–1988 have been reviewed. All had a focal segmental necrotizing glomerulonephritis on renal biopsy with evidence of a small vessel vasculitis. Most had a prodromal illness of less than 1 month. Severity of renal disease varied from microscopic haematuria which has a good prognosis to acute oliguric renal failure which carries a high mortality. The prognosis of microscopic polyarteritis can be improved if the condition is recognized early and treated with steroids and cyclophosphamide.

Introduction

Classical polyarteritis nodosa (PAN) is an inflammatory process involving large and medium sized arteries leading to aneurysm formation.¹ Microscopic polyarteritis differs from classical PAN clinically, pathologically and prognostically.^{2,3} Microscopic polyarteritis is defined as clinical evidence of a small vessel vasculitis associated with a focal segmental necrotizing glomerulonephritis in the absence of conditions associated with similar renal pathology (Table I).⁴ The classification of renal vasculitis remains unsatisfactory as the clinical and pathological features of these conditions are not distinct and overlap syndromes occur. Microscopic polyarteritis shares several features with Wegener's granulomatosis: both cause a focal segmental necrotizing glomerulonephritis and have positive neutrophil cytoplasmic antibodies (ANCA).^{5–7} Wegener's granulomatosis is characterized by a necrotizing granulomatous vasculitis of the upper and lower respiratory tract with or without renal involvement. The prognosis of both conditions is improved by immunosuppressive therapy.^{8–20}

Table I Causes of focal segmental necrotizing glomerulonephritis

Microscopic polyarteritis
Wegener's granulomatosis
Rapidly progressive (crescentic) glomerulonephritis
Systemic lupus erythematous
Henoch Schönlein purpura
Churg Strauss syndrome
Nephritis of bacterial endocarditis
Relapsing polychondritis

Correspondence: J.H. Turney, M.A., M.R.C.P.
Accepted: 13 March 1989

Several studies have reviewed the features of polyarteritis.^{10–21} Some include both classical PAN and microscopic polyarteritis, others used a broader definition of microscopic polyarteritis including other arteritides with renal involvement.^{2,3,10–28} Few have looked specifically at microscopic polyarteritis.^{4,15}

Patients and methods

The clinical records of 36 cases of microscopic polyarteritis diagnosed between 1957 and 1988 were reviewed. All had evidence of small vessel vasculitis and a focal segmental necrotizing glomerulonephritis on renal biopsy. Large vessel disease was not demonstrated by investigation or post-mortem examination. Patients with Wegener's granulomatosis, classical PAN and other vasculitides were excluded. In the study period only two cases of classical PAN were observed. For the purpose of analysis patients were divided into three groups on the basis of presenting renal function: Group A (4 patients) had microscopic haematuria with a stable creatinine of less than 200 $\mu\text{mol/l}$. Group B (8 patients) had deteriorating renal function but did not require dialysis. Group C (24 patients) presented with a rapid decline in renal function requiring dialysis.

The clinical features, treatment and results of laboratory investigations of these patients were examined.

Results

Clinical features

There were 21 female and 15 male cases of microscopic polyarteritis of age range 27–69 years (median 55

years). Most had a non-specific prodromal illness of malaise, myalgia and fever for less than 1 month although in some cases the prodrome was considerably longer (Table II). Renal disease ranged from microscopic haematuria to acute oliguric renal failure with the majority of cases being in the latter group. Myalgia or arthralgia were common but arthritis was not a feature (Table III). Skin manifestations included vasculitic rash, splinter haemorrhages and leg ulceration. Pulmonary haemorrhage occurred in 33% of cases, usually in association with acute renal failure and had a poor prognosis (75% mortality). Sixty one per cent of patients were hypertensive at presentation; 2 cases were found to have coronary vasculitis at post-mortem examination but clinical cardiac problems were not seen. Peripheral neuropathy was present in 4 cases and mononeuritis multiplex in one. Cerebral vasculitis presented as grand mal fits with deterioration in conscious level and a monoplegia, optic atrophy and sensineural deafness, subarachnoid haemorrhage, and pseudobulbar palsy. Otolaryngological abnormalities were secretory otitis media (1 case) and epistaxis (1 case); both patients had normal nasal biopsies. Conjunctivitis was observed in 2 cases.

Table II Duration of prodrome in 36 patients with microscopic polyarteritis

Duration	Number
< 1 week	7
1 week – 1 month	13
1–3 months	7
3–9 months	3
Not known	6
Total	36

Table III System involvement at presentation in 36 patients with microscopic polyarteritis

	Number	%
Renal	36	100
Hypertension (diastolic > 95 mmHg)	22	61
Musculoskeletal	21	58
Skin	16	44
Fever	14	39
Lung (haemorrhage)	12	33
Peripheral nervous system	5	14
Central nervous system	4	11
Otolaryngological	2	5
Ocular	2	5
Cardiac	2	5

Laboratory investigations

These are summarised in Table IV. Most patients had a normochromic, normocytic anaemia, a neutrophil leucocytosis and the ESR was markedly raised. From 1987 antineutrophil cytoplasmic antibody (ANCA) was measured and was positive in all new cases. Rheumatoid factor was positive in 38% of cases in whom it was measured. Hepatitis B serology and antinuclear factor were always negative. Serum complement and immunoglobulin levels showed no specific changes.

Table IV Laboratory investigations

Haemoglobin	Normal	9
	Low	27
White cell count	Normal	21
	Increased	15
	Eosinophilia	1
Platelet count	Normal	19
	Increased	7
	Decreased	3
ESR (mm/hour)	0–20	5
	21–60	6
	61–100	5
	101–120	5
Complement C3	Normal	6
	Increased	13
Rheumatoid factor	Positive	8
	Negative	13
ANCA	Positive	4
	Negative	0

Cause of death

There were 21 deaths (58%), the majority (19 deaths) in those patients requiring dialysis. None of the patients with microscopic haematuria and stable renal function died. Figure 1 shows the cause of death against time from presentation to the Renal Unit. The commonest cause of death in the early years of the study (9 deaths) was renal failure, but this has not been a cause of death for the last 8 years due to the increased availability of dialysis and the use of immunosuppressive therapy. There were 6 deaths from infection, 4 of which were pneumonia. All infective deaths occurred at least 6 weeks after presentation in immunosuppressed patients.

Treatment

Fourteen patients received steroids alone; 9 cyclophosphamide and steroids; 2 steroids and azathioprine; and 11 received no specific treatment (Table V).

Group A All 4 patients in this group did well. One patient received no treatment and showed no deterioration in renal function over several months.

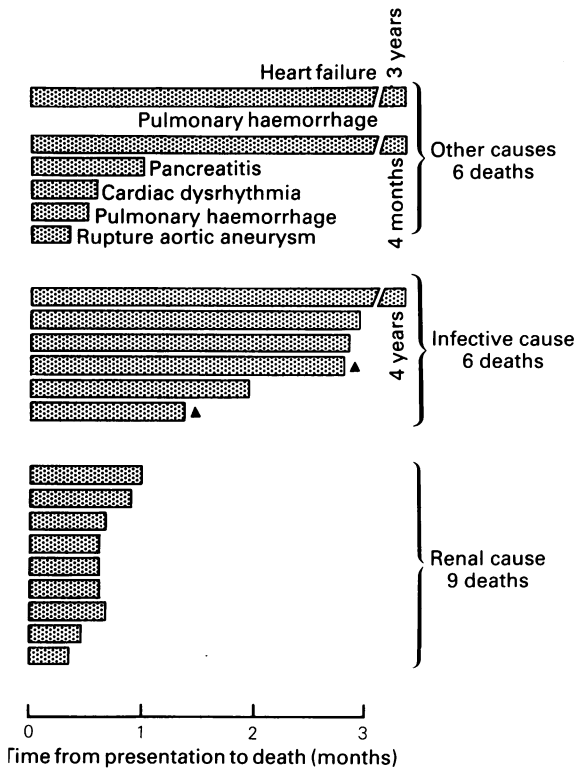


Figure 1 Microscopic polyarteritis: cause of death. (▲ Denotes patients in group B. All other deaths were in group C).

Group B All 8 patients received treatment. There were 2 deaths from infection.

Group C Nineteen of the 24 patients died. There were 2 late deaths on this group at 3 and 4 years. All patients who received no immunosuppression died. The mean survival of the untreated group was 15 days (3–35 days). Treatment improved outcome with 5 out of 14 patients surviving.

The patients requiring dialysis had a much higher mortality than those who did not. Five patients in this group survived, 2 required maintenance haemodialysis but the renal function of 2 cases improved such that they did not require further dialysis.

Discussion

Polyarteritis affecting the kidney is a rare disease but we have seen an increase in referrals in recent years. This may reflect a true increase in incidence as there has not been a comparable increase in other severe nephritides with acute renal failure. When the Renal Unit opened in 1956, patients were referred in established renal failure requiring dialysis. Patients are now seen earlier with a broader spectrum of renal disease ranging from microscopic haematuria with normal renal function to rapidly progressing glomerulonephritis. The variety of coexistent symptoms results in initial presentation to the spectrum of general medical specialities, particularly dermatology, rheumatology, and neurology.

Only cases of biopsy-proven microscopic polyarteritis are included in this study. The sex ratio of 1:1.4 is surprising as other series have reported a preponderance of males.^{4,10,13,15,18,24} The age distribution is similar to other series with a large proportion of cases being over 50 years.^{4,10–16,24,27} Most patients had a vague prodromal illness of less than a month which is less than 3.7 and 7.1 months reported by others.^{4,16}

All patients had evidence of renal involvement; the majority had oliguric renal failure. All had evidence of systemic disease: skin lesions, fever, myalgia, hypertension and lung involvement were common. The clinical features of these patients are similar to other studies of microscopic polyarteritis.^{4,15} The present study is unusual in the high incidence (61%) of hypertension. There were no specific haematological or immunological parameters apart from the ANCA, which has been positive in all recent cases.^{5–7}

Untreated oliguric acute renal failure due to microscopic polyarteritis has a mortality of 100%. The prognosis can be improved with treatment with steroids, with or without cyclophosphamide.^{4,10,13–15,19,24,27} The first reported survivor of acute renal failure due to PAN was in 1976.¹⁷

This study suggests that microscopic polyarteritis is

Table V Treatment

	Supportive	Steroids + immunosuppression	Total
Group A			
Number	1	2	3
Deaths	0	0	0
Group B			
Number	0	3	3
Deaths	0	1	1
Group C			
Number	10	9	19
Deaths	10	6	16
Total			
Number	11	14	25
Deaths	10	7	17

a wide spectrum of disease. At one end is a group with microscopic haematuria and normal renal function who have a good prognosis and at the other is a severe vasculitis causing a rapid deterioration in renal function requiring dialysis. The severe form of the disease is the commonest in this series and carries a high mortality. Early diagnosis and aggressive treatment with steroids and immunosuppression are essential if the prognosis is to be improved.

It is now our practice to treat new cases of micro-

scopic polyarteritis initially with prednisolone 60 mg daily and cyclophosphamide 3 mg/kg/day. Plasma-pheresis is currently being evaluated for severe cases.

Acknowledgement

We are grateful to Dr J.K. Anderson for interpreting the renal biopsies, to Dr F.M. Parsons for access to the records of patients under his care, and to Mrs J. Good for expert secretarial assistance.

References

1. Kussmaul, A. & Maier, R. Über eine bisher nicht beschriebene eigenthümliche. Arteriener Krankheit (periarteritis nodosa), die mit Morbus Brightii und rapid fortschreitender allgemeiner Muskellähmung einhergeht. *Deutsches Arch Klin Med* 1866, **1**: 484–517.
2. Wainwright, J. & Davson, J. The renal appearance in the microscopic form of periarteritis nodosa. *J Pathol* 1950, **62**: 189–196.
3. Davson, J., Ball, J. & Platt, R. The kidney in periarteritis nodosa. *Q J Med* 1948, **17**: 175–202.
4. Savage, C.O.S., Winearls, C.G., Evans, D.J., Rees, A.J. & Lockwood, C.M. Microscopic polyarteritis: presentation, pathology and prognosis. *Q J Med* 1985, **56**: 467–483.
5. van der Woude, F.J., Ramussen, N., Lobatto, S. *et al.* Autoantibodies against neutrophils and monocytes: tool for diagnosis and marker of disease activity in Wegener's granulomatosis. *Lancet* 1985, **i**: 425–429.
6. Savage, C.O.S., Winearls, C.G., Jones, S., Marshall, P.D. & Lockwood, C.M. Prospective study of radio-immunoassay for antibody against neutrophil cytoplasm in diagnosis of systemic vasculitis. *Lancet* 1987, **i**: 1389–1393.
7. Venning, M.C., Arfeen, S. & Bird, A.G. Antibodies to neutrophil cytoplasmic antigen in systemic vasculitis. *Lancet* 1987, **ii**: 850.
8. Fauci, A.S., Haynes, B.F., Katz, P. & Wolff, S.M. Wegener's granulomatosis: prospective clinical and therapeutic experience with 85 patients for 21 years. *Ann Intern Med* 1983, **98**: 76–85.
9. Pinching, A.J., Lockwood, C.M., Pussell, B.A. *et al.* Wegener's granulomatosis: observations of 18 patients with severe renal disease. *Q J Med* 1983, **52**: 435–460.
10. Serra, A., Cameron, J.S., Turner, D.R. *et al.* Vasculitis affecting the kidney: presentation, histopathology and long-term outcome. *Q J Med* 1984, **53**: 181–208.
11. Serra, A. & Cameron, J.S. Clinical and pathological aspects of renal vasculitis. *Semin Nephrol* 1985, **5**: 15–33.
12. Croker, B.P., Lees, T. & Gunnells, J.C. Clinical and pathological features of polyarteritis nodosa and its renal variant. *Hum Pathol* 1987, **18**: 38–42.
13. Adu, D., Howie, A.J., Scott, D.G., Bacon, P.A., McGonigle, R.J.S. & Michael, J. Polyarteritis and the kidney. *Q J Med* 1987, **62**: 221–237.
14. Fauci, A.S., Katz, P., Haynes, B.F. *et al.* Cyclophosphamide therapy of severe systemic necrotizing vasculitis. *N Engl J Med* 1979, **301**: 235–238.
15. Coward, R.A., Hamdy, N.A.T., Shortland, J.S. & Brown, C.B. Renal micropolyarteritis: a treatable condition. *Nephrol Dial Transplant* 1986, **1**: 31–37.
16. Fuiano, G., Cameron, J.S., Raftery, M., Hartley, B.H., Williams, D.G. & Ogg, C.S. Improved prognosis of renal microscopic polyarteritis in recent years. *Nephrol Dial Transplant* 1988, **3**: 383–391.
17. Tuma, S., Chaimovitz, C., Szyman, P., Gellei, B. & Better, O.S. Periarteritis in the kidney. Recovery following immunosuppressive therapy. *JAMA* 1976, **235**: 280–281.
18. Leung, A.C.T., McLay, A., Mosley, H. & Boulton-Jones, J.M. Polyarteritis group of systemic vasculitis - new diagnostic criteria. *Scot Med J* 1985, **30**: 225–231.
19. Lieb, E.S., Restiva, C. & Paulus, H.C. Immunosuppressive and corticosteroid therapy of polyarteritis nodosa. *Am J Med* 1979, **67**: 941–947.
20. Scott, D.G., Bacon, P.A., Elliott, P.J., Tribe, C.R. & Wallington, T.B. Systemic vasculitis in a District General Hospital 1972–1980: clinical and laboratory features; classification and prognosis of 80 cases. *Q J Med* 1982, **51**: 292–311.
21. Ronco, P., Verroust, P., Mignon, F. *et al.* Immunopathological studies of polyarteritis nodosa and Wegener's granulomatosis: a report of 43 patients with 51 renal biopsies. *Q J Med* 1983, **51**: 212–223.
22. Harrison, C.V., Loughridge, L.W. & Milne, M.D. Acute oliguric renal failure in acute glomerulonephritis and polyarteritis nodosa. *Q J Med* 1964, **33**: 39–54.
23. Ladefoged, J., Nielsen, B., Raaschou, F. & Sorensen, A.W.S. Acute renal failure due to polyarteritis nodosa. *Am J Med* 1969, **46**: 827–831.
24. Cohen, R.D., Conn, D.L. & Ilstrup, D.M. Clinical features, progress and response to treatment in polyarteritis. *Mayo Clin Proc* 1980, **55**: 146–155.
25. Rose, G.A. & Spencer, H. Polyarteritis nodosa. *Q J Med* 1957, **26**: 43–79.
26. Zeek, P.M. Periarteritis nodosa: a critical review. *Am J Clin Pathol* 1952, **22**: 777–789.
27. Frohnert, P.P. & Sheldon, G.S. Long-term follow up study of periarteritis nodosa. *Am J Med* 1967, **43**: 8–14.
28. Fauci, A.S. Vasculitis. *J Clin Immunol* 1983, **72**: 211–223.

Postgrad Med J: first published as 10.1136/pgmj.65.766.515 on 1 August 1989. Downloaded from <http://pmj.bmj.com/> on October 27, 2021 by guest. Protected by copyright.