

# Idiopathic spontaneous haemoperitoneum

Paul L. Sanderson, Michaela F.P. Davies and John M.T. Howat

Department of Surgery, North Manchester General Hospital, Delaunays Road, Manchester M8 6RB, UK.

**Summary:** A case is described of bleeding arising from the falciform ligament which occurred in the absence of obvious local pathology. Spontaneous bleeding from this site hitherto has not been reported. Previously described cases of idiopathic spontaneous haemoperitoneum and factors implicated in the aetiology of this rare condition are reviewed.

## Introduction

Massive haemoperitoneum presents as an acute surgical emergency. It is usually associated with trauma, ruptured aortic aneurysm, ectopic pregnancy, or bleeding from an ovarian follicle or hepatic tumour and, much less commonly, with rupture of an aneurysm of a visceral artery. Spontaneous haemoperitoneum in the absence of overt pathology is excessively rare.

## Case report

A previously fit 69 year old woman was admitted with a 5-day history of pain of sudden onset in the epigastrium and right hypochondrium and radiating to her back. Apart from a little vomiting there were no other symptoms. There was no history of trauma. She looked fit and was afebrile. Her pulse was 88 per minute and her blood pressure 210/110 mmHg. She was tender in the right hypochondrium but there was no rigidity. Her haemoglobin was 12.2 g/dl, and the white cell count  $18.6 \times 10^9/l$ . There were no biochemical abnormalities, other than a trace of protein in her urine. Plain films of the chest and abdomen were normal. A diagnosis of acute cholecystitis was made and she was treated conservatively.

Ten hours after admission the intensity of her pain suddenly increased, her blood pressure fell to 100/60 mmHg and there was a concomitant tachycardia of 140 per minute. She was sweating and distressed and guarding and rebound tenderness were elicited in the right hypochondrium. The haemoglobin had fallen to 9.0 g/dl. Abdominal ultrasound showed a solitary gallstone

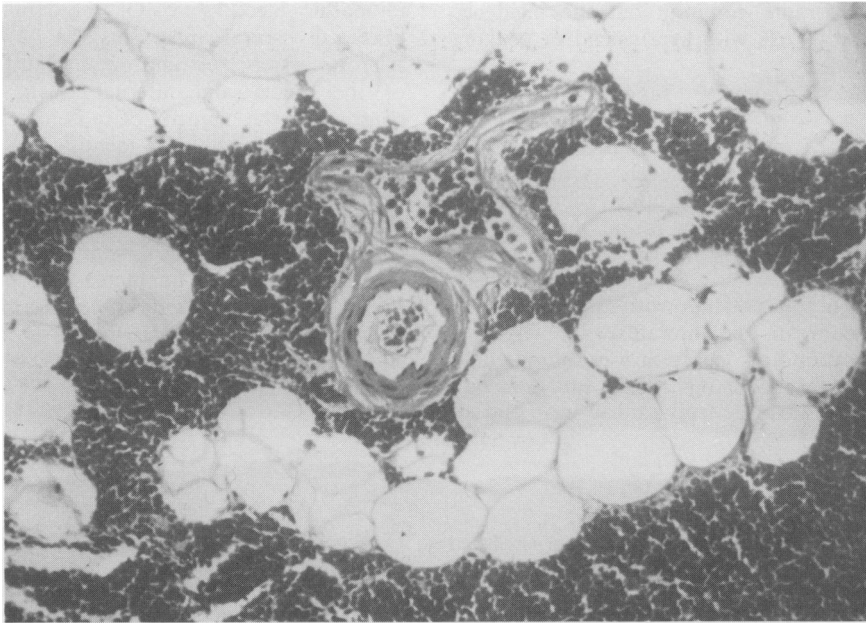
and free intra-peritoneal fluid. After resuscitation a laparotomy was carried out. A considerable amount of clotted blood was present within the peritoneal cavity and a large haematoma was found between the leaves of the falciform ligament which was detached from the back of the umbilicus. Careful search failed to reveal any other intra-abdominal abnormality. The falciform ligament was excised, and the abdomen closed. Clotting studies in the immediate postoperative period were normal. Her recovery was uneventful and she was discharged 10 days later. Histology of the falciform ligament showed only mature adipose tissue distorted by massive haemorrhage (Figure 1). The vessels within it were normal.

## Discussion

Spontaneous haemoperitoneum, or abdominal apoplexy, was first described in pregnancy by Barber in 1909.<sup>1</sup> Since then several authors have reviewed the condition.<sup>2-6</sup> These series have included patients of all ages but it is clear that the aetiology of spontaneous haemoperitoneum differs in young and elderly patients.<sup>6,7</sup> In the young it is common to find rupture of a visceral artery which is due either to an aneurysm resulting from a developmental defect of the artery analogous to congenital aneurysms in the brain; indeed the two have been reported to be associated,<sup>8</sup> or the necrosis of the media of the arterioles in polyarteritis nodosa.<sup>5,9</sup> The latter may also cause a haemoperitoneum in older patients.<sup>10</sup> In pregnancy haemoperitoneum usually results from rupture of the splenic artery,<sup>11</sup> a sequel to the structural changes occurring in connective tissue during gestation.<sup>12</sup>

Correspondence: J.M.T. Howat, M.D., F.R.C.S.

Accepted: 2 November 1987



**Figure 1** Section of falciform ligament showing haemorrhage and normal vessels (H & E  $\times 200$ ).

Over the age of 45 years spontaneous haemoperitoneum usually occurs as in the present case, in the absence of manifest pathology and is an extremely uncommon phenomenon, there being only 51 similar cases published since 1911.\* The initial symptom in most was ill-defined abdominal pain (46/51), but cases have occurred in which dyspnoea, chest pain, collapse and vomiting were the presenting complaints. Hypovolaemia and shock inevitably follow but this may be delayed for several days during which the bleeding is contained between the leaves of the mesentery, or as in the present case within the falciform ligament, before rupture into the peritoneal cavity.<sup>13-15</sup> Idiopathic spontaneous haemoperitoneum is most common between 55 and 64 years with a male to female ratio of 3:2. Of the 51 patients, 41 underwent surgery of whom only 28 (68%) survived. All 10 patients managed conservatively died. Patients were more likely to survive if a definite bleeding point was identified at operation (63%) than if one was not (35%), and although idiopathic intraperitoneal bleeding may arise from any intra-abdominal or retroperitoneal vessel, most commonly it is the branches of the coeliac axis or superior mesenteric which have been implicated. A bleeding point was

not found in 38% of the cases, either at operation or subsequently at post-mortem. No case has been previously described in which rupture of a vessel within the falciform ligament resulted in a haemoperitoneum.

The cause of haemorrhage in these patients is not entirely clear; however, it would seem that at least 70% of those whose blood pressure was recorded (29/41) were, like our patient, hypertensive. This figure may be an underestimate for some patients were in a state of shock at the time of first presentation.<sup>16-19</sup>

Hypertension may cause degeneration and fibrosis of the walls of the vessels of the gastrointestinal tract,<sup>20</sup> and this, in theory, may result in rupture. It has been suggested that atherosclerosis may be the lesion which predisposes to the spontaneous rupture of a visceral vessel.<sup>7,21,22</sup> However, the evidence for this is lacking and atherosclerosis, although often present in the aorta of these patients, has only occasionally been demonstrated in their visceral vessels. Furthermore, although in elderly patients with a cerebral haemorrhage, hypertension and atherosclerosis of the cerebral vessels are common findings, the small visceral arteries are rarely affected by atherosclerosis.<sup>23</sup> If atheroma was a significant factor in the pathogenesis of idiopathic spontaneous haemoperitoneum, the condition might be expected

\*A full list of references can be obtained from the authors.

to be not only more common but the incidence would continue to rise with age instead of peaking in the 6th decade.

Dvorak & Gazzaniga<sup>18</sup> suggested that the dissection of a visceral aneurysm might be a more common cause of intraperitoneal bleeding than is generally appreciated. However, Guthrie & McLean in a review of dissecting aneurysms of arteries other than the aorta, found that only 28 had been recorded to arise in the splanchnic vessels since 1829.<sup>24</sup>

There are only 8 patients with a spontaneous haemoperitoneum in the literature in whom a bleeding point found at operation was submitted to histological examination. Of these, only 3 had normal vessels and can be truly said to have had an

idiopathic bleed.<sup>4,25,26</sup> Of the remainder, 2 had dissected visceral aneurysms,<sup>18,27</sup> 2 had ruptured sclerotic vessels,<sup>19,28</sup> and one had diffuse deficiency of the media and internal elastic lamina.<sup>6</sup> By contrast, in the majority of those cases in which the vessel involved was only identified at post-mortem, the histological findings were normal.

The roles, therefore, of hypertension and abnormalities of the vessel wall in the aetiology of spontaneous haemoperitoneum remain obscure. It seems unlikely that an increase in blood pressure *per se* is sufficient to rupture a normal artery and presumably in some cases the vessel involved is the site of local pathology which so far remains unrecognized.

### References

1. Barber, M.C. Intra-abdominal haemorrhage associated with labour. *Br Med J* 1909, **ii**: 203.
2. Cushman, G.F. & Kilgore, A.R. The syndrome of mesenteric and subperitoneal haemorrhage (abdominal apoplexy). *Ann Surg* 1941, **114**: 672-681.
3. Brewer, A.C. & Marcus, R. Massive spontaneous intraperitoneal haemorrhage. *Br J Surg* 1947, **36**: 198-200.
4. Browne, M. & Glashan, R.W. Abdominal apoplexy. *Br J Surg* 1965, **52**: 362-367.
5. Carter, R. & Gosney, W.G. Abdominal apoplexy. *Am J Surg* 1966, **111**: 388-397.
6. Kleinsasser, L.J. Abdominal apoplexy. *Am J Surg* 1970, **120**: 623-628.
7. Shallow, T.A. Herbot, P.A. & Wagner, F.B. Abdominal apoplexy secondary to ruptured 'congenital' aneurysm. *Surgery* 1946, **19**: 177-185.
8. Nevin, S. & Williams, D. The pathogenesis of multiple aneurysms. *Lancet* 1937, **ii**: 955-958.
9. Woods, A.C., Parry, R.G. & Detmer, D.E. Successful surgical treatment of massive abdominal haemorrhage due to polyarteritis nodosa. *Arch Surg* 1968, **97**: 541-543.
10. Pugh, J.I. & Stringer, P. Abdominal polyarteritis nodosa. *Br J Surg* 1956, **44**: 302-307.
11. Pollak, E.W. & Michas, C.A. Massive spontaneous haemoperitoneum due to rupture of visceral branches of the abdominal aorta. *Am Surg* 1979, **10**: 621-630.
12. Mariello-Estralla, P. & Borke, A.E. Histopathological findings in human aortic media associated with pregnancy. *Arch Pathol* 1967, **83**: 336-342.
13. Churchman, J.W. Spontaneous intraperitoneal haemorrhage. *Am J Med Sci* 1911, **142**: 825-826.
14. Thompson, K.W. & Dunphy, J.E. Intra-abdominal apoplexy. *Ann Surg* 1935, **102**: 1116-1118.
15. Berk, J.E., Rothschild, N.S. & Doane, J.C. Intra-abdominal apoplexy. *Ann Surg* 1941, **113**: 513-520.
16. Woolf, A.L. & Thompson, H.R. Spontaneous intra-abdominal haemorrhage. *Br Med J* 1949, **i**: 572-575.
17. Hahn, G.A. Rupture of the mid-colic artery (abdominal apoplexy) producing signs of pelvic haemorrhage. *Am J Obst Gynec* 1958, **66**: 185-187.
18. Dvorak, A. & Gazzaniga, A. Dissecting aneurysms of the gastroduodenal artery. Anatomic basis for the clinical syndrome of abdominal apoplexy. *Ann Surg* 1969, **169**: 425-428.
19. Fleisser, W., Stefanini, J. & Kosyak, E.P. Spontaneous rupture of the splenic artery at the level of an atheromatous plaque. *Vasc Surg* 1971, **5**: 183-185.
20. Smith, J.P. Hyaline arteriosclerosis in spleen, pancreas and other viscera. *J Pathol Bact* 1956, **72**: 643-655.
21. Silverstone, M. Massive spontaneous intra-peritoneal haemorrhage. *Br Med J* 1938, **i**: 230-231.
22. Tanna, J.F. Abdominal apoplexy. *Am J Surg* 1947, **73**: 132-136.
23. Debakey, M.E., Lawrie, G.M. & Glasser, D.M. Patterns of atherosclerosis and their surgical significance. *Ann Surg* 1985, **201**: 115-131.
24. Guthrie, W. & McLean, H. Dissecting aneurysms of arteries other than the aorta. *J Pathol* 1972, **108**: 219-234.
25. Burkitt, R. Abdominal apoplexy due to spontaneous rupture of right gastric artery. *Br Med J* 1956, **i**: 214.
26. Martorell, R. Spontaneous rupture of the superior mesenteric artery. *Ann Surg* 1963, **157**: 292-297.
27. Michas, C., Pollak, E.W. & Wolfman, E.F. Haemoperitoneum due to spontaneous gastroepiploic artery rupture. *JAMA* 1977, **237**: 2526.
28. Buckbinder, J.R. & Greene, E.I. Intra-abdominal apoplexy. *JAMA* 1936, **105**: 874-875.