

Familial dysalbuminaemic hyperthyroxinaemia

S.J. Fleming, G.F. Applegate and C.G. Beardwell

Withington Hospital, Manchester, M20 8LR, UK.

Summary: Familial dysalbuminaemic hyperthyroxinaemia (FDH) can be confused with thyrotoxicosis if clinical signs and laboratory tests are misinterpreted. We describe three members of the same family with FDH who were erroneously treated for thyrotoxicosis. Screening of other family members resulted in the discovery of a further six patients at risk of being misdiagnosed as thyrotoxic. Clinical and biochemical findings relevant to the diagnosis of FDH are discussed.

Introduction

Familial dysalbuminaemic hyperthyroxinaemia (FDH) is a recently described condition in which albumin molecules have a greatly increased affinity for thyroxine (T_4) resulting in elevated levels of total T_4 but normal levels of the free, active hormone.¹ Affected individuals are euthyroid but at risk of being diagnosed as thyrotoxic. We describe three members of the same family with FDH who were erroneously treated for thyrotoxicosis. Thyroid function tests were carried out on other family members and a further six patients at risk of being misdiagnosed as thyrotoxic identified.

Case studies

Patient 1

A 12 year old girl presented to another hospital in August 1985 with several weeks of constipation associated with intermittent abdominal pain and vomiting. There was no history suggestive of thyrotoxicosis and clinically she was euthyroid. In view of the family history of thyrotoxicosis (*vide infra*) thyroid function tests were carried out. Serum T_4 was 244 nmol/l (normal 50–150), triiodothyronine (T_3) 2.2 nmol/l (normal 1.0–3.6), thyroid stimulating hormone (TSH) 1.7 mU/l (normal <8), free T_4 (measured by an analogue assay) 83 pmol/l (normal 10–28), and thyroxine binding globulin (TBG) 21 mg/l (normal 15–35). Autoantibody screen was negative. She was commenced on carbimazole 25 mg/day. After 5 weeks of treatment her neutrophil count was

$1.35 \times 10^9/l$. Carbimazole was discontinued and 3 weeks later when the neutrophil count was still depressed a bone marrow examination which proved to be normal was carried out. Her differential white count returned to normal. She was referred to this hospital for advice on further treatment of her thyrotoxicosis as other antithyroid drugs were felt to be contraindicated and her parents were reluctant to consider surgery. When seen in January 1986 she appeared euthyroid and after review of the initial thyroid function test results a clinical diagnosis of FDH was made and subsequently confirmed on biochemical testing.

Patient 2

A 49 year old man, the uncle of Patient 1, was seen in another hospital in April 1984 with a long history of anxiety and palpitations induced by stress or exertion. There were no other symptoms suggestive of thyroid disease. On examination he was euthyroid and a goitre was not palpable. A diagnosis of anxiety attacks was made and he was commenced on propranolol. Results of thyroid function tests were: T_4 248 nmol/l (normal 50–150), T_3 1.9 nmol/l (normal 1.1–2.8) and T_4 to TBG ratio 13 (normal 3–9). He was treated with carbimazole and propranolol for 6 months with some symptomatic relief. A month after discontinuing the carbimazole, serum T_4 was again elevated and in May 1985 he was treated with radioactive iodine (225 MBq). Three months later he was clinically euthyroid and serum values of both T_4 and TSH were elevated at 206 nmol/l and 7.9 mU/l (normal 0.5–6.5) respectively. He was followed in outpatients but received no further treatment. The diagnosis of FDH was made in him after it had been confirmed in his niece (Patient 1).

Correspondence: S.J. Fleming, M.A., M.R.C.P., Teaching Unit Six, Withington Hospital, Manchester M20 8LR, UK. Accepted: 6 October 1986

Patient 3

The 41 year old mother of Patient 1 and sister of Patient 2 was referred for specialist opinion at another hospital because of some years of feeling generally unwell with headache, malaise, anorexia and latterly some weight loss. On examination she was euthyroid and a goitre was not palpable. As part of a routine screening battery thyroid function tests were carried out and these showed: T₃ uptake 108 (normal 92–117), T₄ 210 nmol/l (normal 60–156) and free thyroxine index (FTI) 194 (normal 65–130). In October 1984 she was commenced on carbimazole 30 mg/day with little relief of her symptoms. By January 1985 T₃ uptake was 120, T₄ 65 nmol/l, FTI 54 and TSH 35 mU/l (normal 0–6). Carbimazole was discontinued. When she complained of feeling exhausted a month later carbimazole treatment was recommenced. The drug was again withdrawn 6 months later when serum T₄ was < 34 nmol/l and TSH > 51 mU/l. Her presenting symptoms persisted and the diagnosis of FDH was finally made only after it had been arrived at in her daughter (Patient 1).

Results of screening three generations of the family are presented in Figure 1. Transmission was by the mother of Patients 2 and 3 and four of her eight children were affected. Of 11 children in the third generation born to affected parents, four were shown to have FDH, five were normal and two were not tested. The pattern of inheritance is consistent with autosomal dominant transmission as has been previously described.^{2,3} Another of the affected family members had already been referred to medical outpatients as possibly thyrotoxic because of the strong family history of this

disease. Fortunately the initial laboratory tests were correctly interpreted as showing FDH.

Discussion

Serum total thyroxine may be elevated either in thyrotoxicosis or when the concentration of T₄-binding proteins is increased. An elevated TBG, the principal protein binding both T₃ and T₄ is routinely tested for in many clinical laboratories either directly or by thyroid hormone uptake tests. In FDH albumin has increased affinity for T₄ and sometimes T₃.¹ Under these circumstances total T₄ is elevated and TBG normal so that the T₄/TBG ratio will also be raised and the incorrect diagnosis of thyrotoxicosis may be made. When T₃ uptake tests are used patients with albumin that binds only T₄ will give normal results so that the FTI will also be misleadingly raised. To date three distinct albumin variants with enhanced affinity for T₄ have been described.⁴

Patients with FDH will not be mistakenly diagnosed as having thyrotoxicosis if proper attention is paid to both clinical examination and the results of routine laboratory tests of thyroid function.

Clinically these patients are euthyroid and the response to treatment with T₄, T₃, potassium iodide, or subtotal thyroidectomy supports the concept that the elevated levels of T₄ are an appropriate response to increased binding of this hormone.⁵ None of the patients described above was clinically thyrotoxic.

While T₄ and FTI are elevated in FDH, serum free thyroxine levels measured by equilibrium dialysis are normal¹ although the levels measured by most of the commonly used analogue assays are misleadingly high⁴ as was found in Patient 1. Serum total T₃ is

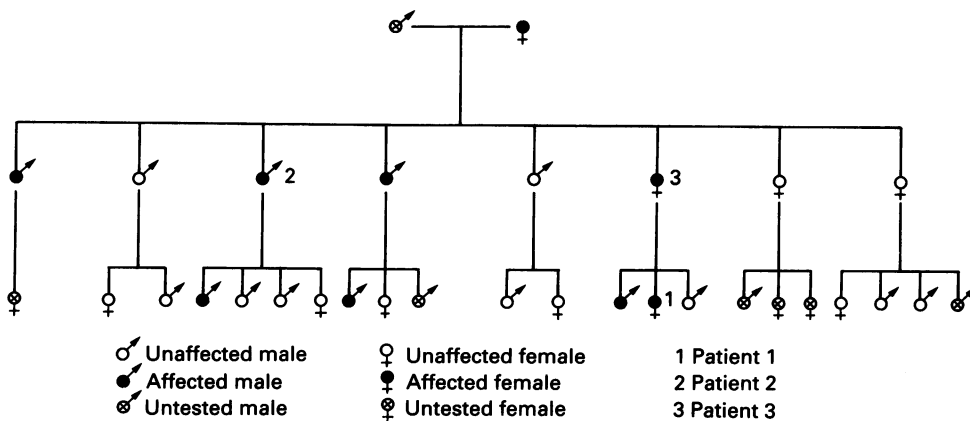


Figure 1 Family tree showing affected members.

usually in the normal range as is free T_3 ¹ but there is one albumin variant which binds increased amounts of both T_3 and T_4 resulting in elevated total levels of both these substances.

The diagnosis of FDH was suggested in Patients 1 and 2 by the normal T_3 levels which are surprising in thyrotoxicosis and usually only found in elderly patients with other serious systemic diseases⁶ or in other types of euthyroid hyperthyroxinaemia.⁷ In Patient 3 the T_3 uptake was towards the upper end of the normal range suggesting the presence of an abnormal binding protein. In laboratories using high sensitivity TSH assays, the finding of detectable TSH in a patient with a raised T_4 concentration makes the

diagnosis of thyrotoxicosis unlikely.

If the diagnosis of FDH is suspected a screening test can be used in which the increased binding of T_4 by the abnormal albumin is detected by adding excess T_4 to the patient's serum to saturate the TBG together with a trace amount of ¹²⁵I- T_4 . The fraction of T_4 not bound to the serum proteins is absorbed by dextran coated charcoal. Patients with FDH show increased binding of radioactive T_4 when compared to normals.³ Confirmation of a positive result, and the definitive diagnosis, can be made by the use of reverse flow electrophoresis.⁸ Use of these tests may prevent other patients receiving unnecessary and at times hazardous treatment for non-existent thyrotoxicosis.

References

1. Ruiz, M., Rajatanavin, R., Young, R.A. *et al.* Familial dysalbuminemic hyperthyroxinemia: a syndrome that can be confused with thyrotoxicosis. *N Engl J Med* 1982, **306**: 635–639.
2. Lee, W.N.P., Golden, M.P. van Herle, A.J., Lippe, B.M. & Kaplan, S.A. Inherited abnormal thyroid hormone-binding protein causing selective increase of total serum thyroxine. *J Clin Endocrinol Metab* 1979, **49**: 292–299.
3. Stewart, M.F., Ratcliffe, W.A. & Roberts, I. Thyroid function tests in patients with familial dysalbuminaemic hyperthyroxinaemia (FDH). *Ann Clin Biochem* 1986, **23**: 59–64.
4. Lalloz, M.R.A., Byfield, P.G.H. & Himsworth, R.L. A new and distinctive albumin variant with increased affinities for both triiodothyronines and causing hyperthyroxinaemia. *Clin Endocrinol* 1985, **22**: 521–529.
5. Stockigt, J.R., Topliss, D.J., Barlow, J.W., White, E.L., Hurley, D.M., Taft, P. Familial euthyroid thyroxine excess: an appropriate response to abnormal thyroxine binding associated with albumin. *J Clin Endocrinol Metab* 1981, **53**: 353–359.
6. Birkhauser, M., Thurer, Th., Bussett, R. & Burger, A. A Diagnosis of hyperthyroidism when serum thyroxine alone is raised. *Lancet* 1977, **ii**: 53–56.
7. Rajatanavin, R. & Braverman, L.E. Euthyroid hyperthyroxinaemia. *J Endocrinol Invest* 1983, **6**: 493–505.
8. Lalloz, M.R.A., Byfield, P.G.H., Himsworth, R.L. Hyperthyroxinaemia: abnormal binding of T_4 by an inherited albumin variant. *Clin Endocrinol* 1983, **18**: 11–24.