

aetiology should be considered, irrespective of race. Multiple pigmented longitudinal bands in the nails of coloured patients may not have the same significance.

Acknowledgments

We wish to thank our colleagues in Surgery and Pathology for their help, and also Dr I. W. Caldwell and Dr J. E. White, for allowing us to report their patients.

References

- ALLENBY, C.F., & SNELL, P.L. (1966) Longitudinal pigmentation of the nails in Addison's disease. *British Medical Journal*, **1**, 1582.
- BISHT, D.B. & SINGH, S.S. (1962) Pigmented bands on nails. A new sign of malnutrition. *Lancet*, **i**, 507.
- ENGMAN, M.F., MOOK, W.H. & ENGMAN, M.F., Jr (1931) *Melanotic whitlow*. *Archives of Dermatology and Syphilology*, **23**, 1174.
- HARVEY, K.M. (1960) Pigmented naevus of nail. *Lancet*, **ii**, 848.

- MONTGOMERY, D.W. (1917) A pigmented stripe in the thumb nail. *Journal of Cutaneous Disease*, **35**, 99.
- NOBEL, J.F., FERRIN, A. & MERANDINO, K.A., (1952) Pigmented naevus of the fingernail matrix. *Archives of Dermatology and Syphilology*, **65**, 49.
- OLIVER, E.A. & BLUEFARB, S.M. (1944) Naevus striatus symmetricus unguis, *Archives of Dermatology and Syphilology*, **49**, 190.
- OPPENHEIM, M. & COHEN, D. (1942) Naevus striatus symmetricus of the thumbs, *Archives of Dermatology and Syphilology*, **45**, 253.
- PACK, G.T. & ADAIR, F.E. (1939) Subungual melanoma. *Surgery*, **5**, 47.
- PILLSBURY, D.M., SHELLEY, W.B. & KLIGMAN, A.M. (1956) In: *Dermatology*. W. B. Saunders, Philadelphia, p. 1022.
- SAMMAN, P.D. (1965) *The Nails in Disease* (First Edition) p. 90, William Heinemann, London.
- SAMMAN, P.D. (1972) The Nails. In: *Textbook of Dermatology* (Ed. by A. J. Rook, D. S. Wilkinson & F. J. Ebling), 2nd Edn, **2**, 1657, Blackwell Scientific Publications, Oxford.
- STEWART, W.K. & RAFFLE, E.J., (1972) Brown nail-bed arcs and chronic renal disease, *British Medical Journal*. **1**, 784.
- WOMACK, N.A. (1927) Subungual melanoma. *Archives of Surgery*, **15**, 667.

Postgraduate Medical Journal (October 1977) **53**, 627-630.

Hereditary angio-oedema with mesangiocapillary glomerulonephritis

JUAN PLAZA
M.D.

PRIDA MALASIT
M.D., M.R.C.P.

DAVID N. S. KERR
M.Sc., F.R.C.P. (Edin.), F.R.C.P. (Lond.)

University of Newcastle-upon-Tyne, England

Summary

A patient with hereditary angio-oedema (HAO) developed mesangiocapillary glomerulonephritis (MCGN) under observation. HAO is characterized by an inherited defect of complement—deficiency of C1 esterase. MCGN is often associated with another complement abnormality which leads to depression of serum C3 and there is some evidence that the complement abnormality precedes the nephritis. The coincidence of these two rare diseases in the present patient, and in one previously described, suggests that other complement abnormalities may predispose to the development of MCGN.

Introduction

Hereditary angio-oedema (HAO) is a disease inherited as an autosomal dominant in which there is a deficiency of an inhibitor of the activated first component of complement (C1 esterase inhibitor). It is characterized by attacks of oedema of the skin and mucous membranes which may be life-threatening when the pharynx and larynx are involved (Donaldson and Evans, 1963; Hadjiyannaki and Lachmann, 1971; Beck *et al.*, 1973).

Mesangiocapillary glomerulonephritis (MCGN) is a form of chronic glomerulonephritis with mesangial hyperplasia and capillary wall thickening thought to arise from the deposition of immune complexes either under (subendothelial type) or within (dense deposit type) the basement

Correspondence: Professor D. N. S. Kerr, Department of Medicine, Royal Victoria Infirmary, Newcastle-upon-Tyne NE1 4LP.

membrane of the glomerular capillaries. The dense deposit type also affects tubular basement membranes. MCGN is usually associated with an ill-defined abnormality of the complement system which causes depression of serum C3 (West, Northway and Davies, 1964; Vargas *et al.*, 1976; Ooi, Vallota and West, 1976).

Both these diseases are rare. In the Northern Health Region of England (population 3 million) the authors are aware of only four families with HAO and have seen only twenty-four cases of MCGN during the 16 years that renal biopsy has been available (about 3000 renal biopsies). There is no known connection between these diseases apart from the existence of complement abnormalities in both. Their co-existence in a patient, an association that has been reported once before (Pickering *et al.*, 1971), is now described.

Case history

A retired miner of Caucasian descent, aged 62 years, was referred to the Dermatology Department in April 1969, because of a personal and family history of HAO. The family tree is shown in Fig. 1.

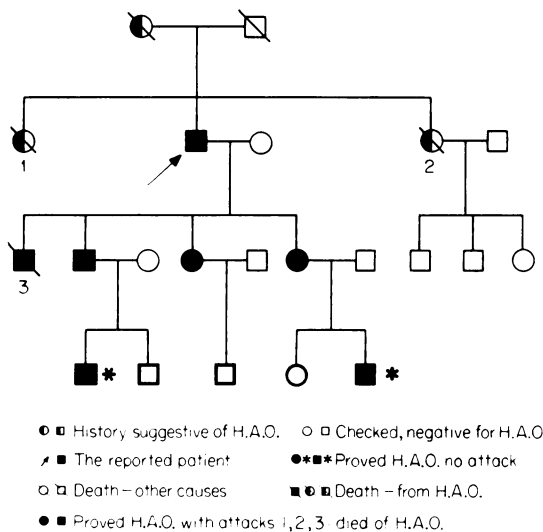


FIG. 1. Family tree of patient.

He has two sons, two daughters and a sister who also suffer from HAO. His two sisters (1, 2, on family tree) and his eldest son (3) died from laryngeal oedema during crises of angio-oedema; the latter has been reported (Holti, 1975). The present patient's attacks were manifested by swelling which could be localized or generalized; his face and extremities were most commonly affected. In his more severe attacks he had difficulty

in breathing because of pharyngeal or laryngeal oedema, which responded rapidly to infusion of fresh-frozen plasma. These attacks were usually, but not always, brought on by direct trauma, minor surgical operations, heavy exertion or infection. Although routine urinalysis was performed on several earlier occasions, haematuria was not discovered until he was 68 years old and even then he had no urinary symptoms.

His past medical history included recurrent bilateral otitis media since childhood, one attack of pneumonia at the age of 21 years and malaria during World War II but he had not otherwise been troubled with recurrent infections. He had had two operations (herniorrhaphy and haemorrhoidectomy) under cover of fresh frozen plasma without complications.

On admission at the age of 68 he was hypertensive (180/105 mmHg) but not oedematous. His urine contained 3.4 g protein/24 hr and numerous red blood cells, hyaline and granular casts. The proteinuria was non-selective. His plasma urea was 13.3 mmol/l, creatinine 93 μ mol/l, creatinine clearance 88 ml/min, total serum proteins 68 g/l, albumin 42 g/l. His IVU was normal. He has been followed-up for 4 years during which his proteinuria has fallen to less than 0.5 g/24 hr but the urinary sediment has remained abnormal and red cell casts have been seen in the deposit on several occasions. Excretory function has declined slightly but his hypertension has been easily controlled with methyldopa.

Renal histology

Renal biopsy was carried out soon after the discovery of haematuria (Fig. 2). The sections contained 54 glomeruli. Some showed only mesangial prominence but most were enlarged and lobular. Mesangial cells and matrix were increased, displacing the capillary loops to the periphery. Capillary walls were thickened and showed splitting of the basement membrane. There were no capsular crescents, tubular atrophy or interstitial fibrosis. Immunofluorescence study showed deposition of IgG and C3 in the glomeruli; IgM was not detected. Electron microscopy (Dr Mary McDonald) confirmed the diagnosis of mesangiocapillary glomerulonephritis of subendothelial type.

Complement study

Complement components C1q, C2, C3, C4, C5, C6, Factor B and C1 esterase inhibitor (C1-ihb) were measured by single radial immunodiffusion against specific antisera and C1-ihb was also measured functionally by a standard method while the patient was in remission. C1-ihb was absent functionally and greatly depressed antigenically; C2 and C3 were below normal (Table 1).

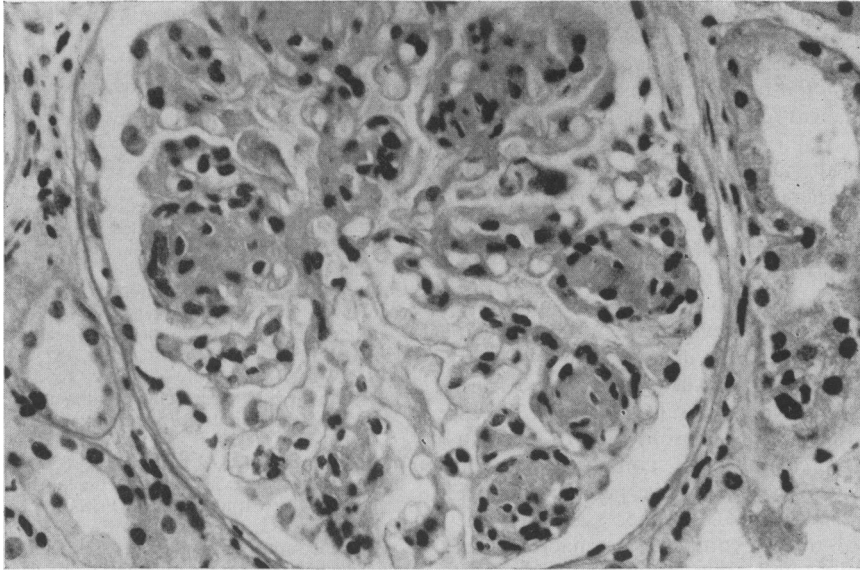


FIG. 2. Renal biopsy.

TABLE 1. Serum complement assay

	C1q	C2	C4	C3(B ₁ A)*	C5	C6	C1-inh antigenic	C1-inh functional	B
No. of assays	1	1	1	8	1	1	25	0	1
Results (%)	100	'low'	20	74.9	62	80			55
Normal range (%) (mean ± 2 (s.d.))	60-136		50-210	90.6 ± 5.6	60-110	33-187			40-120

* results expressed as mg/dl

Discussion

HAO is an inherited disease, so the complement abnormality was present in the patient from birth while his glomerulonephritis, the onset of which can be dated with reasonable accuracy, did not appear until his 69th year. It is interesting to speculate whether his primary complement abnormality predisposed him to MCGN. Some complement abnormalities (C1r-, C4- and C2-deficiency) are associated with immune complex disease (Moncada *et al.*, 1972; Aguello, De Bracco and Kunkel, 1972; Hauptmann, Grosshans and Heid, in press). There are reports of glomerulonephritis (presumably of immune complex type) with deficiencies of C1r, C2 and C1 esterase inhibitor (Pickering *et al.*, 1971).

Patients with MCGN typically have a low concentration of C3 which is sometimes associated with the presence of a factor which breaks down C3 (C3-nephritic factor; C3-NEF). There is a close association between this disease and lipodystrophy. Patients with lipodystrophy often have a low serum C3 which precedes the onset of nephritis and this led

Peters and his colleagues (Peters *et al.*, 1973) to suggest that the complement deficiency made these patients susceptible to the development of glomerulonephritis, possibly because they could not eliminate bacterial infection normally. Certainly the complement system is an indispensable part of the host's defences against infection, since it is necessary, with antibody, for the lysis and phagocytosis of bacteria and viruses. Patients with various genetic defects of the complement system are vulnerable to infection (Alper, Bloch and Rosen, 1973; Alper, Colten and Rosen, 1972). This has not been convincingly demonstrated for patients with lipodystrophy, MCGN or HAO, including the patient described here, but it may well be that overt susceptibility is not necessary for the development of nephritis. Possibly latent bacterial or viral infection, by providing a continuing antigenic stimulus, is more important.

On the other hand, the complement system is a mediator of renal damage in immune nephritis and complement deficiency might be expected to protect

the patient against nephritis when he has circulating immune complexes (Pickering *et al.*, 1971). There are at least three possible explanations for this paradox. Firstly, the deficiencies may not be complete and sufficient complement may remain to mediate renal injury. With some complement deficiencies the alternate pathway provides a second route for complement activation. Secondly, immune complexes on their own can damage the glomerulus without the intervention of complement. Complement depletion has no effect on the capacity of circulating complexes to deposit in blood vessel walls (Cochrane and Hawkins, 1968) and their deposition occurs during increases in vascular permeability produced by vasoactive amines and histamine release from mast cells by the action of complexes by themselves (Henson, 1969). Thirdly, a decrease in the clearance of complexes by the reticulo-endothelial system can be postulated since complement, especially C3, is necessary for the binding of IgM-antigen complexes to macrophages and neutrophils, and this may outweigh any protective effect of complement deficiency.

In summary, it is possible that some abnormalities of complement activation, mainly in the first steps of the classical pathway, predispose to immune complex disease. No reasonable explanation can be offered as to why an overreaction of part of this segment of the complement pathway, caused by lack of an inhibitor, should have the same effect as a deficiency but the odds against two such rare diseases co-existing by chance are long. It is therefore suggested that HAO predisposes to the development of MCGN in a manner that will only become apparent with better understanding of the complement system.

Acknowledgments

We are grateful to Professor Lachman and his staff for the complement values in Table 1, to Dr Michael Floyd now of the University of Dallas, for his interest in the patient when first diagnosed, and to Dr G. Holti for permission to use his data on this patient and the family.

References

AGUELLO, V., DE BRACCO, M.M., & KUNKEL, H.G. (1972) Hereditary C2 deficiency with some manifestations of

- systemic lupus erythematosus. *Journal of Immunology*, **108**, 837.
- ALPER, C.A., COLTEN, H.R., & ROSEN, F.S. (1972) Homozygous deficiency of C3 in a patient with repeated infections. *Lancet*, **ii**, 1179.
- ALPER, C.A., BLOCH, K.J. & ROSEN, F.S. (1973) Increased susceptibility to infection in a patient with type II essential hypercatabolism of C3. *New England Journal of Medicine*, **288**, 601.
- BECK, P., WILL, D., DAVIES, G.T., LACHMANN, P.J. & SUSSMAN, H. (1973). A familial study of hereditary angioneurotic oedema. *Quarterly Journal of Medicine*, New Series XLII **166**, 317.
- COCHRANE, C.G. & HAWKINS, D. (1968) Studies of circulating immunocomplexes III. Factors governing the ability of circulating complexes to localize in blood vessels. *Journal of Experimental Medicine*, **127**, 137.
- DONALDSON, V.H. & EVANS, R.R. (1963). A biochemical abnormality in hereditary angioneurotic oedema: absence of serum inhibitor of C1 esterase. *American Journal of Medicine*, **35**, 37.
- HADIYANNAKI, K., & LACHMANN, P.J. (1971) Hereditary angioedema: a review with particular reference to pathogenesis and treatment. *Clinical Allergy*, **1**, 2.
- HAUPTMANN, G., GROSSHANS, E. & HEID, E. (In press) Systemic lupus erythematosus and hereditary complement deficiencies. A case with total C₄ deficiency. *Annales de Dermatologie et de Syphiligraphie*
- HENSON, P.M. (1969) The adherence of leucocyte and platelets induced by fixed IgG antibody or complement. *Immunology*, **16**, 107.
- HOLT G. (1975) Some clinical aspects of hereditary angioedema (HAE). (Abstract.) *Biorheology*, **12**, 76.
- MONCADA, B., NOORBIBI, K.B., GOOD, R.A. & WHINDHORS, D.B. (1972) Lupus erythematosus-like syndrome with familial defect of complement. *New England Journal of Medicine*, **286**, 689.
- OOI, Y.M., VALLOTA, E.H., WEST, C.D. (1976) Classical complement pathway activation in membranoproliferative glomerulonephritis. *Kidney International*, **9**, 46.
- PETERS, D.K., WILLIAMS, D.G., CHARLESWORTH, J.A., BOULTON JONES, J.M., SISSON, J.G.P. & EVANS, D.J. (1973) Mesangiocapillary nephritis, partial lipodystrophy and hypocomplementaemia. *Lancet*, **ii**, 535.
- PICKERING, R.J., MICHAEL, A.F., HERDMAN, R.C., GOOD, R.A. & GEWURZ, H. (1971) The complement system in chronic glomerulonephritis: three newly associated aberrations. *Journal of Pediatrics*, **78**, 30.
- VARGAS, R., THOMSON, K.J., WILSON, D., CAMERON, J.S., TURNER, D.R., GILL, D., CHANTLER, C. & OGG, C.S. (1976) Mesangiocapillary glomerulonephritis with dense 'deposits' in the basement membranes of the kidney. *Clinical Nephrology*, **5**, 73.
- WEST, C.D., NORTHWAY, J.D. & DAVIS, N.C. (1964) Serum levels of Beta 1c globulin, a complement component in the nephritides, lipid nephrosis and other conditions. *Journal of Clinical Investigations*, **43**, 1507.