Postgrad. med. J. (March 1969) **45**, 230–232.

Bleeding oesophageal varices

ROGER WILLIAMS
M.D., M.R.C.P.

IN BRINGING this Symposium to a close, I shall deal with one of the most dramatic and lethal complications of liver disease—rupture of an oesophageal varix. These patients die from loss of blood or liver failure, or more usually, a combination of both factors. The development of liver failure with increasing jaundice, ascites and hepatic coma is inevitable if bleeding is allowed to continue. The haemorrhage causes a decrease in hepatic blood flow with resulting hepatic anoxia. Another factor contributing to the hepatic encephalopathy is the absorbed load of nitrogenous breakdown products from the blood within the lumen of the gut. When confronted with such patients there are three aspects to be considered.

1. Confirmation of site of bleeding

Cirrhotic patients have an increased incidence of peptic ulcer and in various series published in America more than half of those admitted with bleeding have either an alcoholic gastritis or a chronic peptic ulcer. In this country alcoholism is a less common cause of cirrhosis and probably a greater proportion are bleeding from varices. Direct visualization of a bleeding point at oesophagoscopy is the only way of being certain, but this is unpleasant for the patient and bleeding may have stopped by the time of examination. We rely on a barium swallow and meal to demonstrate varices and to exclude a peptic ulcer and reserve oesophagoscopy and gastroscopy for patients in whom there is serious doubt as to the site of bleeding. The control of bleeding by a Sengstaken tube is also useful as a confirmatory test. The occurrence of bleeding in a young patient, or in one without signs of cirrhosis, should raise the suspicion of an extrahepatic portal hypertension due to thrombosis of splenic or portal veins. The chances of successfully controlling the acute bleed and the long-term survival are higher in this group, although shunt operations can rarely be performed.

2. Immediate measures

Adequate blood transfusion is essential to prevent further impairment of liver function. Fresh blood is preferable for it will temporarily remedy the deficiency of platelets and clotting factors so often present in cirrhosis. Vitamin K_1 (10 mg daily) should also be given. Neomycin (1 g 4-hourly) given orally or through a stomach tube will decrease bacterial breakdown of blood in the gut and the bowel should also be kept empty by enemata. Morphine and similar sedatives must not be given since they are liable to precipitate hepatic coma. If the patient is greatly distressed, phenobarbitone (60–200 mg intramuscularly) or chlorpromazine (50–100 mg intramuscularly) are probably the least harmful. Occasionally the patient may stop bleeding spontaneously or after blood transfusion but usually more active measures have to be employed.

Vasopressin (Pitressin)

Vasopressin lowers portal blood flow and pressure as a result of vasoconstriction of the splanchnic arterioles. Vasopressin is given as an intravenous infusion of 20 units in 100 ml of 5% dextrose over 20 min and the effect lasts up to 1 hr. Initially there is also systemic arteriolar constriction with transient pallor of the skin and rise in arterial blood pressure. Intestinal colic is another immediate effect which may be useful in emptying the bowel of blood. The dose can be repeated after 4 hr but its efficacy tends to decrease with successive doses. Its use is contraindicated in patients with cardiac ischaemia and another disadvantage is that the reduced hepatic blood flow may further impair the circulation of the cirrhotic nodules. The synthetic derivative phenylalanine^2-lysine^8-vasopressin (Octapressin) has less effect on the systemic circulation but its advantages over vasopressin have not been established in a controlled trial (Tsakiris, Haemmerli & Bülmann, 1964).

Balloon tamponade

The Sengstaken tube with its gastric and oesophageal balloons was introduced in 1950 and much has been written about its use. Traction is advised by some to keep the gastric balloon in position in the fundus of the stomach and this can be judged by screening the patient during inflation of the balloons. The tube is undoubtedly effective but is unpleasant for the patient and there is also a risk of pulmonary complications and oesophageal ulceration (Read *et al.*, 1960). Repeated pharyngeal suction to remove saliva and other secretions is required

Postgrad Med J: first published as 10.1136/pgmj.45.521.230 on 1 March 1969. Downloaded from http://pmj.bmj.com/ on August 10, 2022 by guest. Protected by copyright.

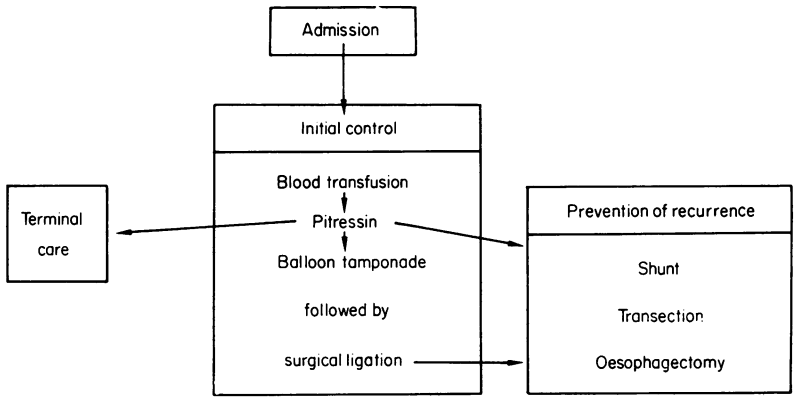

FIG. 1. Illustrating scheme of management (from Williams & Dawson, 1968).

and on no account should the balloons be left inflated for more than 24–36 hr. Some workers find that a single gastric balloon is sufficient and suggest that the pressure of the balloon against the diaphragmatic crura stops the blood flow from the gastric veins into the oesophageal varices (Linton & Ellis, 1956; Tanner, 1967).

Published results show that either of these techniques has stopped bleeding in 20–80% of patients but their effect is temporary. Pitressin is the simplest and least distressing to the patient, and our practice is to use it once unless there are specific contra-indications (Fig. 1). If bleeding is not stopped or if it recurs within a few hours then we use the Sengstaken tube. Some time in the next 24 hr, however, when the bleeding has been controlled and the general condition improved, the patient is taken to the threatre for surgical ligation of the varices. Experience has shown that most of these patients bleed again during the next days or weeks, and that with each re-bleed and subsequent resuscitation the general condition and liver function of the patient deteriorates and the chances of a successful outcome get less. The real problem arises in deciding whether to operate on a patient with signs of severe liver failure and in whom bleeding has been stopped by Pitressin or the Sengstaken tube. So often the bleeding is but one manifestation of terminal liver failure and not infrequently it has been precipitated by the final development of a hepatoma.

Surgical ligation of varices

The chest is opened through the bed of the eighth rib and the lower oesophagus mobilized. The varices may then be dealt with in either of two ways. In the Boerema–Crile operation (Britton & Crile, 1963; Hunt, 1965) the lower oesophageal lumen is entered via a longitudinal incision. The columns of varices are then under-run with a continuous catgut suture and the oesophagus closed in layers. In the Milnes–Walker operation (Walker, 1964) the muscle of the lower oesophagus is divided longitudinally down to the mucosa. The mucosal tube, together with the varices which lie in the submucosa is then dissected free and then divided transversely as low down as possible, and resutured with a continuous catgut suture. This suture, and the subsequent healing process in the mucosal layer occlude the varices. The two suture lines lie at right angles to one another so the closure is potentially safer than in the Boerema–Crile operation. Details of operations and the post-operative care have been given elsewhere (Williams & Dawson, 1968).

3. Subsequent therapy

Although a few patients do not re-bleed for a number of years after ligation of varices, the majority do and all should be assessed for definitive surgery. The operation which confers the best long-term protection against further haemorrhage is the portacaval shunt. Ideally, the patient should be less than 50 years old, only minimally jaundiced, have a serum albumin of greater than 3 g/100 ml and have shown none, or only minimal neuro-psychiatric disturbance during the haemorrhage. The portal vein must also have been shown to be patent by venography. Relatively few patients fulfil these criteria and many less favourable patients are operated on.

In patients who are unfit for shunt surgery some degree of protection against further operation may be conferred by a transection operation, either the Milnes–Walker type already described (if the initial procedure has been a simple ligation only) or the more extensive porta-azygos disconnection described by Tanner (1961). In this procedure, all the external

Postgrad Med J: first published as 10.1136/pgmj.45.521.230 on 1 March 1969. Downloaded from http://pmj.bmj.com/ on August 10, 2022 by guest. Protected by copyright.

vascular connections of the lower 5 cm of the oesophagus and the upper 5 cm of the stomach are divided. The upper stomach is then transected and re-anastomosed. The injection of sclerosant solutions into the varices (Macbeth, 1955) or into the submucosa around the varices has also been employed (Hunt, 1965) but there are no controlled trials of their use.

The approach that has been outlined means that the patient may have to undergo two major operations with a prolonged period of hospitalization. For this reason several groups in America have recommended than an emergency portacaval anastomosis should be done as the initial procedure after bleeding has been controlled (Orloff, 1968). Mortality figures are of the order of 40–50% which are remarkably good considering that these series are constituted of alcoholic patients with severe liver failure on admission. In this country, however, the procedure has been carried out only in patients in whom liver cell function is good. In such patients Shaldon Walker (1962) obtained an immediate operative mortality of 20% as compared with 5% for a shunt operation done as an elective procedure.

The overall results reported for bleeding varices are certainly not encouraging. Hislop and colleagues (1966) found that thirty-six of sixty-three patients admitted with their first bleed from varices died, and in Sherlock's series (1964) forty of 120 cirrhotic patients died within 1 year of their first haemorrhage. Nevertheless, the overall prognosis for selected groups of good risk patients treated by shunt operations is quite good.

Hunt (1965) in an analysis of 242 cases found a 5-year survival of 48% and a 10-year survival of 27%. However, Grace, Muench & Chalmers (1966) who analysed 154 papers in the world literature could find no evidence that the shunted patient survived longer than the good risk patient who had bled but had not had a shunt performed. The incidence of hepatic encephalopathy after a portacaval shunt was 22% (Table 1). This encephalopathy must to some extent reflect the progressive nature of the underlying liver disease but there seems little doubt that the incidence is higher after shunt operations. This is well shown by the results of a controlled study of prophylactic portacaval anastomosis (Table 2). However, in some of these patients the symptoms of encephalopathy may be relatively minor and easily controllable by neomycin and protein restriction. There is no evidence at present that a prophylactic portacaval anastomosis significantly prolongs life, but it is difficult to judge whether the interference to working capacity and quality of life enjoyed, which result from encephalopathy, is worse than that resulting from recurrent bleeding.

TABLE 1. The morbidity of shunt operations (from Grace *et al.*, 1966)

	Portacaval	Splenorenal
No. of patients	762	232
Recurrence of bleeding (%)	2·8	19
Incidence of encephalopathy (%)	22	13·4

TABLE 2. Results of prophylactic portacaval anastomosis (New Haven and Boston, from Grace *et al.*, 1966)

	Shunts	Controls
No. of patients	68	73
Occurrence of bleeding (%)	1·5	26
Occurrence of encephalopathy (%)	25	5·5

References

BRITTON, R.C. & CRILE, G. (1963) Late results of transoesophageal suture of bleeding oesophageal varices. *Surg. Gynaec. Obstet.* **117**, 10.

GRACE, N.D., MUENCH, H. & CHALMERS, T.C. (1966) The present status of shunts for portal hypertension in cirrhosis. *Gastroenterology*, **50**, 684.

HISLOP, I.G., WATERS, T.E., KELLOCK, T.D. & SWYNNERTON, B. (1966) The natural history of haemorrhage from oesophageal varices. *Lancet*, **i**, 945.

HUNT, A.H. (1965) An analysis of 584 cases of portal obstruction seen between 1947–1963, with particular reference to surgical treatment. *St Bart's Hosp. J.* Suppl. No. 11, **69**, 1.

LINTON, R.R. & ELLIS, D.S. (1956) Emergency and definitive treatment of bleeding oesophageal varices. *J. Amer. med. Ass.* **160**, 1017.

MACBETH, R. (1955) Treatment of oesophageal varices in portal hypertension by means of sclerosing solutions. *Brit. med. J.* **2**, 877.

ORLOFF, M.J. (1968) *The Therapy of Portal Hypertension* (Ed. by N. G. Markoff). Verlag, Stuttgart.

READ, A.E., DAWSON, A.M., KERR, D.N.S., TURNER, M.D. & SHERLOCK, S. (1960) Bleeding oesophageal varices treated by oesophageal compression. *Brit. med. J.* **1**, 227.

SHALDON, C. & WALKER, R.M. (1962) Emergency portacaval anastomosis. *Lancet*, **ii**, 1003.

SHERLOCK, S. (1964) Haematemesis in portal hypertension. *Brit. J. Surg.* **51**, 746.

TANNER, N.C. (1961) The late results of porto-azygos disconnexion in the treatment of bleeding from oesophageal varices. *Ann. Roy. Coll. Surg. Engl.* **28**, 153.

TANNER, N.C. (1967) *The Liver* (Ed. by A. E. Read). Butterworth, London.

TSAKIRIS, A., HAEMMERLI, U.P. & BULMANN, A. (1964) Reduction of portal venous pressure in cirrhotic patients with bleeding from oesophageal varices by administration of a vasopressive derivative, phenylalanine^2-lysine^8-vasopressin. *Amer. J. Med.* **36**, 852.

WALKER, R.M. (1964) Oesophageal transection for bleeding varices. *Surg. Gynaec. Obstet.* **118**, 323.

WILLIAMS, R. & DAWSON, J.L. (1968) The management of bleeding oesophageal varices. *Brit. med. J.* **1**, 35.

Postgrad Med J: first published as 10.1136/pgmj.45.521.230 on 1 March 1969. Downloaded from http://pmj.bmj.com/ on August 10, 2022 by guest. Protected by copyright.