

Injection ulcers do not occur if a careful technique has been employed. Should one happen, however, the leg should be firmly supported by means of an elastoplast bandage, which should not be removed for a month. The ulcer is thus out of sight of the patient and operator, and usually heals without much trouble.

Leak ulcer does not occur if the needle is not removed too hurriedly after an injection, and if the limb is not allowed to be dependent after the sclerosant has been introduced. Oedema resulting from injection means interference with the deep vein system, and the only thing to do is to apply a firm supportive bandage.

Recanalisation of veins, as already explained, is less likely to occur following a proper technique on correctly selected cases. The term is often used to include, not only cases in which a new channel has formed in the vein, but also those cases which "recur" from the dilatation of fresh veins around the sclerosed vessel, or from the enlargement of small veins considered too small for injection at the original time of treatment.

When performing the twin injection, introduced nearly twenty years ago by Rodney Maingot, use three syringes. Inject the lithocaine first, flush the needle through with sterile water, and finally use the third syringe for the quinine injection. One puncture spot, speed of injection, and the recumbent position of the patient are important factors in the success of this valuable manœuvre which is reserved for resistant large veins.

The hard "Roller" veins which occur around the ankle joint need careful fixation before injection. They also require a relatively larger dose. "Hair" veins, or as they are sometimes called "Spider Bursts," should be attacked via the "Feeder" vein, which is usually present. Very small veins may be entered more easily by using a dental syringe and needle. A solution of froth made by shaking some mono-ethanolamine oleate in the syringe is a useful method of dealing with this type of vein, this manœuvre allows the operator to see the small bubbles coursing along the interior of the vein. Minim doses of mono-ethanolamine oleate may sometimes be injected perivenously in cases, with advantage such.

The injection of varices in association with varicose ulceration must be done with especial care. No injection should be given until gross sepsis associated with the ulcer has been cleaned up by means of supportive and other measures. The injection should be given as far away from the ulcer as is possible, and the limb enclosed in a firm elastoplast bandage as soon as the treatment has been given. Never inject the varices of the vulva, or those of a varicocele. If in doubt where the syringe contents are going to, stop injecting,

and injection ulcers will be few and far between. All this advice appears too simple to warrant mention, but attendance in a vein clinic will soon show the reader that these elementary errors are frequent. Inject the right solution into the right type of case, and adopt the right technique, and recurrences and painful thrombi will become less common . . . and a valuable method of therapy will not receive unfair criticism.

REFERENCES

- BRICE, F. J. (1941), "Reactions after Ethanolamine oleate Injections" (letter), *Brit. Med. J.*, **1**, 797.
 COGSWELL and THOMAS (1940), *Southwest M.*, **24**, 408.
 DODD, H. (1940), "Treatment of Varicose Veins" (letter), *Brit. Med. J.*, **1**, 869.
 FOOTE, R. K. (1944), "Severe reaction to Mono-ethanolamine oleate" (letter), *Lancet*, September 16.
 GOLDEN and HEYERDALE, W. (1940), "Sensitivity to Sodium Monohate and Monolate," *Proc. Mayo Clinic*, **15**, 28.
 MAINGOT, R. H. (1932), "Injection Treatment of Varicose Veins, Haemorrhoids and Other Conditions," London: H. K. Lewis & Co.
 SHELLEY, H. J. (1939), *J. Amer. Med. Assn.*, **112**, 1792.

DISEASES OF THE SPINE AND SACRO-ILIAC JOINTS (Part II)

By G. O. TIPPETT, F.R.C.S.

(Hon. Asst. Orth. Surg. to Queen's Hosp. for Children and Croydon General Hosp., Acting i/c Physiotherapy Dept., University College Hospital.)

Diagnosis

In order to make a correct diagnosis in the case of a patient complaining of back-ache it is necessary not only to know the anatomical structures of the area concerned, but also to know what pathological conditions may be found as the result of disease or faulty body mechanics of these parts. Thus we may fit into the jig-saw the patient's symptoms and patient's physical signs on examination.

Diseases of the Spine and Sacro-Iliac Joints to be remembered by the Examiner

Inflammatory Disease.—Lumbago and Fibrositis.

Traumatic.—Sprains, fractures of vertebrae, adhesions and subluxations of the sacro-iliac joints.

Mechanical or postural upsets.—Excessive lordosis or kyphosis caused by faulty posture or other disease.

Diffuse Spinal Disease.—osteoarthritis, ankylosing spondylitis, and Tuberculosis.

Oddments.—Referred pain from intra-abdominal or peripheral nervous lesions, e.g. adherent Duodenal ulcer, Herpes, etc.

Preparatory to Examination of Patient

1. Ascertain from the patient where is the backache or pain complained of.

If in the *lumbar region* of the spine and the pain is localised, the possibility of fibrositis, tuberculosis, or fracture must be considered. If the pain is diffuse, lumbago or postural causations must be considered.

If in the *dorsal region*, then fibrositis, adolescent rigid kyphosis, or tuberculosis are possibilities.

If pain is complained of in the *sacro-iliac region*, the possibility of sacro-iliac strain, subluxation or arthritis should be considered.

2. Ascertain how long the patient has suffered from back-ache.

(a) Sudden onset suggests an acute inflammatory lesion such as lumbago.

(b) An insidious onset suggests fibrositis, osteoarthritis, postural strain, or tuberculosis.

(c) If there has been pain for some time before resorting to doctor, the probability is that it is due to a long-standing postural strain, though sometimes a tuberculous spine may give rise to pain of an intermittent character, and only when it becomes continuous does the patient present himself for medical examination.

Predisposing causes.

(a) *Injury*.—The patient usually can tell the examiner whether he considers that his backache dates from the time of some definite injury, in which case the possibility of a fracture, a sprain, or traumatic adhesions should be considered.

(b) *Occupation*.—Standing and sitting for long periods both tend to fatigue the muscles responsible for postural tone, with the result that extra strain is thrown on the ligaments, thereby causing diffuse pain.

(c) *Previous attacks*.—If the patient tells the examiner that he has had such attacks of pain on and off for some years, the possibility is that one is dealing with a patchy fibrositis which has been stirred up by local trauma or climatic conditions.

(d) *Intercurrent disease*.—If a patient complaining of backache also informs the examiner that he has had pain in the other limbs, or swelling of joints, the strong possibility is that his backache is also due to one of the rheumatic or arthritic diseases.

Examination of Patient

The patient should be completely stripped, and the examiner should see the patient walk up and

down his consulting room. The patient should then be stationary and face away from the examiner so that a general view of the spine and its musculature can be undertaken. The examiner should note whether the spinal column is erect or whether there is any deviation from the perpendicular giving rise to scoliosis, that is a lateral deviation, or an excess of the normal anterior or posterior curvature, namely, an excess of kyphosis or lordosis. It should be remembered that there is normally some kyphosis in the dorsal region and some lordosis in the neck and lumbar regions, and that there is more lumbar lordosis in the female than in the male. The examiner should then have the patient standing immediately in front of him, and he should examine the spinal column closely, paying particular attention to the area complained of.

Local deformities of spine, such as a prominence of several spinal processes, that is the local kyphus—especially in the dorsal region—suggests tubercle or a fracture. A local kyphus in the lumbar region may be caused by a fracture or tubercle, but sometimes a prominence of spinal processes (suggesting a pathological kyphus) is seen in persons in middle life, but an X-ray photograph will reveal no gross disease in these vertebrae other than some absorption of the intervertebral discs, and possibly slight wedging of the bodies of the vertebrae concerned, signs of an early degenerative arthritic process due to “anno domini.”

An excessive lordosis is usually due to a chronic postural strain, though occasionally a more localised depression in the lower part of the lumbar lordotic curve should make the examiner remember the possibility of a spondylolithesis.

A scoliosis in a young person is probably due to postural imbalance, though occasionally the examiner will see a scoliosis due to partial paralysis and weakness in infantile paralysis. A scoliosis held by muscle spasm is also an accompaniment of sciatica.

Movements.

If there is general rigidity of the spine, the possibility of osteo-arthritic or ankylosing spondylitis arises. If there is local rigidity in the dorsal region adolescent rigid kyphosis must be remembered. Rigidity in the lumbar region accompanied by spasm suggests lumbago, fibrositis, or tuberculosis. Rigidity without spasm is found in osteo-arthritis.

Note.—On asking the patient to bend down, that is flex the spine, notice if the lateral deviation disappears or persists. In lumbago and sciatica the lateral deviation being due to spasm still persists even in flexion. Most early cases of postural scoliosis do not show any fixed deviation

on flexing the spine. If the patient cannot fully flex and put his hands at least as far as the knees the possibility of tight hamstrings must be considered, as this condition may give rise to an excessive lordosis which in turn gives rise to postural pain. Tight hamstrings are considered by many observers to be the causation of the dire disease of adolescent rigid kyphosis.

Palpation.

- (a) *Vertebral column.*—Tap any projecting spinous process. If pain is complained of, tubercle, fracture, or supra-spinous ligament strain must be considered.

If there is tenderness of the posterior blade of ilium on palpation, percussion, or jerking, the presence of a chronic sacro-iliac strain or an arthritis (due to osteo-arthritis, toxic arthritis, or tuberculosis) must be considered.

- (b) *Soft parts.*—Tenderness of the soft parts of the back, either local or diffuse, is found in lumbago, fibrositis, or post-traumatic and inflammatory adhesions.

SPECIAL TESTS.

- (a) With the patient lying on the examination couch, the examiner should fully flex both hips well on to the abdomen. If pain results, a lumbo-sacral strain or low lumbar arthritis may be present.
- (b) With the patient lying supine on the couch, the examiner should raise each leg straight in the air, pushing over to the abdomen as far as possible. This manœuvre not only stretches the sciatic nerve, but also, through the attachment of the hamstring muscles, throws a strain of a rotary nature on to the iliac bone which is transmitted through the sacro-iliac joint. A comparison should be made between the limits of movement of either side. If one movement produces pain at an earlier stage of the movement than the other, the possibility of a sciatica or sacro-iliac strain must be considered and differentiated.
- (c) With the patient lying on one side, the examiner should forcibly jerk one blade of the ilium forwards and inwards, thus putting the sacro-iliac joint on to sudden tension. Pain from this manœuvre is present in sacro-iliac strain or arthritis. The mere clicking that is heard on carrying out this test is of no special significance other than showing slight laxity of the great sacro-sciatic ligament.

- (d) *Head suspension.* The examiner should stand in front of the patient, and placing his hands under the patient's chin he should endeavour to lift the patient off the floor. If possible, an assistant should note whether any curvature of the spine straightens out. As a rough rule it may be stated that where a curvature straightens out on suspension, it is not likely that backache is due to this degree of deviation, and search should be made for some other spinal condition.

- (e) The patient should now sit on a small stool with his hands across his chest, whilst the examiner, standing behind, should grasp the patient by his shoulders and twist him from side to side. Pain on rotating the lumbar spine shows up the presence of adhesions of arthritis.

X-ray Examination

In a case of backache an X-ray examination of the spine should be made, preferably involving all the spine, but in any case the area complained of. Not only should one look for disease, but one should also notice the deviations of the curvature from the normal, that is scoliosis and kyphosis,

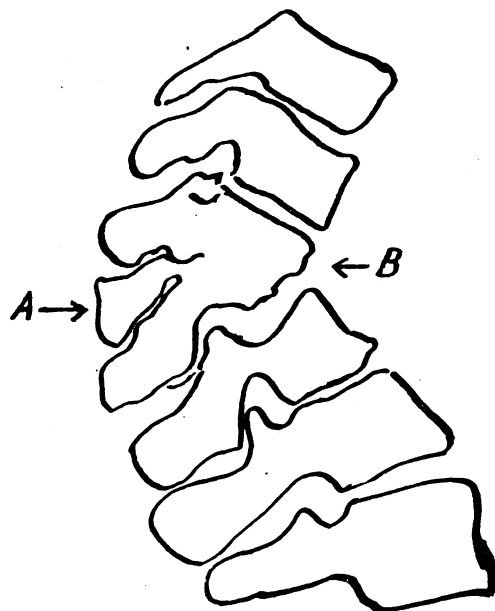


FIG. 1. *Spinal Tuberculosis.*

A lateral view of a tubercular spine.

A. Local Kyphosis.

B. Two vertebral bodies have now been attacked, eroded and now have collapsed.

both of which, as before noted, may be due to either disease or to faulty posture. Sometimes it is difficult to draw the line as to what is an abnormality and what is a normal curvature. The individual vertebrae should be examined for signs of collapse (as would be found in fractures or in tuberculosis), or osteophytic formations due to arthritis. Special attention should be paid to the contour and regularity of the surfaces of the articular facets. Very often root pain may be caused by a localised arthritis of one articular facet.

In the lateral X-ray special attention should be paid to any signs of a wedging which is often found in the lumbar spine from pure "anno domini." Other causes of wedging are, of course, fractures,

tuberculosis and osteo-arthritis. Wedging in the dorsal spine is caused (1) through adolescent rigid kyphosis, (2) fractures which are usually accompanied by some dislocation, and local spinal cord damage, and (3) tuberculosis which is usually accompanied by signs of an abscess shadow.

The relative position and the angle of the sacrum as compared to the 5th lumbar should be noted for signs of an early slipping of the 5th lumbar on the sacrum, that is, a pre-spondylo-lithitic stage. Fuzziness of one or more vertebrae should make the examiner consider the possibility of carcinoma secondaries. Other rare curiosities sometimes are seen giving rise to collapse or fuzziness, such as vascular tumours.

Other Diseases which May Give Rise to the Symptoms of Back-ache

High backache may sometimes be caused by a duodenal or gastric ulcer adhering to the pancreas. Similarly, gall stones and chronic cholecystitis, especially if there are adhesions, will cause not only pain in the shoulder blade, but also diffuse back-ache.

Low back-ache may accompany many gynaecological conditions, such as retroversion and fibroids, and no clinical examination for backache can be said to be complete without a full vaginal and rectal examination. Other causes of low backache are visceroptosis and constipation. Infections of the lower renal tract, urethric stone, tuberculous ulceration of the bladder, and prostatitis may also give rise to low sacro-iliac distribution of pain. Therefore, in all cases of low backache the urine must be examined. Rectal examination may produce many surprises in the way of causation of back-ache. Piles, fissures, and a carcinoma of the rectum may give rise to low back-ache. Many patients who have sustained the trivial trauma of sitting hard on their tailpieces complain not only of tenderness of the coccyx and sacrum, but also of persistent pain, namely coccydynia.

Thus it will be seen that the causations of back-ache are manifold, ranging from physiological overstrain of an otherwise normal back to serious diseases, such as tuberculosis or carcinomatosis. Thus the examination of a patient complaining of back-ache may prove to be time-taking procedure, and in some cases the examiner is at a loss to account for the actual causation.

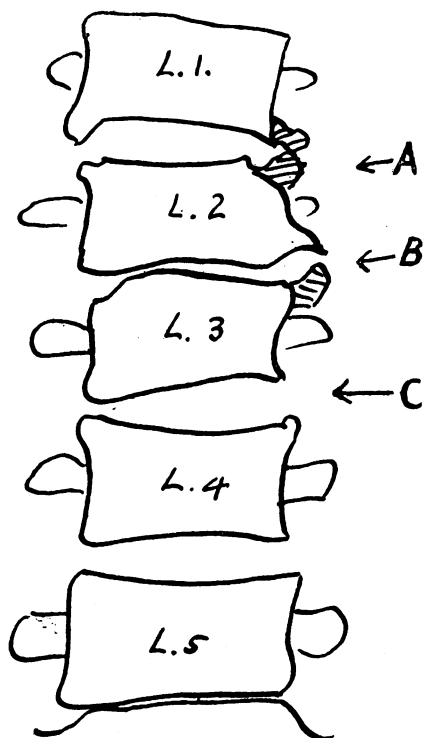


FIG. 3. *Osteo-arthritis of the Lumbar Vertebrae.*

An anterior-posterior view showing "Beaks" due to osteophytes, A & B.

c. Note the irregular disc space.

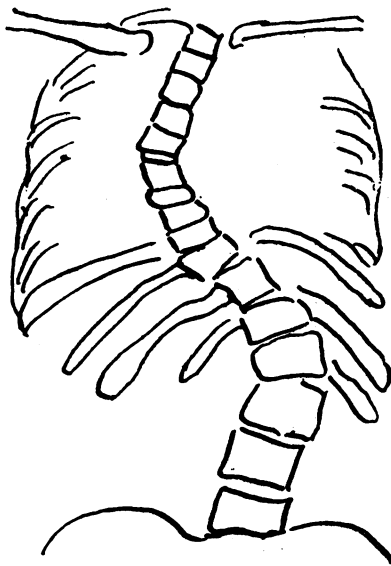


FIG. 2. *Postural Scoliosis.*

An anterior-posterior view of the multiple curves of a scoliosis.

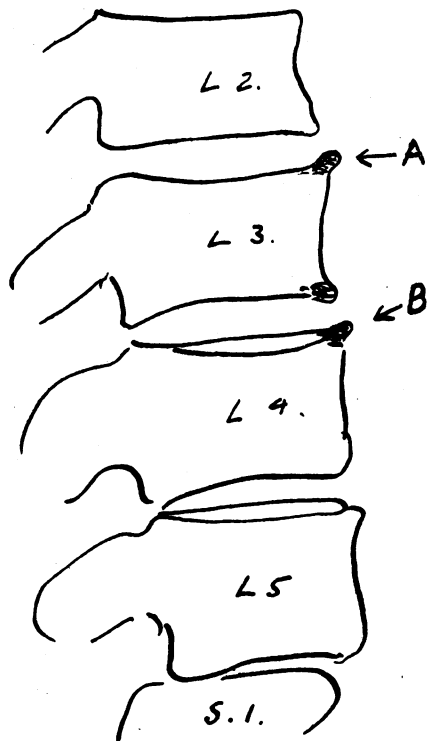


FIG. 3b. A lateral view showing little osteophytic formation as compared to that seen in an anterior-posterior view.

A. & B. "Small beaks" usually designated as lipping.

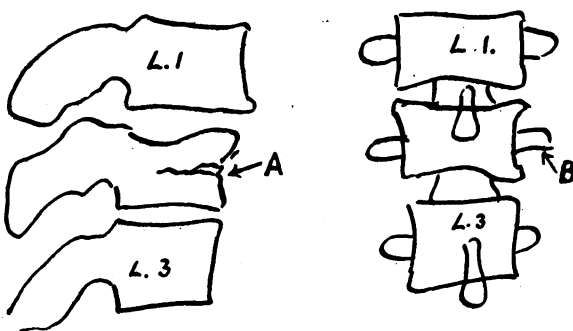


FIG. 5. *Compression Fracture of Lumbar Vertebra.*

This fracture might easily be missed if only an anterior-posterior view is taken.

- A. 1. The irregular upper surface.
- 2. The depression in the anterior border.
- B. Note that the body does not appear symmetrical as compared to those above and below.

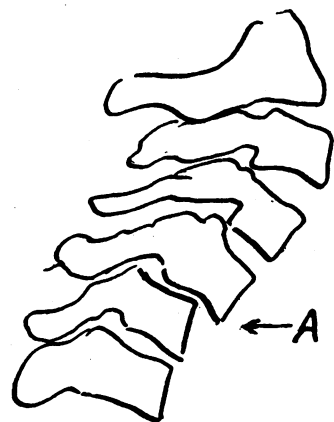


FIG. 4. *Dislocation of the Cervical Vertebrae.*

A lateral view showing a dislocation between the 4th and 5th cervical vertebrae.

A. Note the projecting anterior edge.