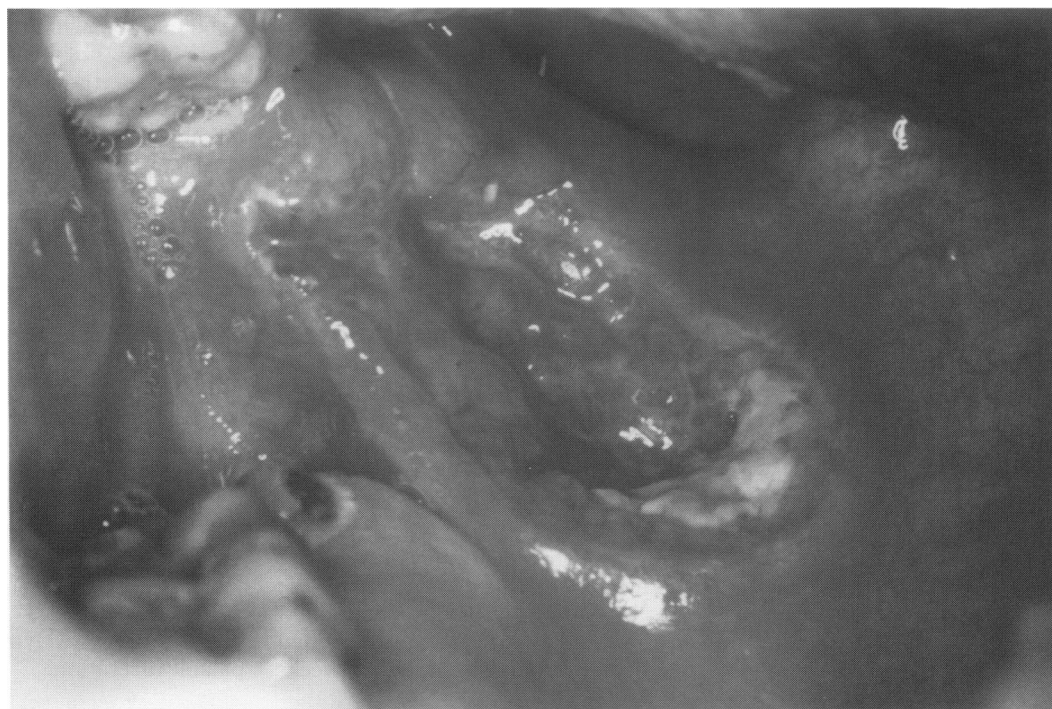

Self-assessment corner

Atypical palatal ulceration

JAG Buchanan, AS Hasan, L Churchill, F Fortune

A 41-year-old unmarried woman presented with a painful solitary ragged palatal ulcer of 3 cm diameter with a well-defined raised rolled margin and necrotic central base. The ulcer had been first noticed some six weeks previously as a persistent white plaque and was unresponsive to antibiotic therapy. The patient had smoked 15 cigarettes/day for the past 15 years and there was no history of intravenous drug abuse, unprotected sex or blood transfusion. General examination was unremarkable and there were no systemic symptoms.



**Department of
Immunology, Guy's
Hospital, Floor 28,
London SE1 9RT, UK**
JAG Buchanan
AS Hasan
L Churchill
F Fortune

The palatal ulcer extended from the left side of the hard and soft palate to the retromolar region. There was no limitation of movement of the soft palate, dysphagia, or dysphonia

- Question 1 What diagnostic test should be performed?
- Question 2 Suggest four possible causes.

Causes of persistent palatal ulceration

- oral malignancy: 90% squamous cell carcinoma
- Behcet's disease
- ulcerative colitis
- erosive lichen planus
- lupus erythematosus
- factitial injury
- infection – tuberculosis, syphilis

Answers

QUESTION 1

A persistent solitary oral ulcer in a middle-aged or elderly patient should prompt urgent investigation since a neoplastic lesion must be foremost on the list of the differential diagnoses. Where possible, specialist oral medicine opinion should be sought and immediate biopsy performed. A full haematological autoantibody and infective screen should be undertaken with radiographic and special imaging if there is a possibility of bony involvement or metastases.

QUESTION 2

A wide variety of different diseases may present with persistent atypical palatal ulceration (see box). Major aphthous ulceration is unlikely. Major aphthous ulceration characteristically has its peak age of onset between birth and 19 years of age, is recurrent, has lesions persisting for between 10 and 30 days, with between one and 10 ulcers of greater than 1 cm diameter occurring at any one time.¹ The situation may be complicated in HIV disease where atypical major (or herpetic) ulceration may appear *de novo*.² However, in this patient's case the solitary ulcer had a typically malignant indurated appearance with a raised, rolled margin, had been present for at least six weeks

and there was no preceding history of recurrent oral ulceration. Approximately 90% of all forms of oral malignancy are squamous cell carcinomas and these may arise from premalignant lesions such as leukoplakia, erythroplakia or speckled leukoplakia.³ They are usually found in the U-shaped region involving the borders of the tongue and the lingual alveolar mucosa. Squamous cell carcinoma metastases from tumours of the breast, kidney, lung, colon, prostate or thyroid may also rarely present in the oral region but tend to involve bone. Midline granuloma⁴ and necrotising sialometaplasia⁵ also present in this manner.

Discussion

Incisional biopsy revealed histological features of a high-grade non-Hodgkins B-cell lymphoma. Lymphomas presenting in oral soft tissues are uncommon and are frequently misdiagnosed until histological examination is carried out.⁶ They typically present as soft localised erythematous swellings which proceed to ulcerate and are often characterised by an absence of systemic symptoms. Isolated presentation within the oral cavity often foreshadows imminent progression to lymph nodes and other reticuloendothelial organs. Oral non-Hodgkins lymphomas are radioresponsive but multiple agent chemotherapy with intrathecal prophylaxis avoids the deleterious effects of radiotherapy on the oral tissues whilst effectively treating the primary lesion and any unrecognised occult metastatic deposits. An increased incidence of non-Hodgkins lymphomas has been found in patients with HIV disease, organ transplants, farmers exposed to phenoxyacetic herbicides and following therapeutic irradiation.⁷

Final diagnosis

Non-Hodgkin's lymphoma presenting as palatal ulceration.

1 Rodu B, Mattingly G. Oral mucosal ulcers: diagnosis and management. *J Am Dent Assoc* 1992; 123(10): 83–6.

2 MacPhail L, Greenspan D, Feigae D, *et al*. Recurrent aphthous ulcers in association with HIV infection. *Oral Surg Oral Med Oral Pathol* 1991; 71: 678–83.

3 Cawson RA, Binnie WH, Eveson JD. *Colour atlas of oral disease: clinical and pathological correlation*. 2nd edn. Wolfe, 1994.

4 Batsakis J, Luna M. Midfacial necrotizing lesions. *Semin Diagn Pathol* 1987; 4: 90–116.

5 Abrams AM, Melrose RH, Howell PV. Necrotizing sialometaplasia – a disease simulating malignancy. *Cancer* 1973; 32: 130–5.

6 Freeman C, Berg JW, Cutler SJ. Occurrence and prognosis of extranodal lymphomas. *Cancer* 1972; 29: 252.

7 Regezia JA, Sciubba J. Lymphoid lesions. In: *Oral pathology. Clinical pathologic correlations*, 2nd edn. WB Saunders, 1993, pp 303–21.



Atypical palatal ulceration.

J. A. Buchanan, A. S. Hasan, L. Churchill and F. Fortune

Postgrad Med J 1995 71: 55-56

doi: 10.1136/pgmj.71.831.55

Updated information and services can be found at:
<http://pmj.bmj.com/content/71/831/55.citation>

These include:

Email alerting service

Receive free email alerts when new articles cite this article. Sign up in the box at the top right corner of the online article.

Notes

To request permissions go to:
<http://group.bmj.com/group/rights-licensing/permissions>

To order reprints go to:
<http://journals.bmj.com/cgi/reprintform>

To subscribe to BMJ go to:
<http://group.bmj.com/subscribe/>