

Painless giant cell thyroiditis

Innocente Piazza and Alessandro Girardi

Department of Internal Medicine, Hospital of San Donà di Piave (Ve), Italy.

Summary: We describe an atypical case of subacute thyroiditis affecting a 50 year old patient with long lasting fever, weight loss, malaise and a high erythrocyte sedimentation rate. Cytological examination of the thyroid gland showed the classic granulomas with giant cells. However, the patient had neither painful enlargement of the gland nor thyrotoxicosis.

This case, as well as others previously described, probably represents a new subtype of subacute thyroiditis, painless giant cell thyroiditis. The presence of painless giant cell thyroiditis should be considered in any patient with undiagnosed pyrexia, weight loss and elevated ESR.

Introduction

Subacute thyroiditis, first described by de Quervain in 1904,¹ is an inflammatory disorder characterized by a tender thyroid swelling, spontaneous neck pain radiating to the throat and ears, fever, generalized malaise and elevated erythrocyte sedimentation rate (ESR).

A period of hyperthyroidism caused by discharge of preformed thyroid hormone from damaged cells may develop. In these cases the thyrotoxic condition spontaneously resolves in a few weeks and the patients become euthyroid again. Sometimes, it can be followed by transient, asymptomatic hypothyroidism. Histological examination of the gland shows infiltration of inflammatory cells and granulomas containing typical giant cells.

In recent years, cases of subacute thyroiditis have been reported which seem to define a new subtype, so-called 'painless giant cell thyroiditis' a silent and often euthyroid thyroiditis.^{2,3,4} We report a similar case confirmed by clinical course and fine needle biopsy of the gland.

Case report

A 50 year old man presented with a 3-week history of evening fever, headache, constipation, abdominal pain and an 8 kg weight loss. There was no history of radiation therapy or excess of iodine intake, and family history revealed no thyroid disease.

On admission physical examination was essentially normal apart from a temperature of 37.8°C.

Laboratory tests revealed a markedly elevated ESR (130 mm/h), C-reactive protein, alpha-2 globulin, alkaline phosphatase of 210 IU/l (normal 30 to 110 IU/l), serum alanine aminotransferase (ALT) of 84 IU/l (normal 0–40 IU/l). Serum thyroxine and thyroid stimulating hormone (TSH) were normal. Routine evaluation for infectious diseases showed no abnormalities. Because of the symptoms suggesting a systemic or malignant disease the patient underwent abdominal sonography, chest and bone X-ray, upper and lower gastrointestinal tract series, prostatic fine needle aspiration biopsy, bone marrow aspiration and abdominal computed tomography.

Axillary lymphadenopathy appeared 20 days later. Subsequently, a cytological examination was performed which showed reactive lymphadenitis with lymphoproliferation and the presence of several immunoblasts.

In the following days there was a spontaneous improvement of all symptoms: fever disappeared, his weight increased, the lymph node and the blood test results normalized. After a month of hospitalization he was discharged with the diagnosis of 'pyrexia of unknown origin, with spontaneous recovery'.

Two weeks after discharge, the patient had completely recovered but physical examination revealed a painless, non-tender thyroid enlargement. A fine-needle aspiration biopsy of the gland showed typical changes of granulomatous subacute thyroiditis with giant cells (De Quervain thyroiditis, Figure 1). Serum thyroxine and TSH were still normal. Antithyroid antibodies were not found.

More than 15 months later the patient, who had never received treatment, remained asymptomatic with normal thyroid function. The thyroid gland returned spontaneously to normal size.

Correspondence: I. Piazza, M.D., Via Monte Piana 9, 30027 San Donà di Piave (Venice), Italy

Accepted: 12 January 1989

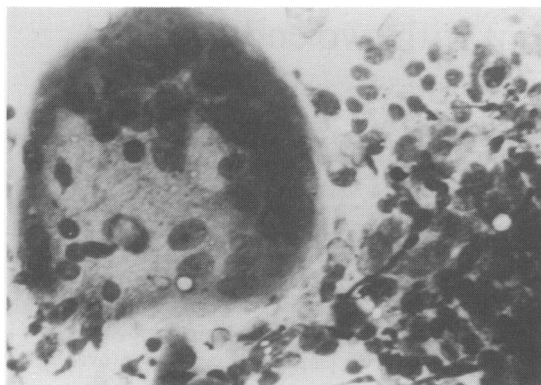


Figure 1 Fine needle aspiration of the thyroid gland: the collected material is very cellular: a giant multinucleated cell of histiocytic type surrounded by hyperplastic, enlarged follicular cells, intermingled with neutrophils. (M.G.G., original magnification $\times 400$).

Discussion

Subacute thyroiditis (De Quervain thyroiditis) is a quite common thyroid disorder, accounting for from 5 to 6% of all thyroid diseases.⁵ The clinical picture includes pronounced asthenia, malaise and symptoms referable to stretching of the thyroid capsule, pain over the gland or referred to the lower jaws, ear or occiput.

Though local or referred pain is universally accepted as the 'hallmark' of subacute thyroiditis,⁶ Stonebridge and Rotemberg^{2,3} have recently described patients who presented all the classical features of the disease (fever, weight loss, general malaise, thyroid

enlargement and typical granulomas with giant cells) except pain. Therefore, an atypical form of subacute thyroiditis seems to exist: painless giant cell thyroiditis.

Agreeing with these authors we believe that painless giant cell thyroiditis is characterized by the following features: (1) the illness often begins as a systemic disorder without symptoms suggesting involvement of thyroid, so that patients may undergo many unnecessary examinations. In our case, thyroid enlargement appeared only after spontaneous recovery of the systemic illness. (2) Patients are usually euthyroid,³ although a typical case with thyrotoxicosis has been described.⁴ (3) Anti-thyroid antibodies are transiently found only in a low percentage of patients, suggesting that antibody production is secondary to the inflammation rather than its cause.³ (4) Our patient, as well as another,² presented evidence of liver involvement and an inflammatory lymphadenopathy suggesting that a subclinical hepatitis and a transient lymphadenitis can be caused by the same presumed virus responsible for painless giant cell thyroiditis. We excluded the possibility of infectious mononucleosis associated with subacute thyroiditis and altered liver function.⁷

In conclusion, we suggest that painless giant cell thyroiditis is an atypical form of subacute thyroiditis. It should be suspected in any patient with pyrexia of unknown origin, weight loss and raised ESR.

Acknowledgements

We are particularly grateful to Dr Professor Paolo Boccato, Chief of Servizio di Citodiagnostica 2', Ospedale Civile, Padua (Italy), for his advice and for providing the photograph.

References

1. De Quervain, F. Die akute, nich eiterige thyreoiditis und die beteiligung der schilddruse an akuten intoxicationen und infektionen ueberhaupt. *Mitt Grenzgeb Med Chir Suppl* 1904, 2: 1.
2. Stonebridge, P.A. Occult subacute thyroiditis with unusual features. *Lancet* 1985, **ii**: 727.
3. Rotemberg, Z., Weinberger, I., Fuchs, J., Maller, S. & Agmon, J. Euthyroid atypical subacute thyroiditis simulating systemic or malignant disease. *Arch Int Med* 1986, **146**: 105-107.
4. Sanders, L.R., Moreno, A.J., Pittman, D.L., Jones, J.D., Spicer, M.J. & Tracy, K.P. Painless giant cell thyroiditis diagnosed by fine needle aspiration and associated with intense thyroidal uptake of gallium. *Am J Med* 1986, **80**: 971-975.
5. Woolf, P.D. Thyroiditis. *Med Clin North Am* 1985, **69**: 1035-1048.
6. Hamburger, J.I. The various presentations of thyroiditis. *Ann Intern Med* 1986, **104**: 219-224.
7. Fennel, J.S. Alkaline phosphatase and thyroiditis. *Ann Intern Med* 1979, **90**: 440.



Painless giant cell thyroiditis.

I. Piazza and A. Girardi

Postgrad Med J 1989 65: 580-581
doi: 10.1136/pgmj.65.766.580

Updated information and services can be found at:
<http://pmj.bmj.com/content/65/766/580>

Email alerting service

These include:

Receive free email alerts when new articles cite this article. Sign up in the box at the top right corner of the online article.

Notes

To request permissions go to:
<http://group.bmj.com/group/rights-licensing/permissions>

To order reprints go to:
<http://journals.bmj.com/cgi/reprintform>

To subscribe to BMJ go to:
<http://group.bmj.com/subscribe/>